

## An Audacious Voyage during COVID-19 Pandemic in Management of Patients with Aneurysmal Subarachnoid Hemorrhage at Tertiary Neurological Center in Nepal

Pravesh Rajbhandari<sup>1</sup>, Jayant Kumar Yadav<sup>1</sup>, Shilpa Giri<sup>1</sup>, Bishal Shrestha<sup>1</sup>, Jessica Kayastha<sup>1</sup>, Janam Shrestha<sup>1</sup>, Gopi Nepal<sup>1</sup>, Pritam Gurung<sup>1</sup>, Reema Rajbhandari<sup>2</sup>, Jitesh Shrestha<sup>3</sup>, Anusha Palikhe<sup>3</sup>, Shambhu Bahadur Karki<sup>3</sup>, Samir Acharya<sup>1</sup>, Resha Shrestha<sup>1</sup>, Sudan Dhakal<sup>1</sup>, Sharad Hari Gajuryal<sup>1</sup>, Pranaya Shrestha<sup>1</sup>, Basant Pant<sup>1</sup>

<sup>1</sup> Department of Neurosurgery, Annapurna Neurological Institute and Allied Sciences, Maitighar, Kathmandu, Nepal

<sup>2</sup> Department of Neurology, Maharjginj Medical Campus, Tribhuvan University Teaching Hospital, Kathmandu, Nepal

<sup>3</sup> Department of Anesthesia, Annapurna Neurological Institute and Allied Sciences, Maitighar, Kathmandu, Nepal

### CORRESPONDENCE

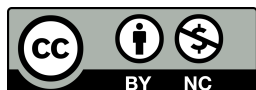Dr. Pravesh Rajbhandari  
Neurosurgery, Annapurna Neurological  
Institute and Allied Sciences, Maitighar,  
Kathmandu, Nepal  
Email: drpraveshrajbhandari@gmail.com

### ARTICLE INFO

Article History  
Submitted: 10 November, 2021  
Accepted: 12 December, 2021  
Published: 8 February, 2022

Source of support: None  
Conflict of Interest: None

**Copyright :** ©The Author(S) 2022  
This is an open access article under  
the Creative Common Attribution  
license CC BY-NC 4.0



### ABSTRACT

**Introduction:** Aneurysmal Subarachnoid Hemorrhage (SAH) is a neurosurgical emergency for which testing for COVID PCR was not an option and was unlikely to change the management of the case. Hence, all surgeries were performed without COVID PCR and Rapid Diagnostic Test (RDT) at our center for the welfare of the patient despite risks involved for the surgeons and supporting staff.

**Methods:** Data were collected retrospectively of all cerebral aneurysm patients who received treatment at Annapurna Neurological Institute and Allied Sciences during the covid pandemic between February 2020 to May 2021. Their demographic profile, clinical and imaging characteristics, treatment decision, postoperative complication, postoperative functional status in terms of Modified Rankin Scale were taken into consideration and analyzed.

**Result:** 63 patients were enrolled in study with patient age ranging from 9 years to 81 years. Male to female ratio was 1:3. Amongst them, 28% had hypertension. 82% underwent microsurgical clipping while three patients underwent coiling. Basilar Top aneurysm, Para clinoid aneurysm, PICA aneurysm underwent simple coiling. Wrapping, bypass and trapping were performed in 1, 1, and 3 cases respectively. At the time of discharge, most of the patients (77%) achieved good functional recovery (mRS ≤ 2) while mortality was reported in 8% of patients. Based on our experience and limited dataset, posterior location of aneurysm, increasing Hunt-Hess Grade and modified fisher grade had poor prognosis, related with degree of cerebral vasospasm, and delayed cerebral ischemia.

**Conclusion:** Results from our study showed outcomes in surgical patients with aneurysmal SAH at par with international standards. COVID pandemic although posed initial difficulties, with proper guidelines and protocols in place, we were able to perform the emergency surgeries without compromising our standards.

**Key Words :** Aneurysm; Clipping; Coiling; Covid -19.

### INTRODUCTION

As the corona virus seem to evolve into a more menacing fate, many countries still act in accordance with the accustomed measures to curb the escalation of the virion. Regrettably, the inclination towards rationing of healthcare assets to quarter the care of critically ill patients contaminated with the contagion has led to an

unprecedented challenge for all specialties who remain committed to lay hold of authority in medical crisis.<sup>1</sup> Concerns have been raised in the field of cardiology and neurology where it is apprehended that patients with myocardial infarction or stroke might avoid hospital or emergency visit due to fear of acquiring of COVID-19.<sup>2</sup>

A study from tertiary neurosurgical center in UK reported reduction in neurosurgical emergency referrals by 33.6% and operations by 55.6% during the pandemic.<sup>3</sup> In a retrospective cross-sectional study conducted across 6 continents and 140 centers, a relative decrease in volume of SAH hospitalizations, aneurysmal SAH hospitalizations and ruptured aneurysm embolization was reported during the first wave of the pandemic and was consistent with decrease in other emergencies such as stroke and myocardial infarction.<sup>4</sup>

Located in the confines of the capital city of Nepal, Annapurna Neurological Institute and Allied Sciences (ANIAS) is a full-fledged tertiary referral neurological and neurosurgical center. In Nepal, the pandemic caught tertiary referral centers off guard who were unprepared to handle the situation of this proportion. While government based tertiary referral centers with neurosurgical facility were converted into dedicated COVID facility, ANIAS continued to provide care for elective as well acute neurosurgical emergencies. Contradictory to the antecedent protocol set by the government to run an RDT/PCR test for COVID-19, we ended up abandoning the directive as the time taken was lingering and that it would not substitute our neurosurgical endeavor. In this retrospective study, we aim to assess the outcomes in patients with cerebral aneurysm who received emergency treatment at our center during the pandemic.

## METHODOLOGY

This was a retrospective study conducted at Annapurna Neurological Institute & Allied Sciences where data were collected from the hospital's electronic health records from the period of February 15, 2020, to May 15, 2021. Aneurysmal SAH being a neurosurgical catastrophe, assessment for the COVID PCR status was felt non-statutory. Nonetheless, there is no trade-off to surgical intervention with regards to the infective circumstance. On that account, preference to the welfare of the patient was set forth despite the noxious risk of acquiring the infection. However, any signs and symptoms of contamination were evaluated post-surgery. Exposed staff were frequently tested for COVID and isolated if the results came out positive or if they had signs and symptoms consistent to the COVID. Consent prior to surgery and after surgery for not performing PCR was taken.

The study was approved by the Institutional Review Board of the institute. All patients with aneurysmal subarachnoid hemorrhage (SAH) were included in the study and patients with traumatic or non-aneurysmal SAH were excluded from the study.

Information of patient's socio demographic status, medical and surgical history, vitals, GCS on presentation, Hunt and Hess classification (HH), Computed Tomography (CT) findings, Fisher's Classification (FC), Computed Tomography Angiography (CTA), and blood parameters were extracted from medical health record for the purpose of the study. Data was entered in excel sheet. Postoperative assessment was done based on modified Rankin Scale score (mRS). Descriptive statistics was used for the purpose of this study. All the values were expressed in terms of means and percentages. All the statistical analyses were performed using SPSS 16 (IBM Corp. Released 2016, IBM SPSS Statistics, Version 16.0, Armonk, NY: IBM Corp.).

## RESULT

### Patients Characteristics

A total of 63 patients were enrolled in the study with patient age ranging from 9 years to 81 years, most common amongst age group 30-60 years. The mean age was 45. There was a female sex preponderance with male to female ratio 1:3. In their midst, 21 (28%) of them were a known case of hypertension whereas hypothyroidism was reported in 2 patients. Further Chronic Obstructive Pulmonary Disease, Rheumatic Heart Disease, stroke, and polycystic kidney disease was reported in one patient each.

A total of 19 patients (30.2%) presented to our ER within first 24 hours, 6 patients (12%) within 2 days, 24 patients (36%) between 3-7 days, 5 (8%) patients after a week, 7 (6.6%) patients after a month of ictus while 2 (2.6%) patients presented to us with the history of headache for 2.5 years. The median duration from ictus to presentation was 2 to 7 days. 82% underwent microsurgical clipping while three patients underwent coiling. Basilar Top aneurysm, Para clinoid aneurysm, PICA aneurysm underwent simple coiling. Wrapping, bypass and trapping were performed in 1,1, and 3 cases respectively. The median duration of coiling and clipping was within 3 days from the ictus.

### Clinical presentation

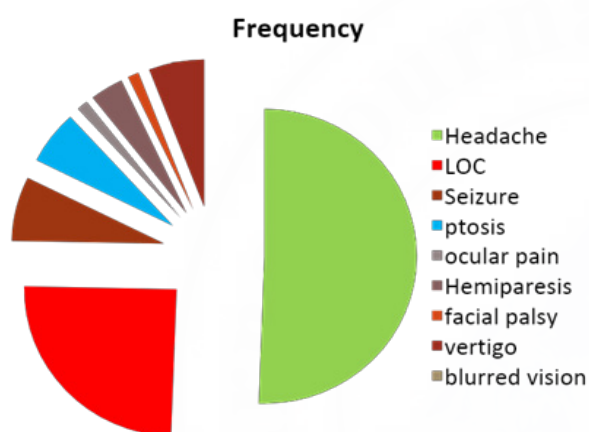
The typical mode of presentation was headache which was consistent in 62 patients. Next was vomiting which was encountered in 43 cases. 21 patients presented with brief loss of consciousness, 6 with abnormal body movements and 5 with ptosis. Ocular pain, hemiparesis, decreased level of consciousness, facial palsy, vertigo, and blurred vision were other surrogate symptoms. One patient reported burning sensation on unilateral head. 38 patients (60 %) were classified as Hunt and Hess grade 1 on initial presentation while 9, 11 and 5 patients were

classified as Hunt and Hess grade 2,3 and 4 respectively (Table 1) (Fig1).

**Table 1: Hunt and Hess classification of patients with aneurysmal SAH**

Hunt and Hess	N (%)
Grade 1	38 (60.3)
Grade 2	17 (27.0)
Grade 3	4 (6.3%)
Grade 4	4 (6.3%)
Grade 5	0

**Figure 1: Distribution of Patient's Symptoms**



Evaluation with CT angiography revealed ruptured aneurysms in 51 patients (81%) whereas 12 of them were classified as unruptured aneurysms. There were 4 cases of incidental discovery of aneurysm while a solitary case of thrombosed aneurysm was also encountered. Predicated by the Modified Fisher CT classification, majority of the patients were entailed in grade 1 whereas 16 patients enrolled into grade 3 or 4 (Table 2).

**Table 2: Distribution of Patients according to Modified CT fisher classification**

Modified Fisher Classification	Frequency	Percentage
0	15	23.8
1	22	34.9
2	10	15.9
3	10	15.9
4	6	9.5

**Characteristics of Aneurysms**

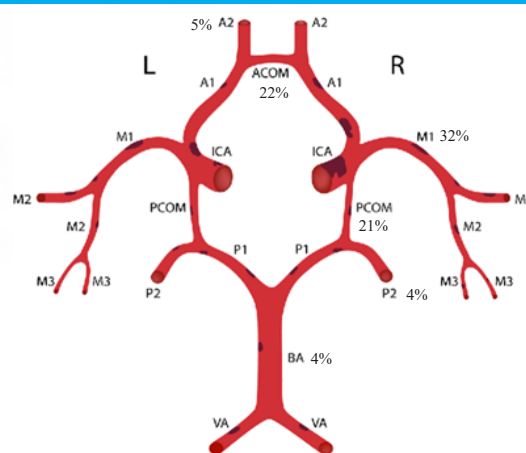
Based on the construct of aneurysm, 61 of them were saccular while 2 of them were mycotic. 59 cases had single aneurysm and 4 had multiple aneurysms. Up to 70% aneurysms were in anterior circulation with Middle cerebral artery involvement in 32% cases and

22% involving Anterior communicating artery. 21% cases had posterior communicating aneurysm. One case had aneurysm in both anterior and posterior circulation. The aneurysms were classified according to its vessel of origin as described in Table 3 & Figure 2.

**Table 3: location of aneurysm in patients included in the study**

Vessels	Frequency	Percentage
Anterior Communicating Aneurysm	17	22.6%
Anterior Cerebral Artery Aneurysm	5	6.66%
Middle Cerebral Artery Aneurysm	24	32.0%
Posterior Communicating aneurysm	16	21.3%
Internal Carotid Artery Cavernous Segment	2	2.60%
Internal Carotid Artery Para Clinoid Segment	3	4.00%
Internal Carotid Supra Clinoid Aneurysm	2	2.60%
Internal Carotid Artery Ophthalmic Segment	1	1.30%
Internal Carotid Bifurcation Aneurysm	1	1.30%
Basilar Top Aneurysm	3	4.00%
Posterior Cerebral Artery Aneurysm	3	4.00%
Posterior Inferior Cerebral Artery Aneurysm	1	1.30%
Vertebral Artery Aneurysm	3	4%

**Figure 2: Location of aneurysm in anterior and post circulation**



**Treatment Modalities**

Based on construct, dimension and whereabouts of the aneurysm, available paradigm of intervention, viz. clipping of aneurysm and endovascular coiling was proposed to the patient. Microsurgical aneurysm clipping was performed in 51 cases. 2 cases underwent wrapping, 5 underwent trapping, 3 underwent coiling, 1 bypass, and 1 underwent excision of mycotic aneurysm. Basilar Top aneurysm,

Para clinoid aneurysm, PICA aneurysm underwent simple coiling (Fig:3a,3b,3c,3d).

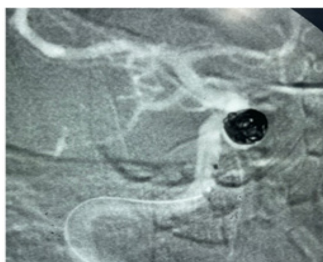


Fig 3a: Coiling of Para clinoid Aneurysm

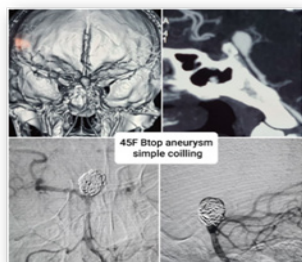


Fig 3b: Coiling of Basilar Top Aneurysm

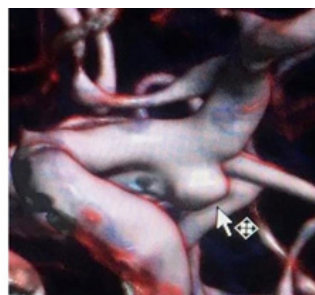


Fig 3c: CT Angiography PCOM Aneurysm

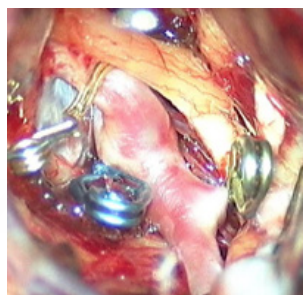


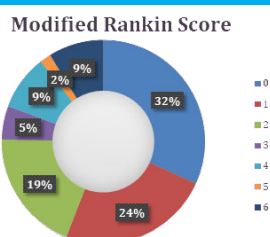
Fig 3d: Sequential Clipping of PCOM Aneurysm

### Postoperative complications and its management

Cerebral ischemia (11%) along with cerebral edema (9%) were most frequently reported complications among patients those underwent aneurysmal repair. Hydrocephalus, meningitis, and pneumonia was reported among the subset of patients. The recoveries of the patients were classified according to Modified Rankin Scale (mRS) at the time of discharge. At the time of discharge, most of the patients (77%) achieved good functional recovery (mRS ≤ 2) while death occurred in 5 patients. Moderate to severe disability as classified by mRS grade 3 and 4 was reported in 3 and 5 patients respectively (Fig 3b). Poor functional outcome (mRS grade 5 and 6) was reported among patients with posterior location of aneurysm, increasing Hunt-Hess grade and modified fisher grading. However, due to small subset of patients in individual subgroups, statistical analysis was deemed not feasible as it would lead to false conclusions.

At 3 months follow up, repeat CT scan showed 1 case of hydrocephalus and bleeding each, 2 cases had subdural hygroma and 3 cases had hydrocephalus ex vacuo.

Fig 7: Distribution according to Modified Rankin Scale



## DISCUSSION

An outstanding stride have been accomplished in the therapeutics of cerebral aneurysm since the first attempt, transpired by Dott in 1931 by wrapping MCA territory aneurysm with muscle.<sup>5</sup> However, it was Dandy, who performed the first clipping of an aneurysm in 1944 with modified Cushing-McKenzie silver clip and reported his case series in 1944 which surfaced to be a leading light in the chronicles of neurosurgery.<sup>6</sup> Aneurysm surgery was introduced in Nepal two decades ago while endovascular coiling was introduced recently in the year 2017. Annapurna Neurological Institute and Allied Sciences is a dedicated, full-fledged tertiary neurosurgical and neurological referral center in Nepal receiving patients from national and international territory.<sup>7,8,9</sup>

Since the mournful dawn of the COVID in our nation, the ministry of health designated hospitals and medical colleges were relocated as a center for referral of patients infected with the covid pneumonia. With the escalation of infected cases, a surge in riot was discerned among the health care facilities due to scarcity of the ventilator and other nursing appliances. As the pandemic emerged, we could not remain pristine, and the neurosurgical facilities had to endure hostility to keep the services ceaseless. In accordance with the government, every case had to go undergo a test to exclude infection with the corona virus. Unfortunately, the report took longer than expected. Because of a desperate death-or-glory situation in a patient with ruptured aneurysm, we had to cast aside scrupulous decision of the government authority of mandatory screening and concluded for an upfront surgery. Nonetheless, a set protocol was devised by our institution for the management of patients infected with the coronavirus. Due to an unbarred precautionary measure, clutching on with primeval cloth masks and gowns, an unendurable angst was felt among the medical staffs. Not a soul called it a day, when a casualty needing our services dispensed into our province. With what we had in our disposal, we kept on combating the fatal coronavirus without having a second thought of capitulating and abandoning the service to needful.<sup>10</sup>

Based on socio demographic survey, intracranial aneurysms are more prevalent in females peculiarly during the fifth and second decade of life. An analogous disclosure was encountered in our study group. Hypertension, a stereotypical risk factor for cerebral aneurysm was relayed in 28% patients in our study. A bare 40% of total patients presented to us within 2 days of ictus when it is contemplated to be the most advantageous time for surgery in achieving a complimentary aftermath. 14% of patients presented months to years late after initial event.

While the exact cause of this delay is unclassified, travel restriction pronounced by the jurisdiction during the pandemic to curb the spread of infection, in absence of structured ambulance service in Nepal may be held accountable. CT Angiography and Digital Subtracted Angiography were used as investigative tool to diagnose aneurysm.<sup>11,12</sup> Nevertheless absurdity and imprudent counsel from the referring physicians who may have falsely labeled grade I SAH as simple headache has also been recited in our overview.<sup>10</sup> Besides, as high as 81% of our patients as evidenced by CTA presented with ruptured aneurysms, because of lack of awareness among the community from the concerned authority to formulate a screening setup among the vulnerable.

The median duration to aneurysm repair in our study was 3 days from the ictus. Majority of cases were operated within the first few hours of presentation to the institute. The most dreaded risk in aneurysmal SAH is re bleeding within the first 24 hours and repair with either clipping or coiling is the salvage. Intervention should be done as early as possible preferably within the first 24 hours of ictus, but it is acceptable up to 72 hours in majority of cases.<sup>13</sup> Most of the patients presented had an acceptable grade of aneurysmal SAH (Hunt and Hess grade 1, 2, 3) accounting for 81.9%. The earlier is the treatment, the better is the sequelae. When a prompt treatment was commenced, a good functional recovery is achieved in approximately 70-90% patients which was contemplated in our study as well as 77% of patients had mRS score of 0-2 at discharge.<sup>14,15</sup> Grievously, 12.6% had a poor grade SAH (Hunt and Hess grade 4, 5) and had poor outcome among such patients. Aneurysmal SAH of these grades with a GCS < 4 is inevitable to succumb into the impoverished after-effects. In these circumstances, treatment should be individualized based on patient's age and comorbidities. Into the bargain, studies have shown that early surgery in poor grade SAH pose technical difficulties due to cerebral edema and clot surrounding aneurysm.<sup>16</sup> Being a minimally invasive approach, endovascular techniques in such setting may be more complementary and approving.<sup>17</sup> Three of our cases underwent endovascular coiling. However, it is more expensive than clipping and may not be an option for all in low-income settings. Mortality was reported in 8% cases in our study, comparable to international studies.

Based on our experience and limited dataset, posterior location of aneurysm, increasing Hunt-Hess Grade and modified fisher grade had poor prognosis, related with degree of cerebral vasospasm and delayed cerebral ischemia. However, due to small sample size, statistical analysis could not be performed to determine factors associated with poor functional outcomes among aneurysmal SAH patients

undergoing intervention as it would lead to spurious conclusions. This is one of the major limitations of our study. The synopsis of our study unveiled outcomes in surgical patients with aneurysmal SAH at par with international standards. Despite the cruel virion disseminating and fabricating an alarming situation among the society and health professionals, with a set guideline and protocol in act, we have been able to set forth the remedy for our patients without compromising our standards.

## CONCLUSION

The coronavirus pandemic caused great stir and anxiety among the public as well as treating physicians. The situation caught most of the centers in Nepal off guard prompting them to delay surgeries even in case of acute emergencies for the confirmation of covid RT-PCR results. As the outcome of cerebral aneurysm surgery is time bound, our center continued to serve the patients despite the risk involved for the treating hospital staffs for the benefit of the patients. Our study showed that good outcome was achievable even in the pandemic with strict precautionary guidelines in place.

## Acknowledgement

We would like to acknowledge all the frontliners who worked tirelessly without a second thought of themselves but to serve humanity and bow our heads to those who lost their life.

## REFERENCE

1. Zhu N, Zhang D, Wang W, Li X, Yang B, Song J, et al. A Novel Coronavirus from Patients with Pneumonia in China, 2019. *N Engl J Med.* 2020 Feb 20;382(8):727–33.
2. McFadden SM, Malik AA, Aguolu OG, Willebrand KS, Omer SB. Perceptions of the adult US population regarding the novel coronavirus outbreak. *PLoS One.* 2020 Apr 17;15(4):e0231808.
3. Ashkan K, Jung J, Velicu AM, Raslan A, Faruque M, Kulkarni P, et al. Neurosurgery and coronavirus: impact and challenges—lessons learnt from the first wave of a global pandemic. *Acta Neurochir (Wien).* 2021 Feb 21;163(2):317–29.
4. Nguyen TN, Haussen DC, Qureshi MM, Yamagami H, Fujinaka T, Mansour OY, et al. Decline in subarachnoid haemorrhage volumes associated with the first wave of the COVID-19 pandemic. *Stroke Vasc Neurol.* 2021 Dec;6(4):542–52.
5. Dott NM. INTRACRANIAL ANEURYSMS: CEREBRAL ARTERIO-RADIOGRAPHY: SURGICAL TREATMENT.

6. Dandy WE. INTRACRANIAL ANEURYSM OF THE INTERNAL CAROTID ARTERY CURED BY OPERATION. *Ann Surg.* 1938 May;107(5):654–9.
7. Rajbhandari P, Rajbhandari S, Shrestha P, Rajbhandari R, Sharma A, Upadhyaya S, et al. Initial experience with aneurysm coiling in Nepal. Vol. 15, Original Article *Nepal Journal of Neurosciences.* 2018.
8. Rajbhandari P, Rajbhandari S, Neupane A, Gurung P. Mechanical Thrombectomy for Acute Ischemic Stroke in Nepal. *Annapurna J Heal Sci.* 2021 Feb 10;1(1):35–7.
9. Rajbhandari P, Rajbhandari S, Neupane A, Martin T, Pant B. Carotid stenting in Nepal: Our experience with two cases of carotid stenosis. *Nepal J Neurosci.* 2021 Sep 1;18(3):44–8.
10. P. Devkota KRAU. Result of surgery for ruptured intracranial aneurysms in Nepal. *Br J Neurosurg.* 2001 Jan 6;15(1):13–6.
11. Rajbhandari P, Gurung P, Rajbhandari S, Shrestha D, Acharya S, Shrestha R, et al. Digital Subtraction Angiography a Door Opener for Neurosurgical Residents who want to Perform Neurointerventional Procedures. :3–7.
12. Parajuli S, Rajbhandari P, Acharya S, Pant B. Transient Cortical Blindness after Digital Subtraction Angiography of Cerebral Vessels. *Nepal J Neurosci.* 2017 Jun 1;14(2):36–8.
13. Connolly ES, Rabinstein AA, Carhuapoma JR, Derdeyn CP, Dion J, Higashida RT, et al. Guidelines for the Management of Aneurysmal Subarachnoid Hemorrhage. *Stroke.* 2012 Jun;43(6):1711–37.
14. Le Roux PD, Elliott JP, Downey L, Newell DW, Grady MS, Mayberg MR, et al. Improved outcome after rupture of anterior circulation aneurysms: a retrospective 10-year review of 224 good-grade patients. *J Neurosurg.* 1995 Sep;83(3):394–402.
15. van den Berg R, Foumani M, Schröder RD, Peerdeman SM, Horn J, Bipat S, et al. Predictors of outcome in World Federation of Neurologic Surgeons grade V aneurysmal subarachnoid hemorrhage patients\*. *Crit Care Med.* 2011 Dec;39(12):2722–7.
16. Koffijberg H, Buskens E, Rinkel GJE. Aneurysm occlusion in elderly patients with aneurysmal subarachnoid haemorrhage: a cost-utility analysis. *J Neurol Neurosurg Psychiatry.* 2011 Jul 1;82(7):718–27.
17. Gonzalez NR, Dusick JR, Duckwiler G, Tateshima S, Jahan R, Martin NA, et al. Endovascular Coiling of Intracranial Aneurysms in Elderly Patients. *Neurosurgery.* 2010 Apr 1;66(4):714– 21.