

**Case Study**

## ADULT ONSET STILL'S DISEASE PRESENTING WITH TUBERCULOUS BRONCHOPNEUMONIA: A CASE STUDY

Manmathan R<sup>1</sup>, Rathnapala A<sup>1</sup>, Siribaddana A<sup>1</sup>,

<sup>1</sup> Department of Respiratory Medicine, National Hospital Kandy, Sri Lanka

### ABSTRACT

**Introduction:** The occurrence of Post primary Tuberculosis [TB] can be due to reactivation of previous infection or reinfection. Reactivation of TB could occur due to many conditions including immunosuppressive drug therapy and immunosuppressive diseases. In countries where latent TB is common a good vigilance is needed for early detection of TB when such conditions are managed.

Adult onset Still's disease (AOSD) is a rare systemic disorder of unknown etiology where fever, rash, lymphadenopathy and multi organ involvement occur. ASOD is a challenging condition to diagnose as there are no pathognomonic physical signs or markers. Early diagnosis and initiation of treatment is important as diagnostic delays could lead to serious consequences <sup>(1)</sup>.

Occurrence of tuberculosis in a patient with AOSD has not been documented in literature to-date. Here we describe a 46-year-old male who presented with low grade fever and arthralgia for more than one month with organomegaly and pericardial effusion managed as AOSD, later developed Tuberculous bronchopneumonia.

**Keywords:** Tuberculosis, pericardial effusion, adult onset of still disease

### INTRODUCTION

Tuberculosis (TB) contributes to high mortality and morbidity world-wide. Around one third of the world population carry the infection. Latent TB infection may reactivate causing active disease. <sup>(2)</sup> Diagnostic delays play a major role in poor outcome.

Bacteriological confirmation of TB requires sputum examination for AFB or Catridge Based Nucleic Acid Amplification Test (CBNAAT) for TB, and culture. Chest radiography (CXR) and High Resolution Computed Tomography (HRCT) of chest are useful imaging tests <sup>(3)</sup>.

### Correspondence:

Dr. Rasaiah Manmathan,  
Senior Registrar in Respiratory Medicine  
National Hospital Kandy  
Sri Lanka  
Ph: 0771348161  
E-mail: rmanmathan5@gmail.com

Adult onset of still disease (AOSD) is a systemic disorder of unknown etiology which is characterized by fever, rash, lymphadenopathy and multiorgan involvement. It is a rare disease with a prevalence of 1 in 100,000.<sup>(1)</sup> ASOD is common in young adults with a bimodal distribution at 15-25 and 36-46 years of age<sup>(4)</sup>. Diagnosis of ASOD is difficult in the absence of specific clinical features or tests. It is important to exclude infection and multisystem disorders with similar presentation. Several criteria have been proposed to diagnose ASOD, Yamaguchi's and Fautrel's criteria being the mostly used <sup>(5,6)</sup>.

The Yamaguchi's criteria require five or more criteria where two or more must be major criteria which are Fever >39 °C lasting 1 week or longer, Arthralgia or arthritis lasting 2 weeks or longer, typical rash and Leukocytosis >10,000/mm<sup>3</sup> with >80% polymorphonuclear cells. The minor criteria are sore throat, recent development of lymphadenopathy, hepatomegaly or splenomegaly and abnormal liver function tests. Tests for

antinuclear antibody, and rheumatoid factor (IgM) should be negative <sup>(5)</sup>.

Fautrel's criteria requires four or more major criteria or 3 major and 2 minor criteria. The Major criteria are Spiking fever  $\geq 39$  °C, Arthralgia, transient erythema, Pharyngitis, Polymorphonuclear cells  $\geq 80\%$  and glycosylated ferritin  $\leq 20\%$ . The minor criteria are maculopapular rash and leukocytosis  $\geq 10,000/\text{mm}^3$ . Both criteria do not include pericardial disease. (6) With extensive literature review we could not find occurrence of tuberculosis with AOSD.

### Case presentation

A 46-year-old male presented with high grade, intermittent daily fever for 1-month duration which responded to paracetamol. He also complained of arthralgia of small joints of both hands and feet with morning stiffness. He didn't have skin rash or sore throat. He denied history of cough, hemoptysis or contact history of TB. He did not have any remarkable past medical history and was not on any medication.

On examination he was febrile. He did not have lymphadenopathy, joint swelling or rash. There was hepatosplenomegaly of 1cm each. The rest of examination was normal. His lab investigations revealed a neutrophil leukocytosis (white cell count 14 000, N-82%), normal red cell and platelet parameters and normal renal function. Blood, urine and sputum cultures were sterile. His Erythrocyte Sedimentation Rate was 90mm/hour, C-Reactive Protein was 70mg/dL, Gamma GT was 180U/L, Alkaline phosphatase was 220U/L, Aspartate Transaminase was 65U/L, Alanine Transaminase was 70U/L. Sputum for Acid Fast Bacilli (AFB) 3 samples and PCR for TB [gene X pert] were negative, CXR at the disease onset was normal (figure-1).

Mantoux was 12mm. Serum ferritin was elevated at 2550ng/ml. Serology for HIV was negative. Ultrasound scan showed mild hepatosplenomegaly. His autoimmune profile such as Anti-nuclear antibody (ANA), Extracted nuclear antigen panel (ENA), Rheumatoid factor (RF), Anti-CCP antibody, Anti double stranded DNA were negative.

Transthoracic echocardiogram showed thin pericardial effusion with normal left ventricular

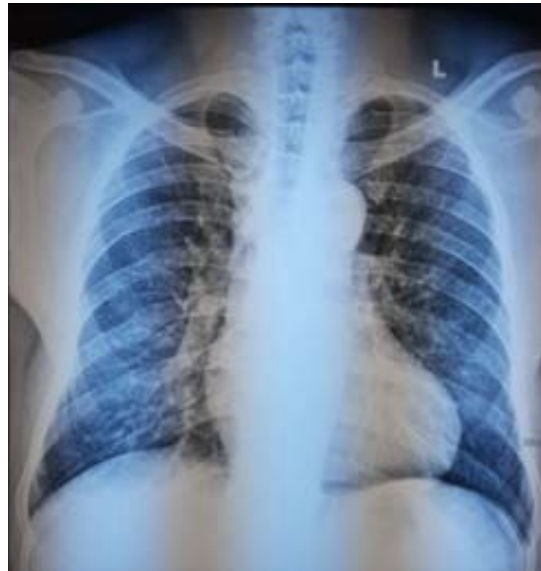

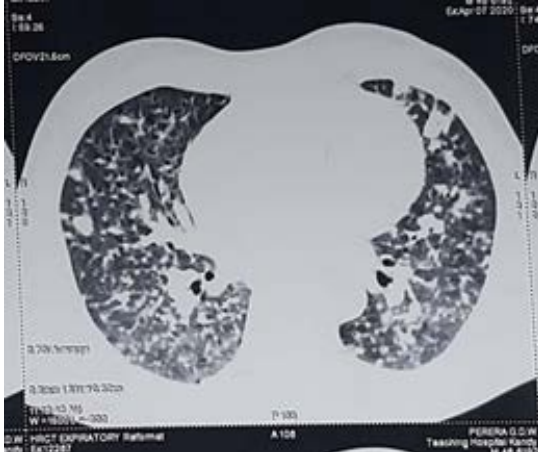
Figure -1 : CXR at the disease onset

function. The patient developed breathlessness after two days and repeat echocardiography revealed a moderate pericardial effusion. Pericardiostomy and pericardial biopsy was done. The pericardial fluid was negative for pyogenic culture, TB culture, and gene Xpert. Histopathology of pericardial tissue revealed no granuloma or evidence of malignancy but showed evidence of an inflammatory response. As the currently used criteria were fulfilled, we made a diagnosis of ASOD and the patient was commenced on Non-Steroidal Anti Inflammatory Drugs and subsequently high dose steroids (50mg). Fever subsided and the pericardial effusion completely resolved within one week. After two weeks of symptom free interval he presented again with fever, cough, and worsening breathlessness. Repeat CXR revealed bilateral patchy consolidation (figure-2).

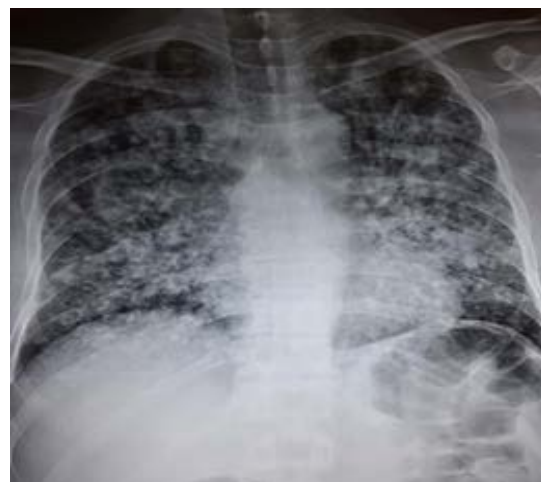

Figure-2 : The CXR following the treatment of AOSD

Sputum AFB was negative but gene Xpert gave a positive result on the first sample. The HRCT chest revealed centrilobular nodules and tree in bud appearance suggestive of endobronchial spread of infection (figure-3).



**Figure-3 : The HRCT chest following the treatment of AOSD**

We reconsidered the diagnosis and tapered off steroids, stopping NSAID. Anti TB drugs were commenced after obtaining sputum for mycobacterial culture. Following initial good response of five days the fever recurred with arthralgia. This was settled following recommencement of steroids and NSAID. We concluded that this patient has ASOD which was followed by rapid development of Tuberculous bronchopneumonia.

## DISCUSSION AND CONCLUSION

The initial clinical presentation of our patient had a wide differential diagnosis including infections, connective tissue disorders and vasculitis. As the diagnostic criteria of AOSD highlights, we did a thorough work up to exclude infections and Connective tissue diseases. Although the Yamaguchi's and Fautrel's criteria do not include pericardial disease, it has been reported to occur with AOSD (7). The patient in this report fulfilled 3 major and 2 minor Yamaguchi's criteria. The ferritin level was elevated but glycosylated fraction could not be used due to non availability.

With ongoing fever and pericardial effusion with a positive Mantoux test of 12mm TB pericarditis was also considered a high possibility at the initial presentation. It was excluded as bacteriology and histology was negative for TB. When high dose

steroids were commenced isoniazid prophylaxis was not initiated due to the elevated liver enzymes. Whether isoniazid would have prevented occurrence of TB or the possibility of induction of isoniazid resistance when used as monotherapy in this situation as the severe bronchopneumonia occurred just two weeks of steroid therapy remains to be answered. But the close follow-up and the high sensitivity, specificity and rapidity of gene Xpert of sputum<sup>(8)</sup> enabled us to arrive at a quick diagnosis. This was important as many other pathogens could cause severe broncho- pneumonia in patients on high dose steroid therapy.

Chest imaging is useful to assess the extent of pulmonary TB. It showed an extensive broncho-pneumonia in our patient. The HRCT identified micronodules which were mainly centrilobular with the typical tree in bud appearance suggestive of TB.

High dose steroid therapy is known to cause reactivation in latent TB leading to active disease. Whether ASOD per se causes reactivation of TB needs to be investigated.

ASOD is a rare disease, with diagnostic difficulties. We suggest to include pericardial disease in the diagnostic criteria. In latent TB close observation for occurrence active disease is important when using immunosuppressants.

## CONFLICT OF INTEREST

None

## REFERENCES

1. Eardley KS, Raza K, Adu D, Situnayake RD. Gold treatment, nephrotic syndrome, and multi-organ failure in a patient with adult onset Still's disease. *Ann Rheum Dis* 2001. Jan;60(1):4-5. 10.1136/ard.60.1.4 [PMC free article] [PubMed] [CrossRef] [Google Scholar]
2. WHO Global tuberculosis report 2017, World Health Organization, Geneva 2017.
3. Rozenshtein A, Hao F, Starc M.T, Pearson G.D. Radiographic appearance of pulmonary tuberculosis: dogma disproved. *AJR Am J Roentgenol*. 2015; 204: 974-978.
4. Kurasawa M, Kotani K, Kurasawa G, Shida K, Yamada S, Tago T. Adult-onset Still's disease in

- a patient over 80 years old successfully treated with low-dose methotrexate therapy. *Age Ageing* 2007. Jan;36(1):104-106. 10.1093/ageing/af1128 [PubMed] [CrossRef] [Google Scholar]
5. Yamaguchi M., Ohta A., Tsunematsu T., et al. Preliminary criteria for classification of adult Still's disease. *Journal of Rheumatology*. 1992;19(3):424–430. [PubMed] [Google Scholar]
  6. Fautrel B., Zing E., Golmard J.-L., et al. Proposal for a new set of classification criteria for adult-onset still disease. *Medicine*. 2002;81(3):194–200. doi: 10.1097/00005792-200205000-00003. [PubMed] [CrossRef] [Google Scholar]
  7. [Cardiac complications in adult onset Still disease: from pericarditis to tamponade as manifestations]. Drouot MH, Hachulla E, Houvenagel E, Hatron PY, Flipo RM, Goullard L, Ducloux G, Devulder B *Rev Med Interne*. 1994; 15(11):740-3.
  8. Steingart KR, Schiller I, Horne DJ, Pai M, et al. Xpert MTB/RIF assay for pulmonary tuberculosis and rifampicin resistance in adults. *Cochrane Database Syst Rev*. 2104;1:CD009593 Available from: <https://doi.org/10.1002/14651858.CD009593.pub3>.