

Modified Keles TPA –An Effective Method for Molar Derotation

Dr Amitabh Kallury,¹ Dr Jaina Dubey,² Dr Rajesh Kumar Balani,³ Dr Chandni Bharti⁴

¹Professor & Head, ²Post- Graduate Student, ^{3,4}Reader,
Department Of Orthodontics & Dentofacial Orthopedics, Peoples Dental Academy

Peoples University, Bhopal, India

Correspondence: Dr Jaina Dubey; Email: dubeyjaina@gmail.com

ABSTRACT

Mesio-palatal rotation of maxillary 1st molars is commonly encountered in clinical practice and this results in a Class I molar relation becoming end on. Traditionally transpalatal arches (TPA) fabricated with 0.036" stainless steel wires have been used for correction of molar rotation in fixed orthodontic treatment. They are not very efficient in correcting the mesio-palatal rotations and require frequent activations. This article describes a modified Keles TPA as an easy, effective method for rapid and precise correction of unilateral or bilateral mesio-palatal molar rotations.

Keywords: Class II, Keles TPA, Maxillary Molar, Molars relation, Rotation.

INTRODUCTION

In few cases, Class I molar relationships may convert into an end on relation due to mesio-palatal rotation of maxillary 1st molars. In these patients, a Class I molar relationship can be achieved by de-rotating the maxillary molars. This will also help in gaining additional arch length.

In 1972 Goshgarian¹ was the first to introduce the Transpalatal Arch (TPA) in the orthodontic literature. Cetlin and Ten Hove² described unilateral TPA activation as it causes successful de-rotation of molars on the affected side and least or no changes on the unaffected side. It would generate distal force on one side and rotation on the other side. After the correction of rotation of the molar on one side, they recommended subsequent activation to de-rotate the molar on the other side a few months later. They stated that the TPA is an effective device to stabilize, rotate, and distalize the molars. Unfortunately in cases with bilateral molar rotation, activating the conventional TPA one side at a time results in prolonged treatment time.

McNamara and Brudon³ have also indicated that the subsequent activation would generate a distal force on one side and rotation on the other side.

The Keles TPA, introduced by Ahmet Keles⁴ for effective & rapid derotation of molar, can simultaneously de-rotate the molars bilaterally. It was fabricated in a

0.032"x0.032" TMA wire and hence it had a long range of action without the need for frequent reactivation.

Technique

The original Keles TPA was fabricated with 0.032 × 0.032" Burstone lingual arch system wire and used a precision lingual hinge cap attachment. Since these are not commonly available in the Indian market, we modified the Keles TPA by fabricating it with 0.032" TMA wire with weldable palatal sheath.

The modified Keles TPA is fabricated with 0.032-inch of Beta-Titanium Alloy (TMA) wire. This wire is adapted on the patient's study model, about 2mm away from the palatal tissue. A helix with an internal diameter of 2 mm is incorporated bilaterally near the marginal gingiva. The wire is extended mesially and then doubled back to form tab. (Fig 1) TPA is checked on study model to ensure that it is passive. (Fig 2) Appropriate pre welded bands are selected for the maxillary 1st molars and a palatal sheath is welded on their palatal aspect. TPA is checked in patient's mouth to ascertain that it is not contacting the soft tissues and then removed for activation. Modified Keles TPA is placed on a piece of white paper and two lines are drawn along the terminal ends (rotating component) of the TPA with a pen (passive stage). (Fig 3) Additional lines are drawn with a red pen, with a 20-degree angle passing through the distal end of the helix of the wire and the TPA is activated.(Active Stage) (Fig 4) It is checked on both sides (Fig 5) and then inserted in the palatal sheath from the distal aspect.

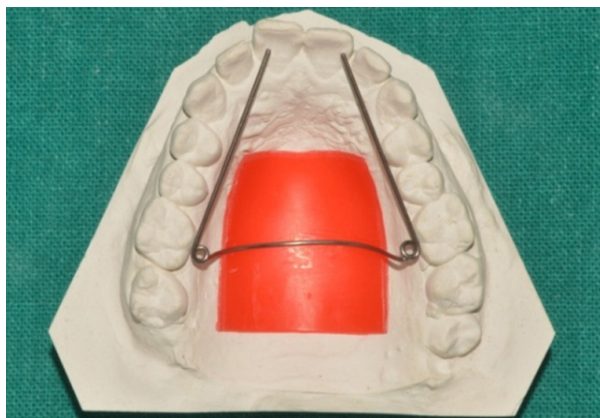

Figure 1: TMA wire (0.032) adapted on the palatal surface about 2mm away from the palatal tissue with helix on both sides

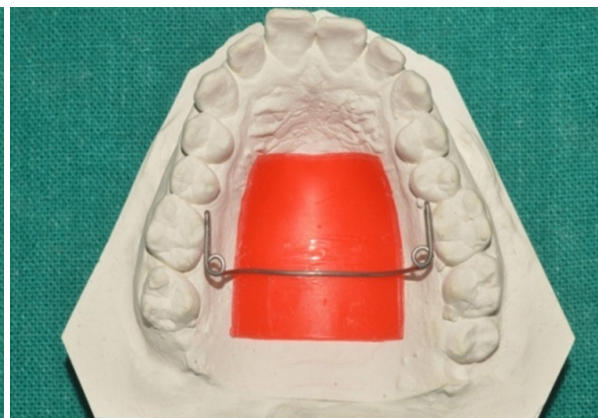

Figure 2: Passive Construction of Keles TPA




Figure 3: Passive Stage




Figure 4: Active stage with 20° activation

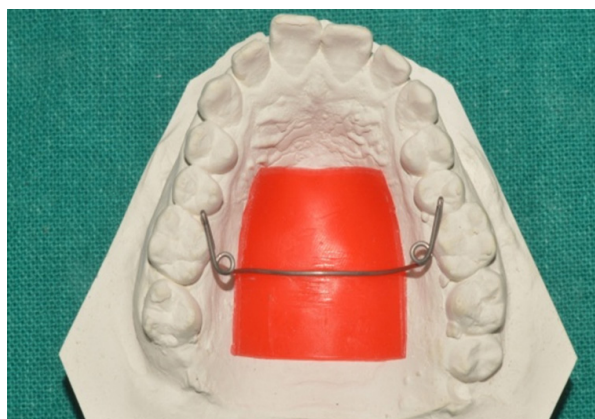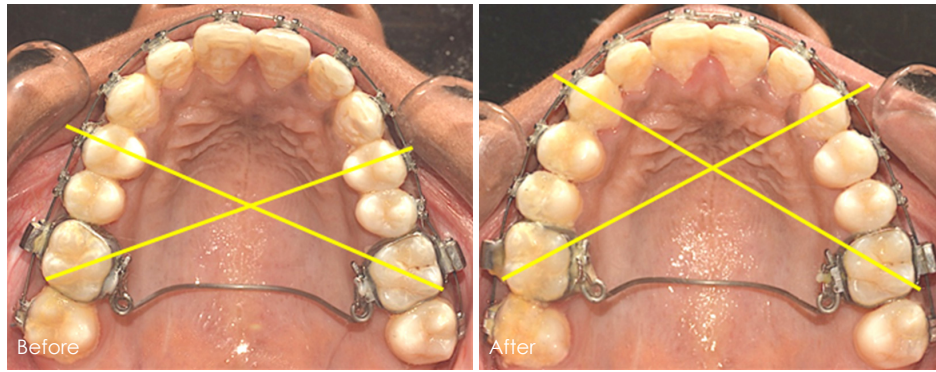


Figure 5: Activated TPA checked on study model

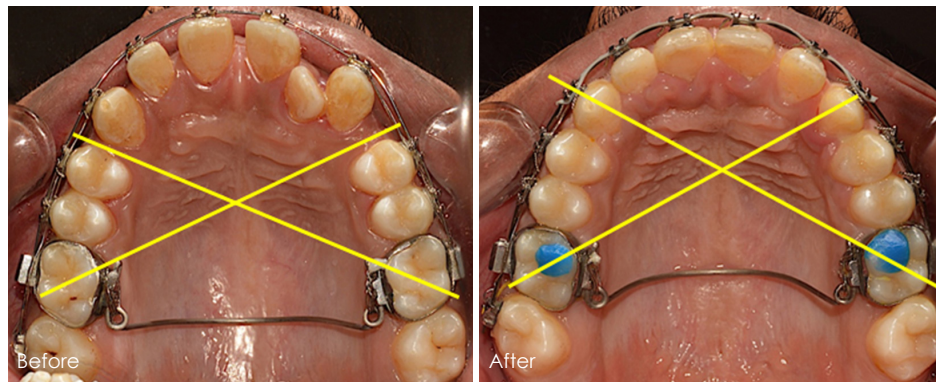
DISCUSSION

In many cases Class I molar relationship and an increase in arch length can be achieved by de-rotation of maxillary molars. According to Ricketts⁵ a line drawn from the distobuccal and mesio-palatal cusp tips of the first molars should pass through the cusp tip of the canines on the opposite side. According to Lima et al⁶

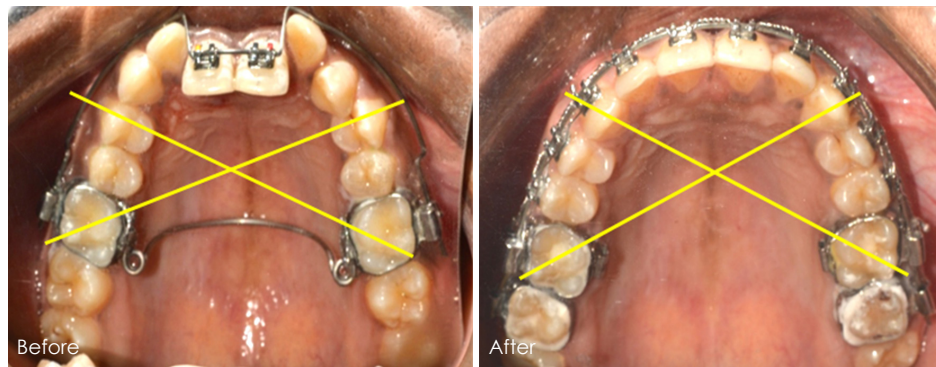
a positive correlation was seen between the severity of Class II div 1 malocclusion and the magnitude of mesio-palatal rotation in maxillary 1st molar. Giuntini et al⁷ reported that 80% of subjects with a Class II molar relationship had mesially rotated maxillary 1st molar. Various researchers have examined the arch length gain with derotation.⁸⁻¹¹ that can convert a borderline case into non extraction.



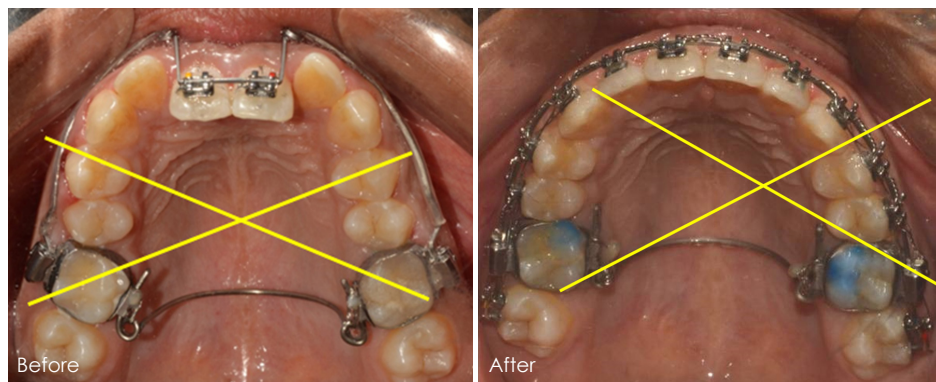
CASE 1:- N.P/ 20/F



CASE 2:- R.S /22 /M



CASE 3:- P.S/19/F



CASE 4:- H.J /17/ F

The main advantage of Keles TPA over conventional TPA is wire that it allows constant and long-lasting light force (low load deflection), without the need

for frequent reactivation due to the incorporation of helices and the use beta-titanium alloy.

ON

REFERENCES

1. Goshgarian RA. Orthodontic palatal arch wires. Washington DC: United States Government Patent Office; 1972.
2. Cetlin NM, Ten Hove A. Nonextraction treatment. *J Clin Orthod* 1982;17:396–413.
3. McNamara JA, Brudon W. Orthodontics and dentofacial orthopedics. Ann Arbor: Needham Press; 2002:208
4. Ahmet Keles and Sentef Impram: An Effective and Precise Method for Rapid Molar Derotation: Keles TPA, *World J Orthod*. 4:229–236,2003.
5. Ricketts RM. Futures of light progressive technique. No. 5. Denver: Rocky Mountain Dental Products, 1972.
6. Lima BP, Maio Pinzan-Vercelino CR, Dias LS, Bramante FS, De Jesus Tavarez RR. Correlation between the rotation of the first molars and the severity of class II division 1 malocclusion. *The Scientific World Journal*. 2015;2015.
7. Giuntini V, Baccetti T, Defraia E, Cozza P, Franchi L. Mesial rotation of upper first molars in Class II division 1 malocclusion in the mixed dentition: a controlled blind study. *Progress in orthodontics*. 2011 1;2:107-13.
8. Cook MS, Wreakes G. Molar de-rotation with a modified palatal arch: An improved technique. *Br J Orthod* 1978;5: 201–203.
9. Orton HS. An evaluation of five methods of de-rotating upper molar teeth. *Dent Practit* 1966;16:279–286.
10. Rebellato J. Two couple orthodontic appliance systems: Transpalatal arches. *Semin Orthod* 1995;1:44–54.
11. Braun S, Kusnoto B, Evans C. The effect of maxillary molar derotation on arch length. *Am J Orthod Dentofacial Orthop* 1997;112:538–544.