

The Extraction-Non Extraction Conundrum and the Role of Self Ligation in Present Day Mechanotherapy

Dr Sagar Dahiya,¹ Dr Gunjan Negi,² Dr Anmol Arya,³ Dr Prasad Chitra⁴

¹Dental Officer & Orthodontist, Department of Orthodontics & Dentofacial Orthopedics, 4 Corps Dental Unit, Assam, India

²Resident, ³Former Resident, ⁴Professor & Head, Department of Orthodontics and Dentofacial Orthopedics, Army College of Dental Sciences, Secunderabad, Telangana, India.

Correspondence: Dr. Prasad Chitra; Email: prasadchitra@yahoo.co.uk

ABSTRACT

Rapid technological advancements in the orthodontic field in recent years have enabled clinicians to treat an increasing number of patients using non extraction approaches. Self ligating brackets are becoming increasingly popular as they enable rapid movement of teeth with lateral arch development negating the need to extract teeth.

Two Class I malocclusion patients presenting with moderate to severe anterior crowding were treated non-extraction with self ligating fixed appliances. The cases presented illustrate the versatility of self ligating brackets in management of malocclusions with extensive transverse and sagittal components. A review of literature discussing the changing paradigms from extraction to non extraction and use of self ligation is highlighted.

Keywords: Damon, Lateral development, Non extraction, Self ligation.

INTRODUCTION

The most popular unresolved debate in Orthodontics commenced officially in 1911 at a meeting of the National Dental Association where Calvin Case and Martin Dewey presented their point of views on the treatment protocols of extraction and non-extraction cases.¹ The debate is not new but has been prevailing since the era of John Hunter,² who opposed the extraction of teeth on the basis that it inhibited growth of the jaws. Angle, who previously extracted teeth initially to improve facial profiles was influenced by Rousseau and changed his perspective attempting to attain ideal relationships of teeth without recourse to extractions.²

The re-introduction of extractions into orthodontics occurred in the mid-20th century, when Tweed, a disciple of Angle, observed relapse in cases treated without extractions of teeth. In the 1944 AAO meeting in Chicago, Tweed showed cases retreated with first premolar extractions which initially were treated non extraction and had developed severe relapse.³ In the late 1990's, Mc Reynolds et al⁴ and Little et al⁵ discouraged premolar extractions and stated that instability of tooth alignment was caused by extractions.

The debate over extraction and non extraction therapy continues till date. Extractions were rare in the early 20th century, peaked in the mid 1960s at about 75%, showed a decline in the early 1980s-1990s to about 15%-20% and remained there for few years of the 21st century.³ In recent years, there has been a definite shift in orthodontics towards non extraction treatment for an increasing number of malocclusions with focus on newer appliance systems like self ligating brackets and use of auxiliaries like TADs, enabling complex tooth movements. Claiming to possess various advantages over conventional twin edgewise brackets, self-ligating brackets have gained popularity in recent years.

One of the main advantages claimed by proponents of these brackets is reduced friction between the wire and the slot, thereby producing more physiologic and harmonious tooth movement.⁶⁻⁸ Therefore, less force is needed to move teeth, enabling more alveolar bone generation, as brackets do not overpower the musculature and the periodontal vascular supply remains uninterrupted. It is asserted that passive designs generate even less friction than active ones.⁹⁻¹² However, there is no clinical evidence of a superiority of one design over the other.¹³ Additional advantages cited are proper arch

wire engagement, lateral development, longer treatment intervals with fewer appointments and reduced chair side time.¹⁴⁻¹⁷

This article is an attempt to highlight the shift in treatment philosophy towards facially driven orthodontics with esthetics and long term stability of treated results taking precedence. Two cases of moderate crowding treated with self ligating appliances are presented.

CASE REPORT 1

A 16 year old male presented with a chief complaint of irregular upper and lower front teeth.

He showed a convex profile, obtuse nasolabial angle and mildly increased lower anterior facial height (Figure 1A).

Intraorally, there was moderate crowding in both arches, bilateral highly placed maxillary canines with reduced overjet and overbite and Class I molar relation on both sides (Figure 1B). Cephalometric analysis revealed an ANB of 5°, Wits of 4mm, lower incisor to A-Pog increased at 4mm with the nasolabial angle increased to 139° (Table 1).

Treatment was planned non extraction with Nexus 0.022" self ligating appliances (Ormco Corp, Glendora, USA) to enable correction using a combination of mild incisor proclination which would reduce the nasolabial angle, and transverse arch development. Levelling and aligning was accomplished using 13" CuNiTi wires followed by 16 x 22" CuNiTi , 18 x 25 CuNiTi and 19 x 25 stainless steel (Figure 2).

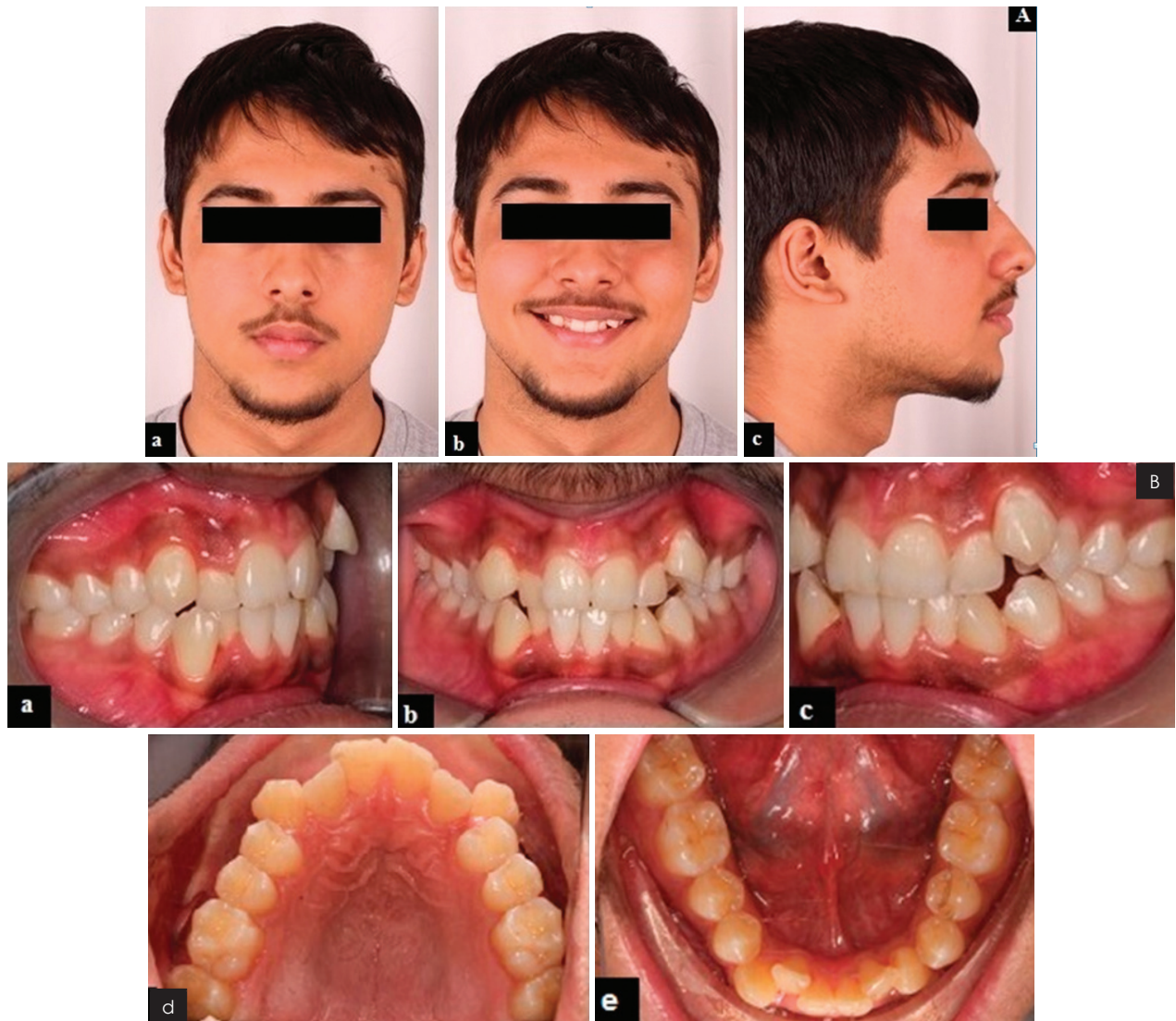


Figure 1: (A) Pretreatment extraoral photographs. (a) Frontal at rest, (b) frontal smiling, (c) profile. (B) Pretreatment intraoral photographs. (a) Right lateral, (b) frontal, (c) left lateral, (d) maxillary occlusal, (e) mandibular occlusal

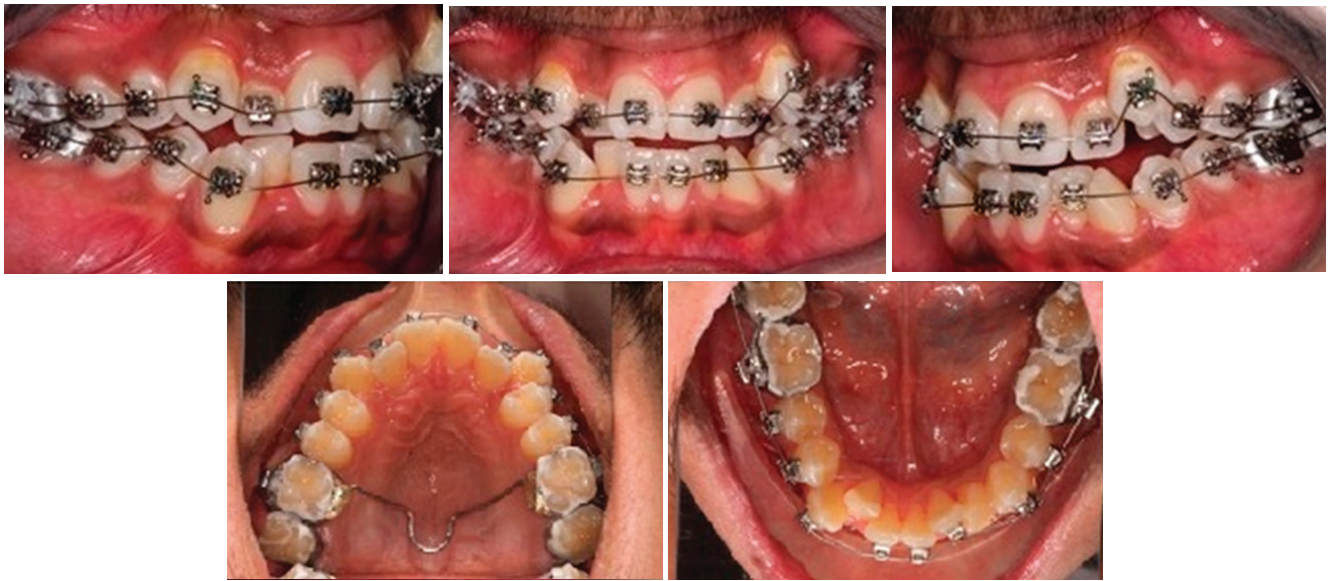

Figure 2: Appliance placement with aligning archwires

Finishing and settling was carried out with 14" stainless steel wires and elastics. Treatment was completed in 16 months (Figure 3).

Class I occlusion with well aligned arches and improved arch form was achieved. The post treatment

cephalometric changes included a reduction in Wits to 1mm, lower incisor to A-Pog ideal at 1mm and nasolabial angle average at 108° as compared to pre treatment values (Table 1, Figure 4).

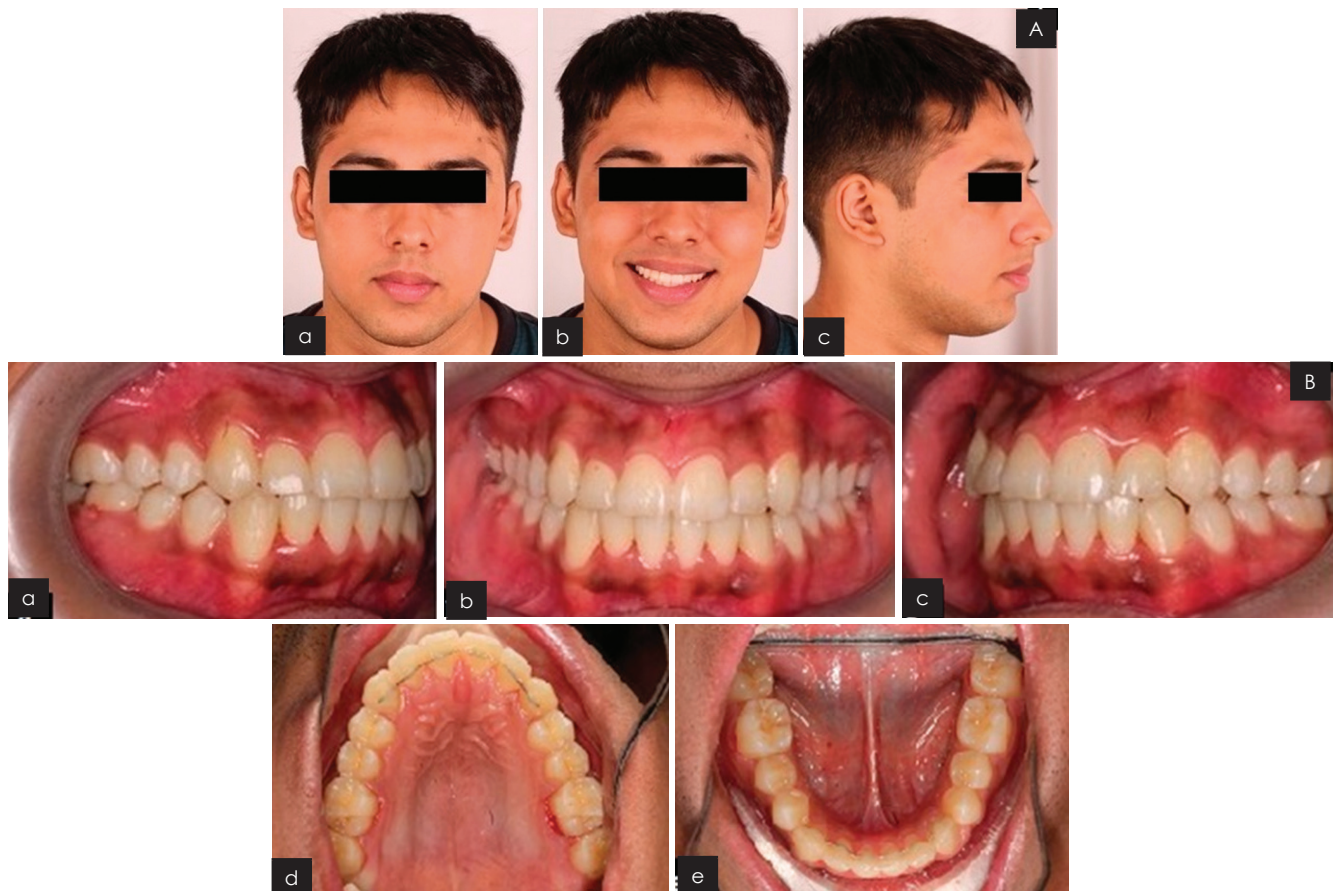

Figure 3: (A) Posttreatment extraoral photographs. (a) Frontal at rest, (b) frontal smiling, (c) profile. (B) Posttreatment intraoral photographs. (a) Right lateral, (b) frontal, (c) left lateral, (d) maxillary occlusal, (e) mandibular occlusal

VARIABLES	PRE-TREATMENT	POST-TREATMENT
SNA	83°	84°
SNB	78°	80°
ANB	5°	4°
Wits appraisal	4mm	2mm
Mandibular plane angle	25°	28°
U1- Maxillary plane angle	110°	118°
IMPA	110°	118°
Nasolabial angle	127°	108°
Lower lip to Apo line	2mm	3mm

Facial esthetics were significantly improved with the patient satisfied with achieved results. The case was retained with use of bonded retainers in both arches. The use of self ligating brackets in this situation enabled rapid tooth movement with minimum stress on anchorage and lateral arch development to gain space. Extractions to enable de crowding were avoided as a result. Records obtained 2 years post treatment show a stable well settled occlusion with good esthetics (Figure 5).

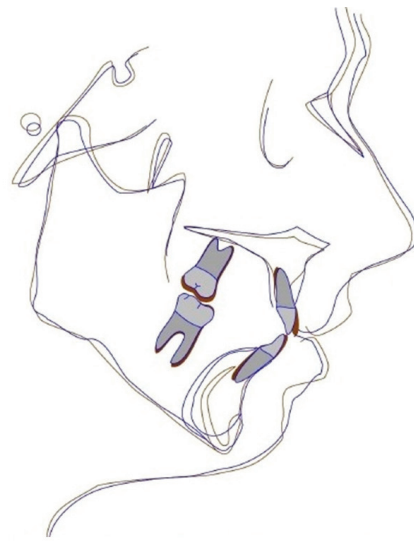


Figure 4: Pre treatment and post treatment superimposition

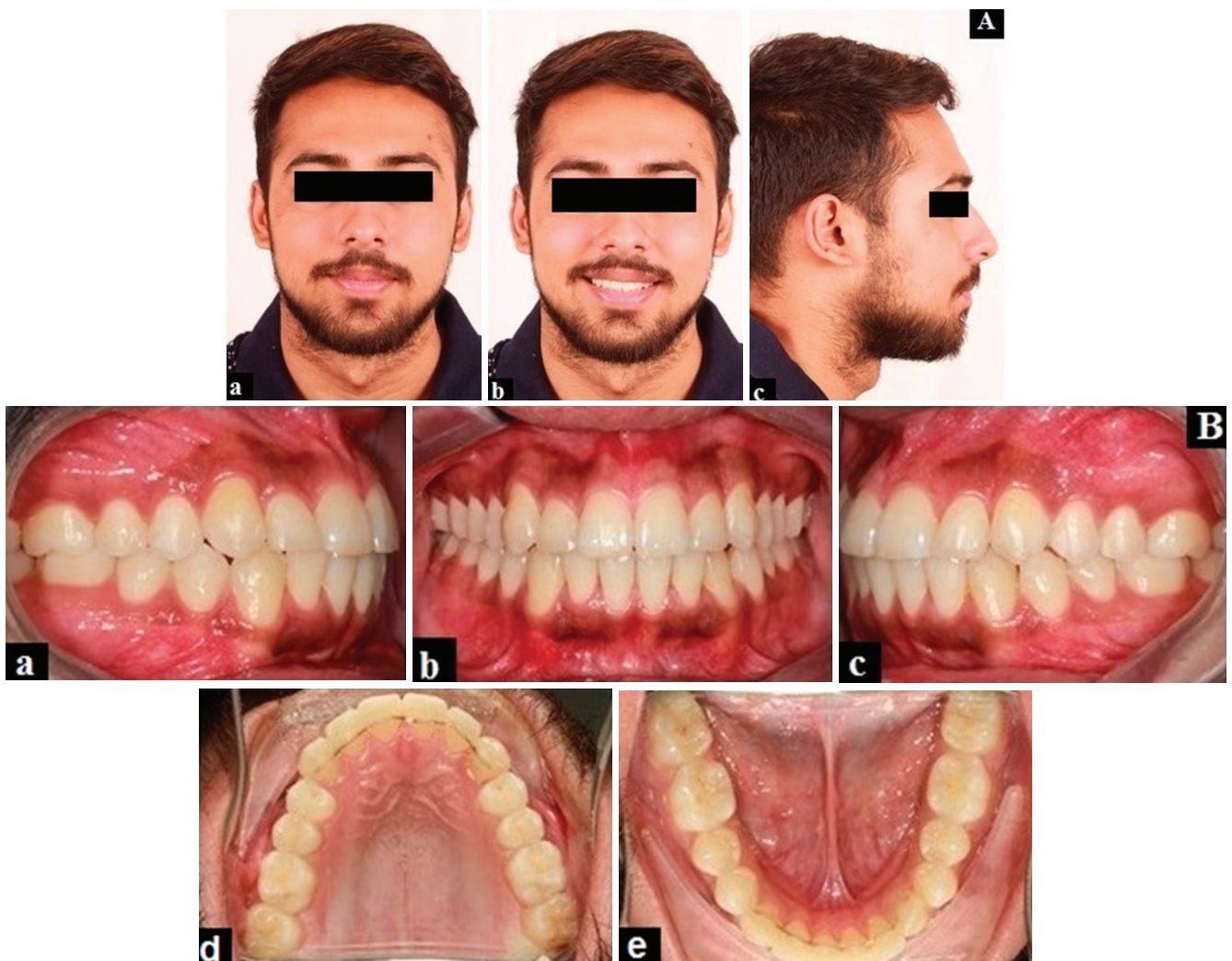

Figure 5: Two year follow up. (A) Posttreatment extraoral photographs. (a) Frontal at rest, (b) frontal smiling, (c) profile. (B) Post-treatment intraoral photographs. (a) Right lateral, (b) frontal, (c) left lateral, (d) maxillary occlusal, (e) mandibular occlusal

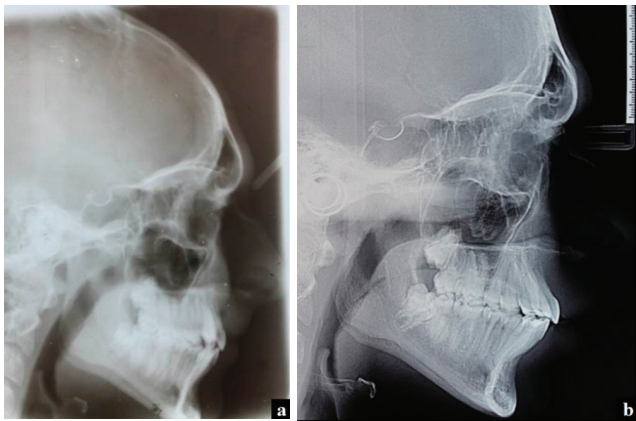


Figure 6: Comparison of (a) pre and (b) post-treatment lateral cephalograms

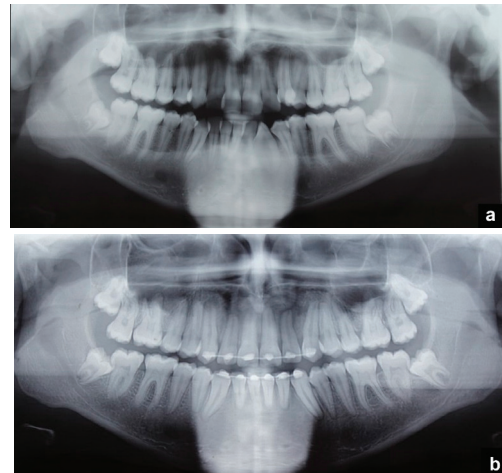


Figure 7: Comparison of (a) pre and (b) post-treatment OPG's

CASE REPORT 2

A 13 year old female presented with a chief complaint of irregular and forwardly placed upper front teeth. She showed a convex profile, average nasolabial angle and lack of lip seal (Fig 8A). Intraorally, there was moderate crowding in both arches, a highly placed maxillary canine

on right side with an overjet and overbite of 4mm and Class I molar relation bilaterally (Fig 8B, 9).

Cephalometric analysis revealed an ANB of 5°, Wits of 5mm and lower incisor to A-Pog increased at 6mm (Table 2).

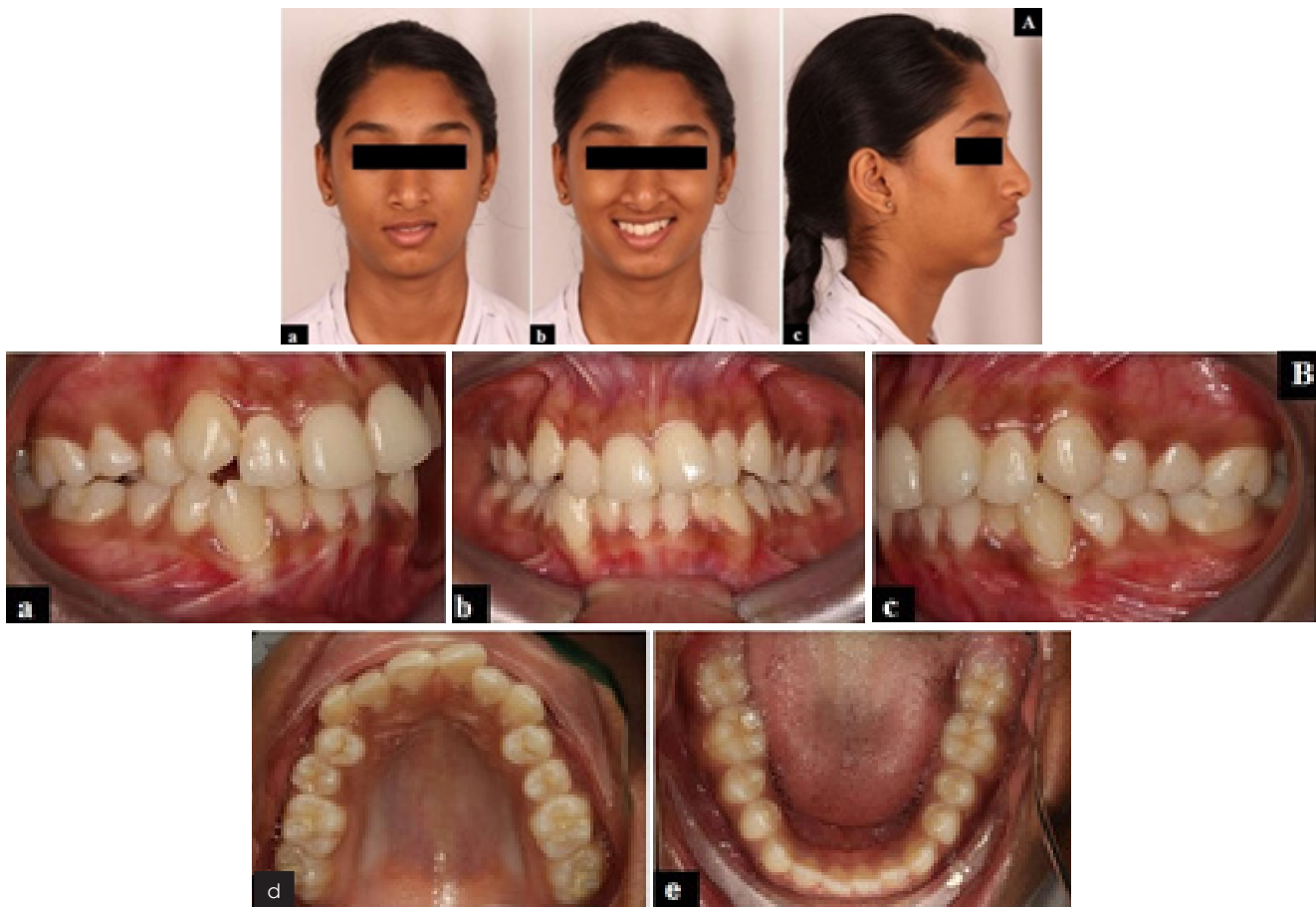


Figure 8: (A) Pretreatment extraoral photographs. (a) Frontal at rest, (b) frontal smiling, (c) profile. (B) Pretreatment intraoral photographs. (a) Right lateral, (b) frontal, (c) left lateral, (d) maxillary occlusal, (e) mandibular occlusal

The case was managed non extraction using Damon3MX 0.022" self ligating appliances(Ormco Corp, Glendora, USA). Leveling and aligning was accomplished using 14CuNiTi wires followed by 14 x 25CuNiTi , 18 x 25 CuNiTi and 19 x 25 stainless steel (Fig 10).

Finishing and settling was accomplished with 14" stainless steel wires and elastics. Treatment was completed in 15 months with a good Class I occlusion and well aligned arches at the end of treatment (Fig 11A, B).

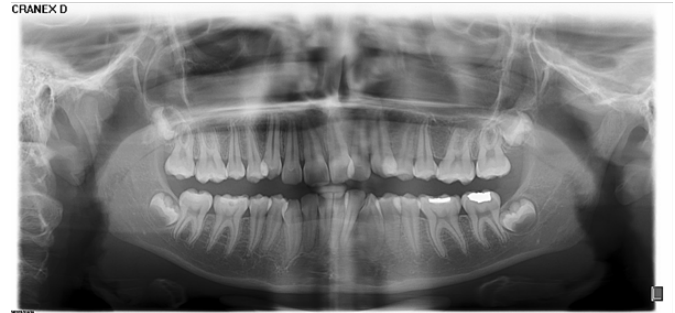

Figure 9: Pre-treatment OPG

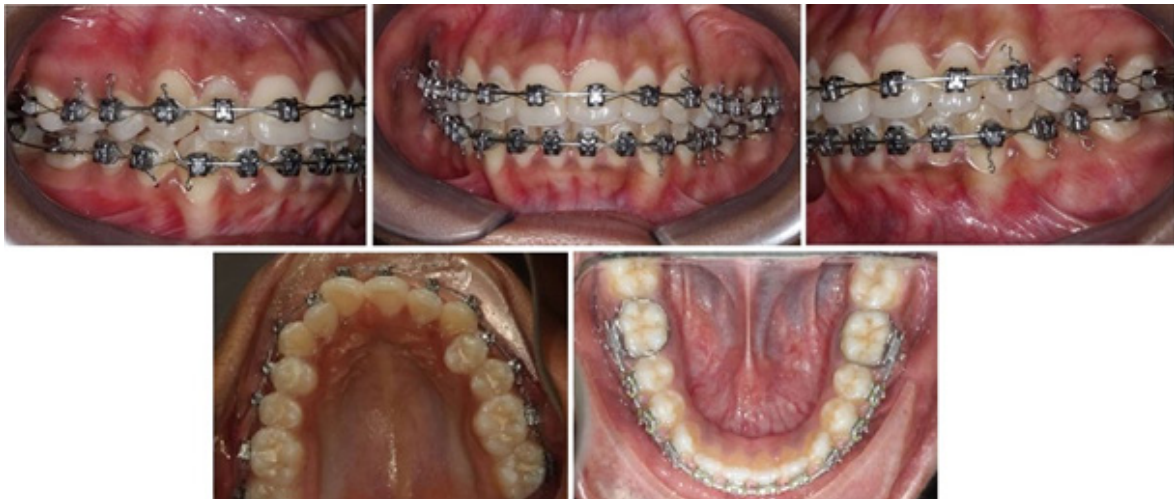

Figure 10: Appliance placement with aligning archwires

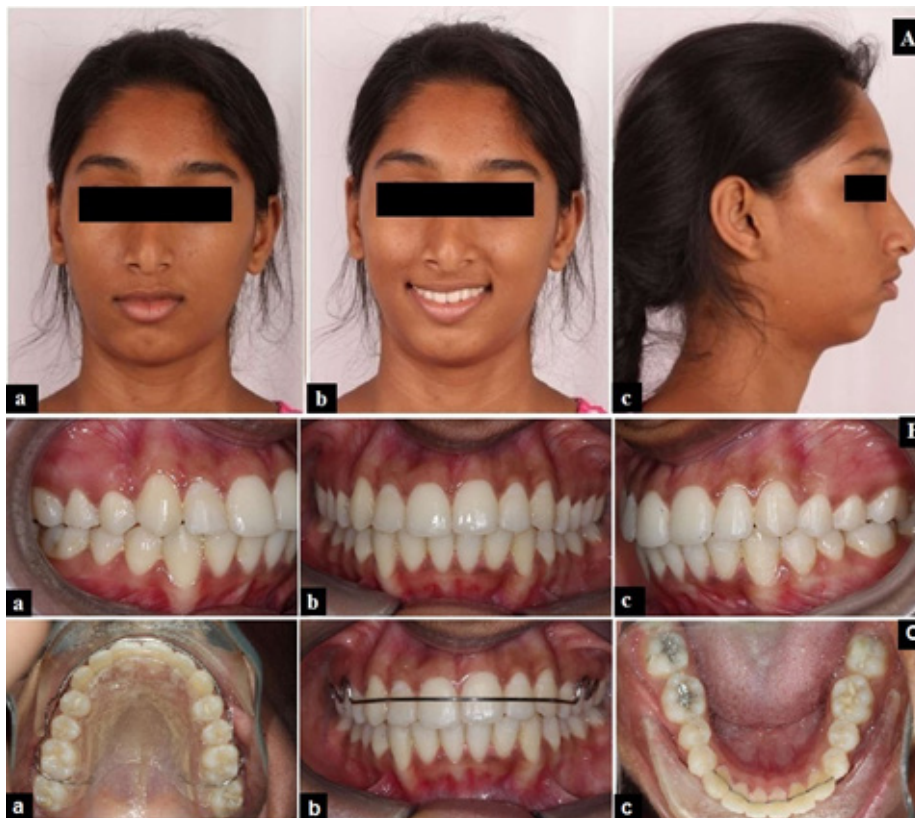

Figure 11: (A) Posttreatment extraoral photographs. (a) Frontal at rest, (b) frontal smiling, (c) profile. (B) Posttreatment intraoral photographs. (a) Right lateral, (b) frontal, (c) left lateral. (C) Retainers. (a) maxillary occlusal view with wrap around retainer, (b) frontal view, (c) mandibular occlusal view with canine to canine lingual bonded retainer

VARIABLES	PRE-TREATMENT	POST-TREATMENT
SNA	79°	82°
SNB	74°	80°
ANB	5°	2°
Wits appraisal	5mm	0mm
Mandibular plane angle	26°	27°
U1- Maxillary plane angle	119.5°	108°
IMPA	105°	92°
Nasolabial angle	98°	95°
Lower lip to Apo line	6mm	1mm

Overjet and overbite were ideal at treatment end with significant improvement in overall facial esthetics. The post treatment cephalometric changes included a reduction in Wits to 0mm, lower incisor to A-Pog ideal at 1mm and increased nasolabial angle of 111° post treatment (Table 2, Fig 12).

A combination of incisor proclination and lateral arch development enabled correction with no deleterious effects on facial profile(Fig 13). Retention was a combination of an upper removable wraparound and lower canine to canine bonded retainer (Fig 11C).

DISCUSSION

Both cases described were Class I malocclusions with moderate amounts of crowding. Treatment planning had to also take into consideration the amount of growth remaining, facial type and arch forms. Both patients did not want extractions of teeth for correction of the malocclusion. Additionally, soft tissue features like the nasolabial angle, lip position and type and facial profile had to be taken into consideration. Significant amounts of tooth movement using non extraction approaches were required. Keeping these factors in mind, a decision to use self ligating brackets was taken. Present day evidence indicates that self ligating bracket systems show decreased frictional resistance, enable shorter chair side times and better infection control as compared to conventional brackets using elastomeric or stainless steel ties for ligation of arch wires.¹⁸ Self ligating brackets, both active and passive are supposed to exhibit reduced friction to sliding and better arch form development. This was confirmed in a study carried out by Vale et al whose findings indicated that self ligating brackets exhibited reduced resistance to sliding. However, findings of a randomized clinical trial comparing them with conventional brackets for maxillary arch dimensional changes have been

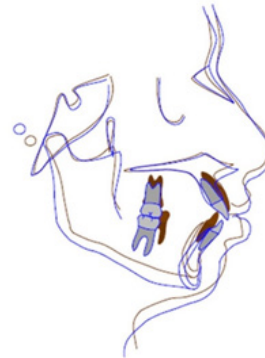

Figure 12: Pre and post treatment superimposition

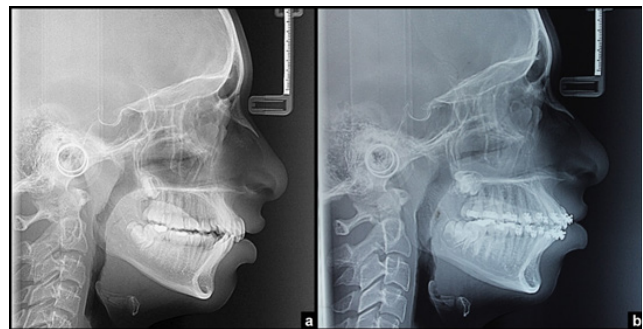


Figure 13: Comparison of (a) pre and (b) pre finishing lateral cephalogram

inconclusive with results being the same irrespective of the type of bracket system used.¹⁹ However, use of self ligating appliances enabled rapid tooth movement with no need for anchorage reinforcement except use of a transpalatal arch in the first case which was primarily to prevent deleterious upper molar extrusion and increase in lower face height. Lateral arch development was also good in both cases with improved arch form and space creation for relief of crowding. The buccal corridors also reduced with improved smile esthetics.

Several studies over the last few years have shown that dental extractions carried out for orthodontic treatment increase treatment duration.²⁰ The frequency of extractions for correction of malocclusion has been showing a decreasing trend over the last few years.²¹ This is primarily due to greater focus on facial proportions and long term changes, better and more refined appliance systems enabling rapid tooth movement and use of adjuncts like micro implants widening the treatment envelope. An attempt was thus made to treat both patients using newer approaches without being dogmatic and considering only the extraction paradigm.

CONCLUSION

1. Self ligating appliances permit a larger number of patients with mild to moderate malocclusions to be treated without recourse to premolar extractions.
2. Passive self ligating appliances can be used in well selected cases with satisfactory results in a short time with minimal archwire changes and long appointment duration benefitting the operator and patient.
3. Modern day orthodontics is evolving rapidly with integration of sound biological concepts and technology, enabling clinicians to understand and use self ligating appliances optimally for the benefit of patients.

ON

REFERENCES

1. Wahl N. Orthodontics in 3 millennia, Chapter 6: More early 20th-century appliances and the extraction controversy, *Am. J. Orthod.* 128:795-800, 2005.
2. Khanum A, Prashantha GS., Mathew S, Naidu M, Kumar A. Extraction vs Non Extraction Controversy: A Review. *J of Dent& Oro-fac Res.* 2018; 14(1):41-8.
3. Rinchuse DJ, Busch LS, DiBagno D, Cozzani M. Extraction treatment, part 1: the extraction vs. nonextraction debate. *J Clin Orthod.* 2014 Dec;48(12):753-60.
4. McReynolds DC, Little RM. Mandibular second premolar extraction—post retention evaluation of stability and relapse. *Angle Orthod.* 1991;61(2):133-44.
5. Little RM, Wallen TR, Riedel RA. Stability and relapse of mandibular anterior alignment: University of Washington studies. In *Sem in Orthod.* 1999;5(3):191-204.
6. Thomas S, Sherriff M, Birnie D. A comparative in vitro study of the frictional characteristics of two types of self-ligating brackets and two types of pre-adjusted edgewise brackets tied with elastomeric ligatures. *Eur J Orthod.* 1998;20(5):589-96.
7. Kapur R, Sinha PK, Nanda RS. Frictional resistance of the Damon SL bracket. *J Clin Orthod.* 1998;32(8):485-9.
8. MonteiroMRG, da Silva LE, Elias CN, and de Vasconcellos Vilella O. Frictional resistance of self-ligating versus conventional brackets in different bracket-archwire-angle combinations. *J Appl Oral Sci.* 2014; 22(3): 228-234.
9. Kim TK, Kim KD, Baek SH. Comparison of frictional forces during the initial leveling stage in various combinations of self-ligating brackets and archwires with a custom-designed typodont system. *Am J Orthod Dentofacial Orthop* 2008;133(2):15-24.
10. Budd S, Daskalogiannakis J, Tompson BD. A study of the frictional characteristics of four commercially available self ligating bracket systems. *Eur J Orthod*2008;30:645-53.
11. Pandis N, Polychronopoulou A, Eliades T. Active or passive self-ligating brackets? A randomized controlled trial of comparative efficiency in resolving maxillary anterior crowding in adolescents. *Am J Orthod Dentofacial Orthop.*2010;137(1):12-e1.
12. Yang X, He Y, Chen T, Zhao M, Yan Y, Wang H, Bai D. Differences between active and passive self-ligating brackets for orthodontic treatment: Systematic review and meta-analysis based on randomized clinical trials. *J Orofac Orthop.* 2017;78(2):121-128.
13. Brauchli LM, Steineck M, Wichelhaus A. Active and passive self-ligation: a myth? Part 1: torque control. *Angle Orthod.* 2012;82(4):663-9.
14. Eberting JJ, Straja SR, Tuncay OC. Treatment time, outcome, and patient satisfaction comparisons of Damon and conventional brackets. *Clin Orthod Res.* 2001;4(4):228-34.
15. Turnbull NR, Birnie DJ. Treatment efficiency of conventional vs selfligating brackets: effects of archwire size and material. *Am J Orthod Dentofacial Orthop.* 2007;131(3):395-9.
16. Paduano S, Cioffi I, Iodice G, Rapuano A, Silva R. Time efficiency of self-ligating vs conventional brackets in orthodontics: effect of appliances and ligating systems. *Prog Orthod.* 2008;9(2):74-80.
17. Tecco S, D'Attilio M, Tete S, Festa F. Prevalence and type of pain during conventional and self-ligating orthodontic treatment. *Eur J Orthod.* 2009;31(4):380-4.
18. Shivpuja PK, Berger J. A comparative study of conventional ligation and self-ligation bracket systems. *Am J Orthod Dentofacial Orthop.*1994;106(5):472-80.
19. Vale F, Malo L, Caramelo F, Ramos J, Cavaleiro J. Dynamic behaviour and surface characteristics of conventional and self-ligating brackets. *Revista Portuguesa de Estomatologia Medicina Dentaria e Cirurgia Maxilofacial.*2016;57(1):1-8.
20. Dardengo C de S, Fernandes LQP, Capelli J. Frequency of orthodontic extraction. *Dental Press J Orthod.*2016;21(1):54-59.
21. Jackson TH, Guez C, Lin FC, Proffit WR, Ko CC. Extraction frequencies at a university orthodontic clinic in the 21st century. Demographic and diagnostic factors affecting the likelihood of extraction. *Am J Orthod Dentofacial Orthop.*2017;151(3):456-462.