

Ortho-surgical Management of Severe Skeletal Class II Div 2 Malocclusion in Adult

Dr Suchita Tarvade Daokar,¹ Dr Gauri Agrawal,² Dr Charushila Chaudhari,³ Dr Sheetal Yamyar⁴

¹Professor, ²PG Resident, ^{3,4}Senior Lecturer
CSMSS Dental College, Aurangabad, India

Correspondence: Dr Suchita Daokar; Email: suchitadaokar@gmail.com

ABSTRACT

Skeletal Class II malocclusion is attributed to maxillary prognathism, mandibular retrognathism or combination of both. In adolescent cases, the treatment includes growth modulation with headgear or myofunctional appliances. However in adults, optimum esthetic and functional efficacy can be achieved by orthodontic-surgical combination.

This case report describes a 21 years old post-pubertal male with severe skeletal Class II discrepancy with normal maxilla and retrognathic mandible. The case was treated with bilateral sagittal split osteotomy (BSSO) with mandibular advancement approach. Straight profile, pleasing esthetics, bilateral Class I molar and canine relationship, normal overjet and overbite were achieved because of a combined ortho-surgical approach.

Keywords: BSSO, Class II, mandibular retrognathism, Ortho-surgical

INTRODUCTION

Class II malocclusion cases are of interest to orthodontists since they constitute a significant percentage of cases they treat. However, they are one of the most challenging malocclusion to diagnose and treat with.

There lies a significant difference in prevalence of Class II malocclusion among various populations. Emmanuel¹ observed 1.1% prevalence in Nigerian, where as Silva *et al*² observed as high as 21.5% prevalence of Class II malocclusion in Latino adolescents. Prevalence of Class II malocclusion in India varies from 1.9% in Rajasthan to 8.37% in South India.^{3,4}

Class II malocclusions have dental or skeletal or combination entities. Furthermore, they can be attributed to maxillary prognathism, mandibular retrognathism or combination of both along with vertical and transverse problems. Success in the management of skeletal Class II case relies on proper diagnosis and treatment planning. The treatment approach of skeletal Class II depends upon growth status of the patient. In adolescent cases, growth modulation with either removable or fixed myofunctional appliances to stimulate mandibular growth, head gear to restrict excessive maxillary growth or a combination approach is recommended.

However in adults, esthetics is the major concern in severe Class II cases. The treatment of severe dentofacial deformities in adult patients is a challenging task for both orthodontist and oral surgeon. Treatment is difficult because of the skeletal and facial disharmony, absence of jaw growth and a tendency to relapse.⁵ Critical diagnosis and ortho-surgical combination treatment approach is to be relied on for gaining optimum esthetic harmony and functional efficiency. Furthermore, acceptance of facial appearance is the prime important factor in determining social relationship.⁶

Case Report

This case report describe a 21 years old male patient who reported to Orthodontic Department of Chatrapati Shahu Maharaj Sikshan Sanstha Dental College, Aurangabad, Maharashtra, India with the complain of irregularly placed teeth in upper front region of jaw.

Clinical examination

Extraorally, the patient exhibited square face with convex profile, competent lips and deep mentolabial sulcus. Intra-orally, patient presented with Class II molar and canine relation with retroclined central incisors, deep bite and scissor bite with 24. Arches exhibited moderate crowding with deep curve of Spee.



Figure 1: Pre-treatment extra-oral photographs

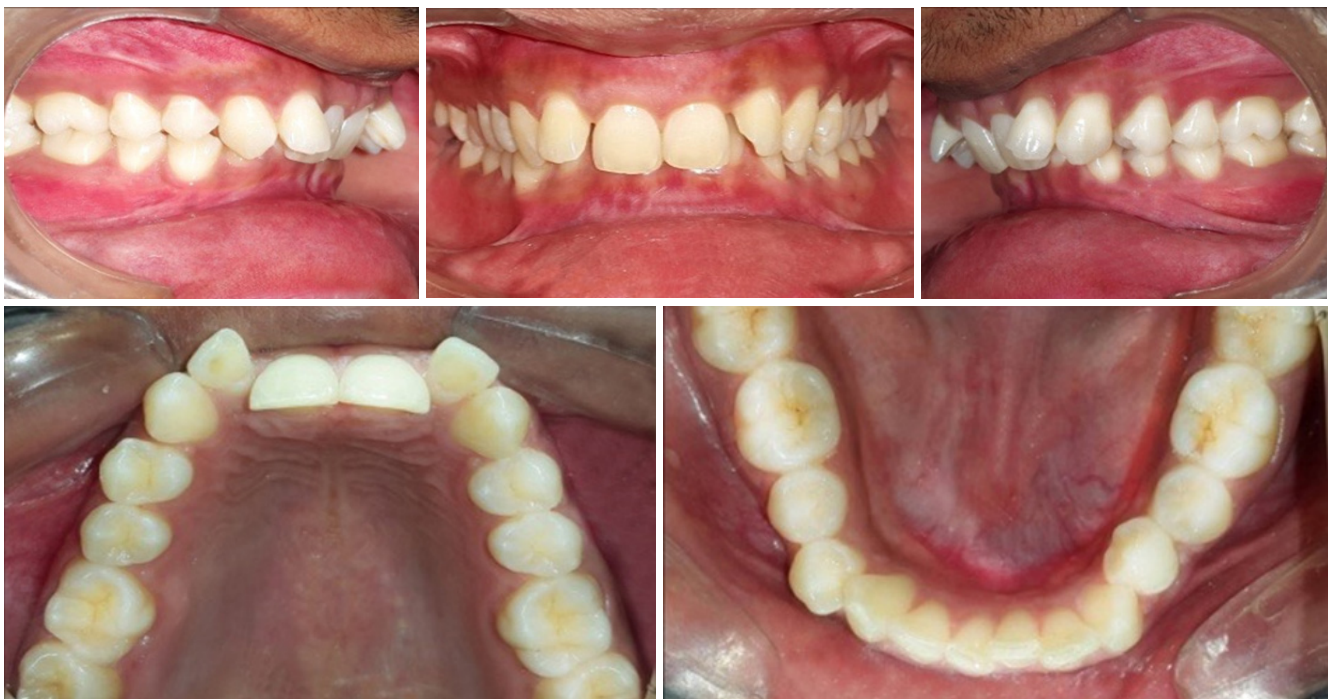

Figure 2: Pre-treatment intra-oral photographs

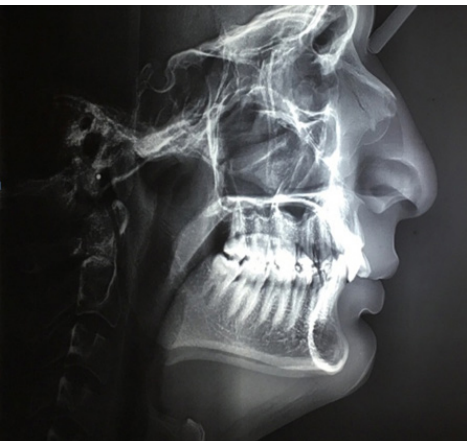

Figure 3 Pre-treatment lateral cephalogram

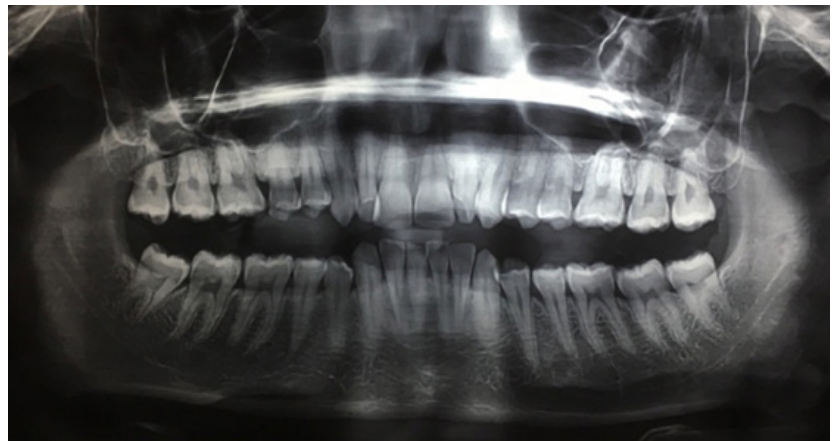


Figure 4: Pre-treatment OPG

Cephalometric analysis

COG's analysis was done to analyze the case. Cephalometric analysis revealed normal maxilla and retrognathic mandible (SNB 74°, ANB 6°, β angle 11°, W angle 48°, Angle of Convexity 9°) with horizontal growth pattern (SN-MP 21°, FH-MP 11°, FMPA 10°, Y axis 56°) (Table 1,2).

Table 1: Cephalometric readings

Parameters	Norms	Pre-treatment	Mid-treatment	Post-treatment
SNA	82	82	82	82
SNB	80	76	76	79
ANB	2	6	6	3
β Angle	27-34	11	14	24
W Angle	51-55	48	51	56
Facial angle	87.8	87	88	88
Angle of convexity	0	9	8	1
SN-MP	32	21	21	28
FH-MP	21.9	11	11	19
FMPA	25	10	10	18
Y axis	59.4	56	54	56
SN-OP	14	21	14	9

Table 2: Linear measurements on cephalogram

Parameters	Pre- treatment	Mid-treatment	Pos- treatment
Effective mandibular length	100 mm	100 mm	106
LAFH	52	53	60
Jaraback's ratio	75.4	75.2	69.4
U1-NA	-4mm	4 mm	4 mm
U1-A Pog	-1mm	4mm	5 mm
L1-NB	-2 mm	1 mm	4 mm
L1- A Pog	-3 mm	4 mm	4 mm
S line - upper lip	0 mm	0 mm	0 mm
S line - lower lip	-1 mm	-1 mm	0 mm



Figure 5: Mid-treatment extra-oral photographs

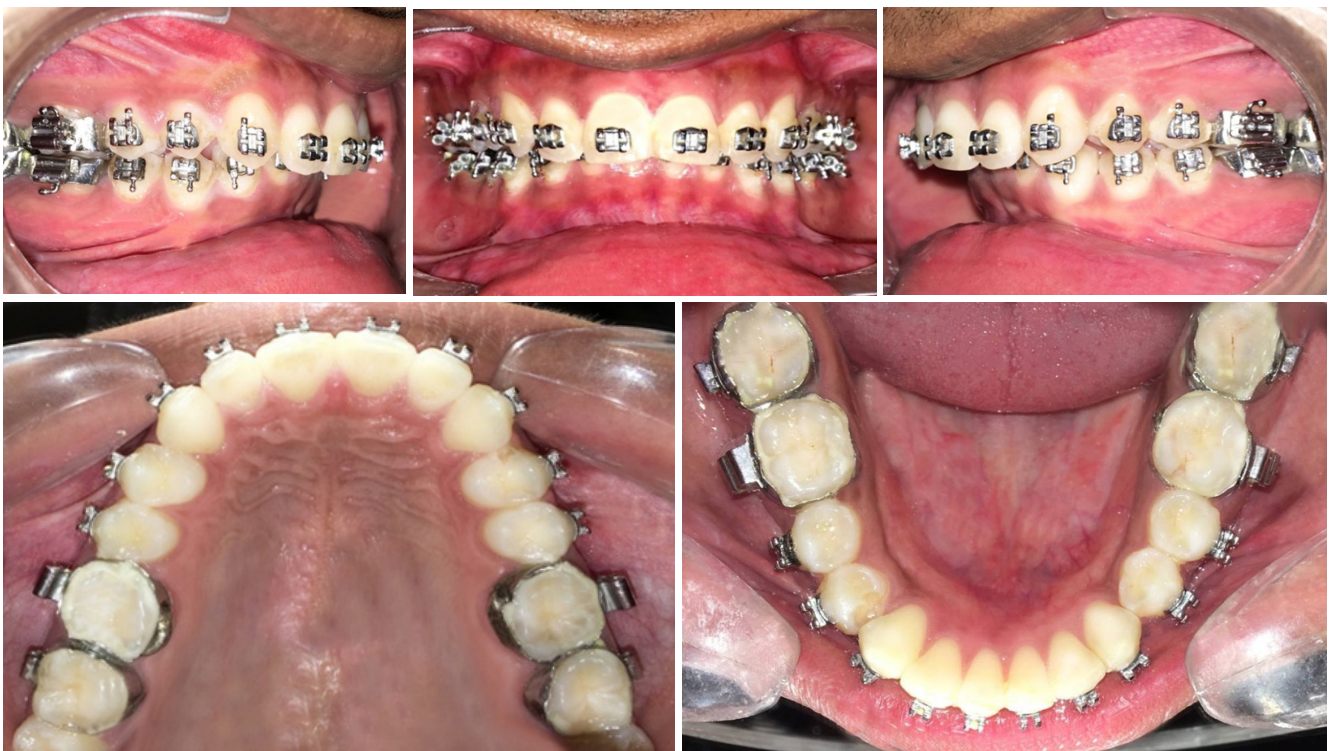

Figure 6: Mid-treatment intra-oral photographs



Figure 7: Facebow transfer

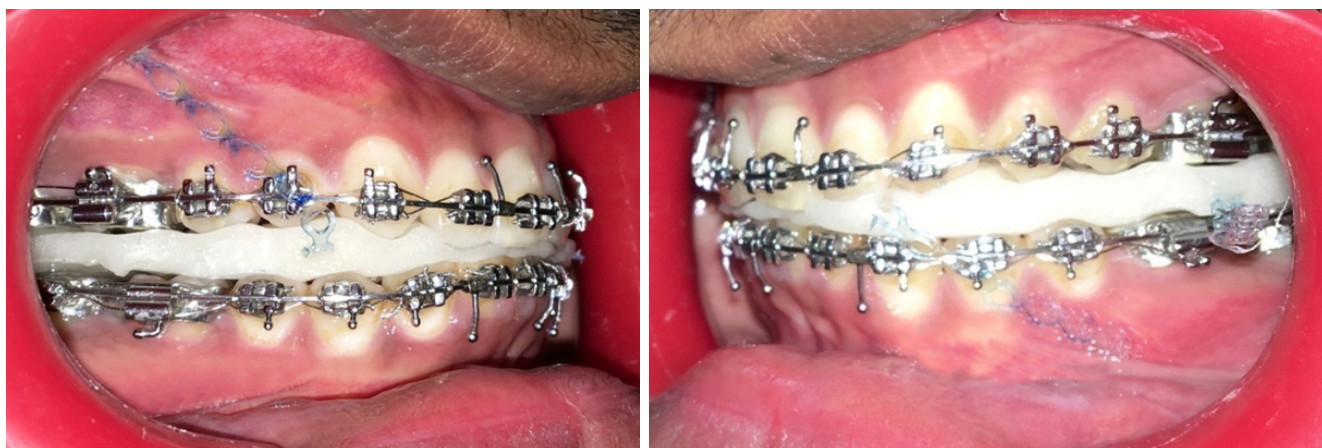

Figure 8. Surgical splint

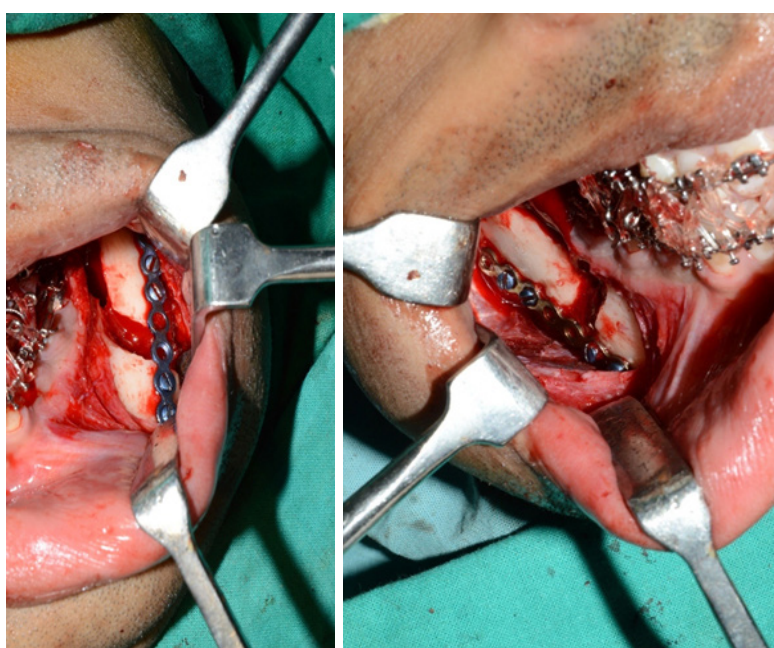


Figure 9: BSSO surgery in progress

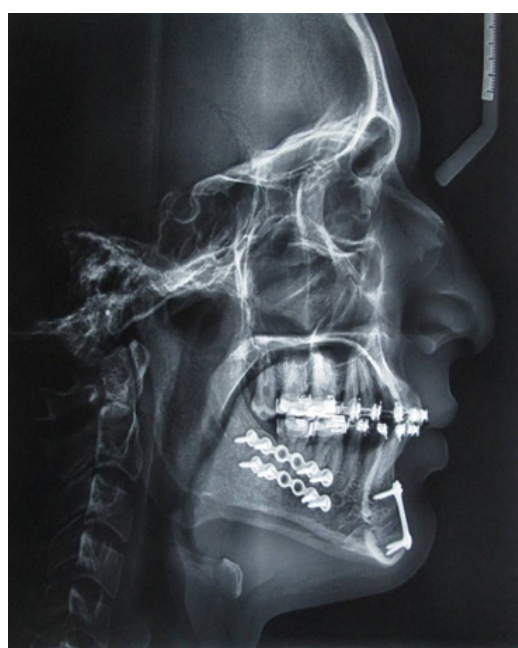

Figure 10: Post-surgical lateral cephalogram

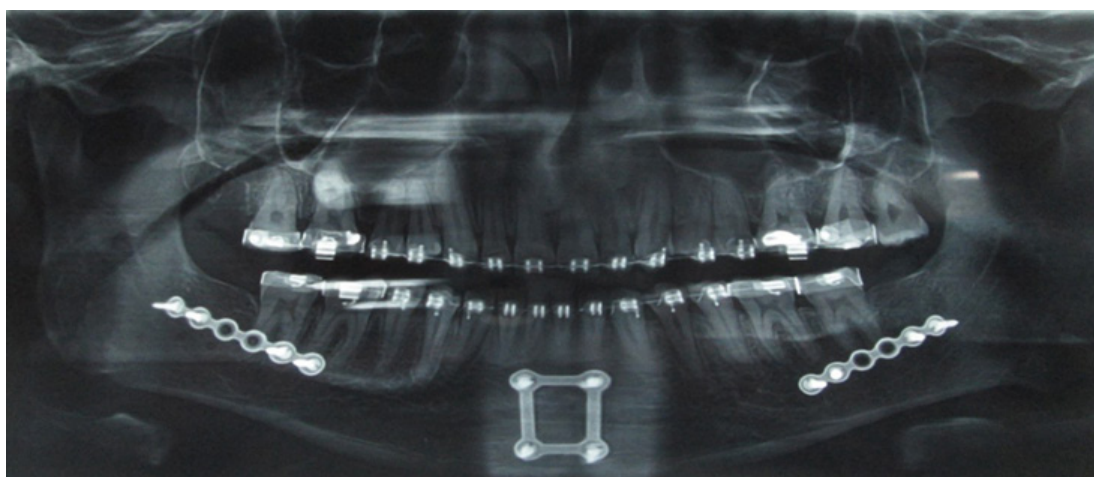


Figure 11: Post-surgical OPG



Figure 12: Post-treatment extra-oral photographs

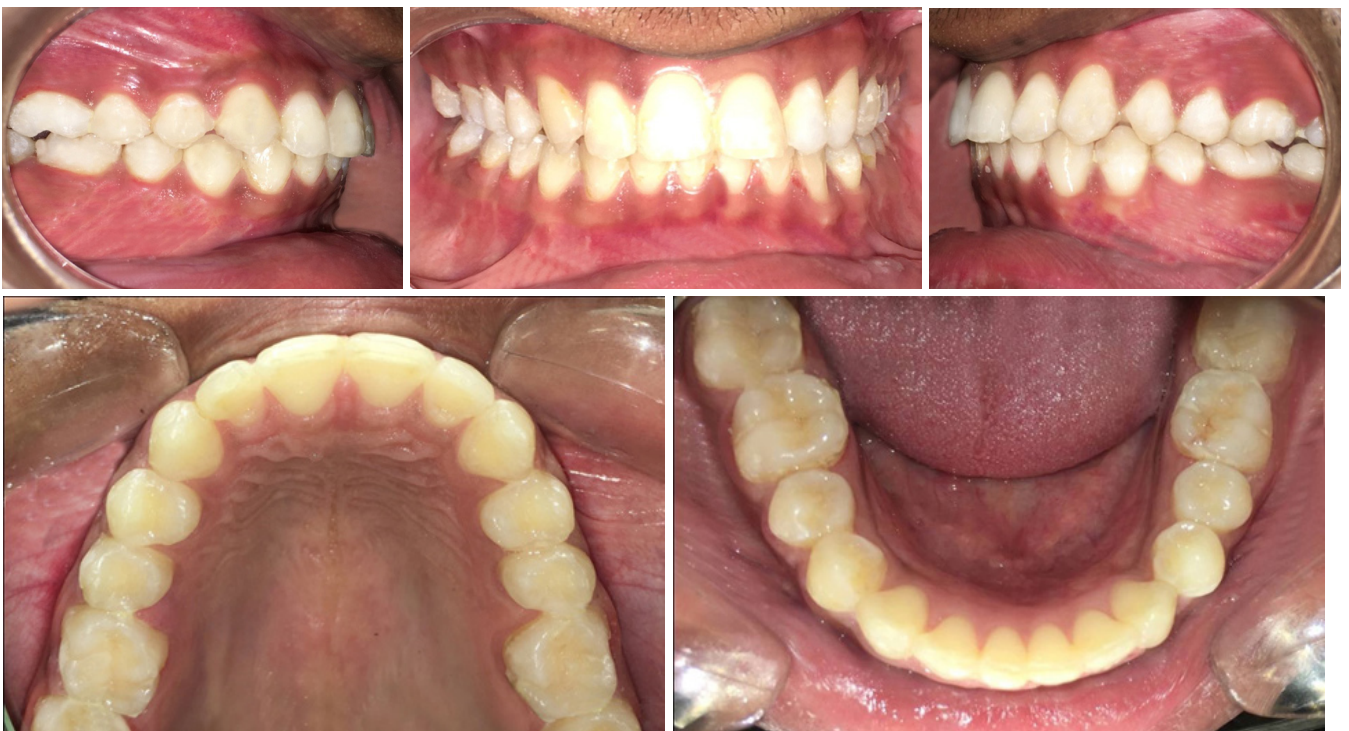

Figure 13: Post-treatment intra-oral photographs

Treatment objective

Main objectives of the treatment were to improve facial aesthetic, achieve straight facial profile, correct mandibular retrognathism, align maxillary incisors, achieve normal bilateral Class I molar and canine relationship, and correct overjet and overbite relation.

Treatment alternatives

There were two treatment alternatives. The first alternative was orthodontic treatment with dentoalveolar compensation using fixed orthodontic appliance. As the patient exhibited obtuse nasolabial angle, any further retrusion of maxillary arch would have been esthetically damaging to the patient's profile, hence no extraction

in the maxillary arch was thought about. The second alternative was ortho-surgical treatment approach with bilateral sagittal split osteotomy with mandibular advancement.

Both the treatment options were explained to the patient. As esthetics was the main concern, second treatment alternative was selected as this would preserve the integrity of the existing profile while reducing the severity of the mandibular retrognathism.

Treatment protocol

Maxillary arch was banded and bonded using 0.022" MBT prescription and .012 Niti wire was placed. After leveling and alignment of the upper arch, anterior

bite plane was given. Subsequently, mandibular arch banding and bonding was done. Patient's mid-treatment cephalometric readings were recorded; then the case was re-evaluated (Table 1,2). Mock surgery was planned, facebow transfer was done and surgical splint was fabricated. The orthognathic BSSO surgery was carried out with 6 mm mandibular advancement to correct antero-posterior skeletal discrepancy. Genioplasty was carried out for chin lengthening. Post-surgical occlusal settling was done. After ensuring the achievement of all intended goals; fixed orthodontic appliance was removed. Patient was then given Hawley's retainer.

Treatment results

Excellent facial and occlusal results were achieved. Significant improvement of the facial profile was appreciated. Intraorally, bilateral Class I molar and canine relation was achieved with normal overjet and overbite relation. Deep mentolabial sulcus was corrected and chin lengthening was achieved. Mandibular retrognathism was improved from ANB 6° to 3°. The patient was satisfied with the treatment results.

DISCUSSION

Class II malocclusion can be corrected depending on growth status and severity of the case. In adults, correction is done by orthodontic alone (camouflage) or orthodontic-orthognathic combination. Orthognathic surgery is indicated when dental discrepancy cannot be corrected by orthodontic treatment alone or when facial esthetic is compromised. Many adults cases exhibiting severe skeletal Class II Div 1 with mandibular retrognathism treated successfully with BSSO followed by mandibular advancement have been reported.^{7,8} However, case reports of surgical management of severe skeletal Class II Div 2 are rare.

In the present case, an adult of severe skeletal Class II Div 2 malocclusion was treated with orthodontic-orthognathic combination. The treatment was focused to relieve crowding, correct skeletal antero-posterior discrepancy and improve facial esthetics. Post-treatment result showed improved facial esthetics and dental occlusion. Convex facial profile and deep mentolabial sulcus were corrected and anterior vertical facial height was increased.



REFERENCES

1. Emmanuel OA. Prevalence of malocclusion among school children in Benin City, Nigeria. *J Med Biomed Res.* 2008; 7(1-2): 58-65.
2. Silva RG, Kang DS. Prevalence of malocclusion among Latino adolescents. *Am J Orthod Dentofacial Orthop.* 2001; 119(3):313-5.
3. Trehan M, Chung VK, Sharma S. Prevalence of malocclusion in Jaipur, India. *Int J ClinPédiate Dent.* 2009; 2(1):23-5.
4. Kaur H, Pavithra US, Abraham R. Prevalence of malocclusion among adolescents in South Indian. *J Int Soc Prev Comm Dent.* 2013; 3(2):97-102.
5. Wieslander L, Lagerstrom L. The effect of activator treatment on Class II malocclusions. *Am J Orthod.* 1979; 75:20-6.
6. McNamara JA Jr, Bookstein FL, Shaugnessy TG. Skeletal and dental changes following functional regulator therapy on Class II patients. *Am J Orthod.* 1985; 88:242-51.
7. Hanumanth S, Krishnanayak US. Surgical orthodontic treatment of skeletal Class II malocclusion. *J Scientific Dent.* 2013; 3(1):35-44.
8. Mohite A, Kshirsagar R, Patankar A, Pawar S, Singh V. Bilateral sagittal split osteotomy and genioplasty: A case report. *IOSR J Dent Med Sci.* 2017; 16(1):119-22.