

# Multidisciplinary Rehabilitation of Ectodermal Dysplasia: A Case Report

Dr Alka Gupta,<sup>1</sup> Dr Sunita Karki,<sup>2</sup> Dr Deepak Thapa,<sup>3</sup> Dr Rabindra Man Shrestha<sup>4</sup>  
<sup>1</sup>PG Resident, <sup>4</sup>Professor, Dept of Orthodontics, <sup>2</sup>PG Resident, <sup>3</sup>Faculty, Dept of Prosthodontics  
Kantipur Dental College, Kathmandu, Nepal

Correspondence: Dr Alka Gupta; Email: [alkagupta985@gmail.com](mailto:alkagupta985@gmail.com)

## ABSTRACT

This case report describes a joint multidisciplinary approach of restoring function and esthetics in an 18-year-old female with ectodermal dysplasia. Ectodermal dysplasia is both physically and emotionally devastating to patients with dental manifestations. It is important that they are treated at an early age to help their social interaction. With proper dental intervention, the quality of life can be improved for patients with ectodermal dysplasia.

**Keywords:** ectodermal dysplasia, hypodontia, orthodontic treatment, partial denture, fixed prosthesis

## INTRODUCTION

Ectodermal dysplasias (ED) are a heterogeneous group of disorders characterized by developmental dystrophies of ectodermal structures.<sup>1</sup> Hypohidrotic ectodermal dysplasia is the most common type and is usually inherited as an X-linked recessive trait. It is characterized by the triad of signs which comprises of sparse hair (atrachosis or hypotrichosis), abnormal or missing teeth (anodontia or hypodontia), and inability to sweat due to lack of sweat glands (anhidrosis or hypohidrosis).

The incidence of ED is estimated at 1 in 100,000 births.<sup>2</sup> The earliest recorded case of ectodermal dysplasia was described in 1792.<sup>3</sup> There are more than 100 different ED syndromes,<sup>4</sup> clinical manifestations depend on the specific syndrome afflicting an individual. The most frequently reported ED syndrome is X-linked hypohidrotic dysplasia,<sup>5</sup> also known as Christ-Siemens-Touraine syndrome,<sup>6</sup> which affects one to seven individuals per 10,000 live births.<sup>6</sup>

Ectodermal dysplasia syndromes have been described as a group of disorders of morphogenesis displaying two or more of the following signs and symptoms: (1) trichodysplasia, (2) dental anomalies, (3) onychodysplasia, and (4) dyshidrosis. These malformations result from developmental defects in tissues in which progenitor cells were originally derived from the ectoderm of the embryo. Congenital malformation of teeth, hair, nails, or sweat glands may occur either as single isolated malformations or as a part of ectodermal dysplasia syndrome.<sup>7</sup> Freire-Maia and Pinheiro classified ectodermal dysplasias into 11 possible groups, based on all possible combinations of

two or more defects. Mutations in only four genes (*EDA1*, *EDAR*, *EDARADD*, and *WNT10A*) are responsible for most of the cases of ED.

The most frequently reported manifestation of ED is hypohidrotic dysplasia (HED), also termed Christ-Siemens-Touraine syndrome, and anhydrotic dysplasia. The ectoderm, one of the three germ layers present in the developing embryo, gives rise to the central nervous system, peripheral nervous system, sweat glands, hair, nails, and tooth enamel. As a result, HED patients exhibit the following clinical signs: hypotrichosis, hypohidrosis, and cranial abnormalities. Patients often exhibit a smaller face because of frontal bossing, depressed nasal bridge, absence of sweat glands resulting in smooth dry skin, and hyperkeratosis of hands and feet. Oral traits may express as anodontia, hypodontia, and conical teeth. Anodontia may manifest due to a lack of alveolar ridge development.

## CASE REPORT

An 18-year-old female reported to Dental OPD, Kantipur Dental College Teaching Hospital with a chief complaint of partially missing teeth in both upper and lower arches. The patient gave a history of missing teeth since birth and a history of intolerance to heat. No other associated medical or systemic conditions were present. Diagnostic records included OPG, lateral cephalogram, photographs and study model.

On extra-oral examination, patient gave a characteristic appearance of sparse hair on scalp and eyebrow (fine and dry), frontal bossing, saddle nose, sunken cheeks, macroglossia, pigmentation around eyes and thick

everted lips (Figure 1,2). Intra-orally, patient presented with oligodontia with the presence of permanent first and second molars. On anterior region, conical teeth were present which were widely spaced (Figure 3). Tooth present were 17,16,13,12,11,21,23,26,27,36,37,46,47. The enamel was normal in color and hardness. In addition to the cone-shaped anterior crowns; the crown form of maxillary first molar was tricuspid heart shaped with conical roots. Patient also suffered with the intolerance to heat suggesting sparse eccrine sweat glands. Mother and father were both clinically normal with no presenting symptoms. There was no history of consanguineous marriage of the parents. Patient's younger male sibling aged 16 years also exhibited similar intra-oral features in milder form. Patient's grandmother also suffered from conical shaped teeth. On further enquiry, no other family members exhibited such symptoms.

Multiple impacted tooth in the lower anterior region were extracted in the Department of Oral Surgery prior to orthodontic consultation. The patient exhibited mild localized gingivitis and was referred for a comprehensive periodontal evaluation and oral prophylaxis.

Orthodontic treatment was performed on the maxillary arch with fixed orthodontic appliance of 0.018" slot.

Leveling and alignment was performed with gradual 0.012", 0.014", 0.016" Niti wires followed by 0.016", 0.018" round stainless steel wires; then 0.016x0.022" rectangular stainless wire to stabilize the arch. Meanwhile, closing and maintenance of space was done using elastomeric chains; proper spaces were maintained to allow fixed partial dentures.

After completing the orthodontic phase, patient was referred to the Dept. of Prosthodontics for prosthetic rehabilitation. On upper arch, teeth were prepared for porcelain fused to metal (PFM) bridge then cemented with fixed partial denture with A2 Vita shade (Figure 3, 4). PFM bridge was given in three segments i.e. from canine to molar on either sides and lateral to lateral bridge in the anterior segment. Lower arch was initially planned for implant placement; however it could not be considered due to the thin cortical plate. Lower arch was rehabilitated with cast partial denture utilizing semi-precision attachments (vertex) in the missing area along with metal crowns in relation to 36, 37 and 46, 47 (Figure 5).

OPG revealed numerous conical teeth in upper anterior and impacted teeth in lower anterior regions (Figure 6). Based on the clinical and radiographic findings, a case of Hypohydrotic Ectodermal Dysplasia was diagnosed.

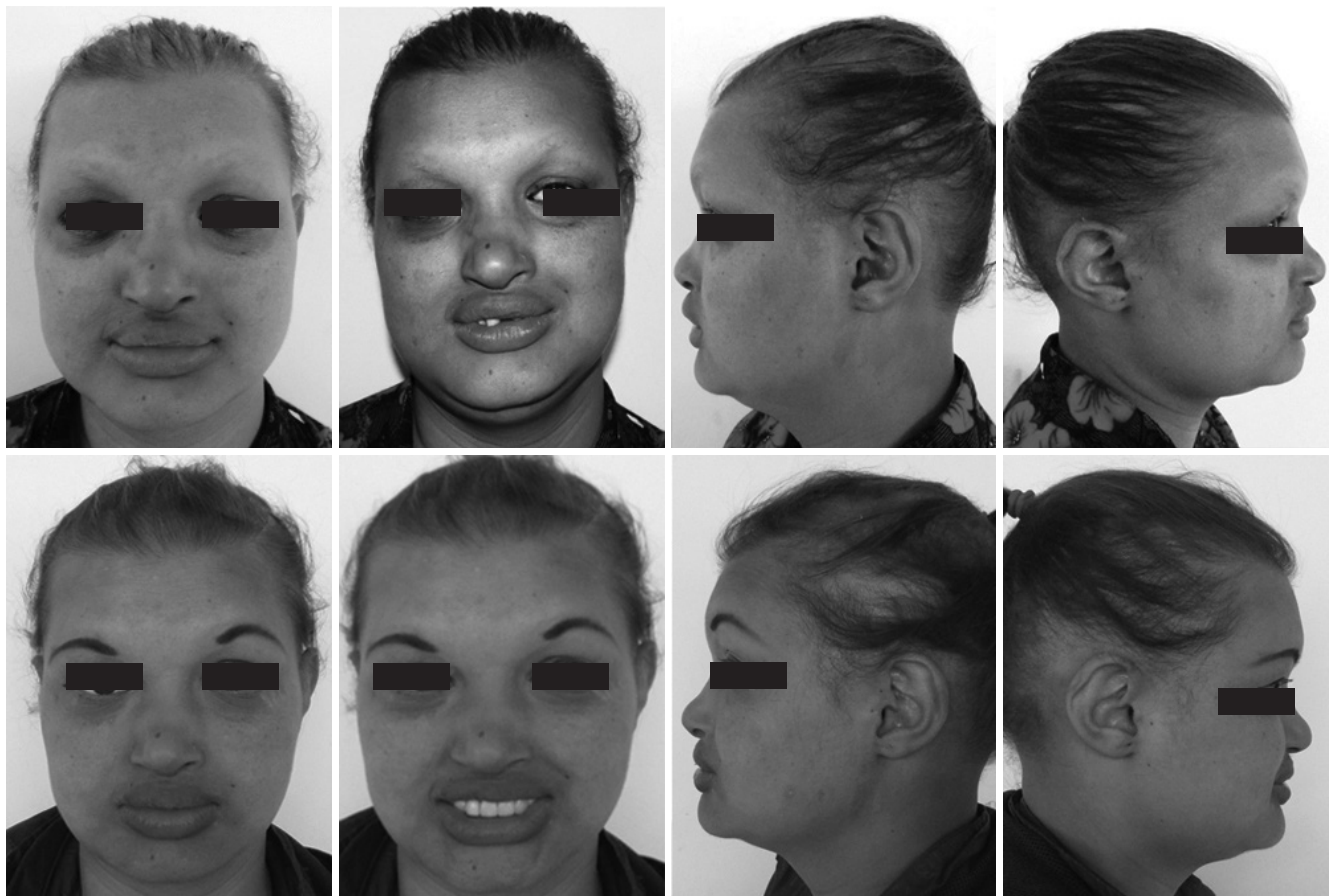

Figure 1: Pre and post-treatment extra-oral photographs

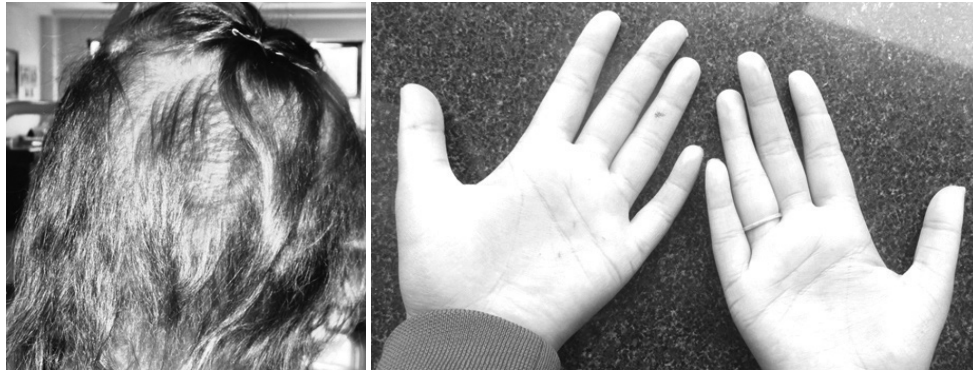

Figure 2: Photographs showing scalp and palm

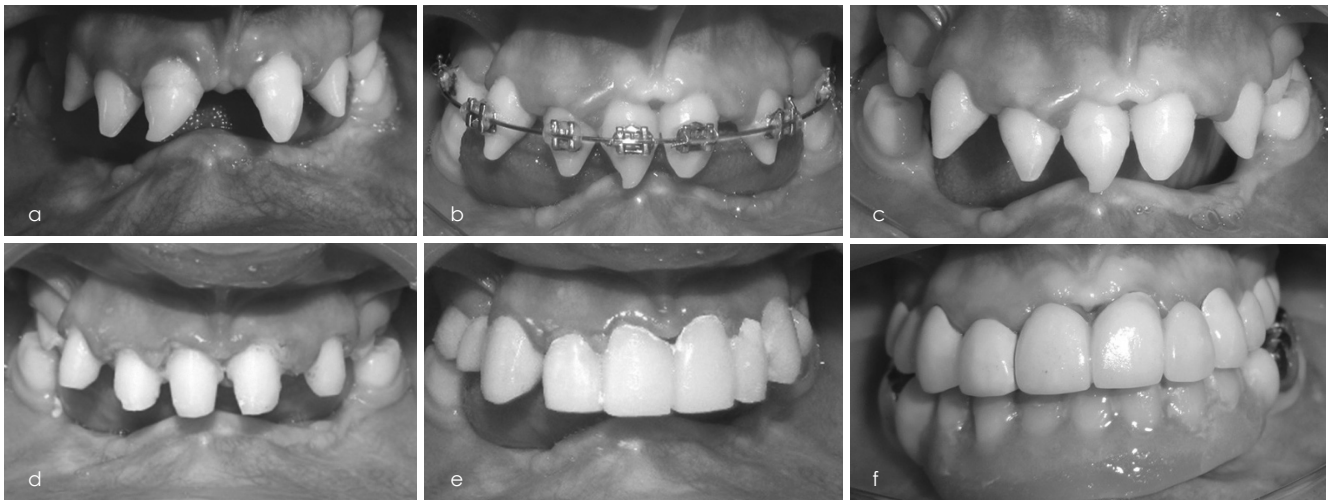


Figure 3: a) Pre-treatment, b) Intra-orthodontic treatment, c) After Debonding, d) Tooth Preparation, e) Temporization, f) Complete Rehabilitation

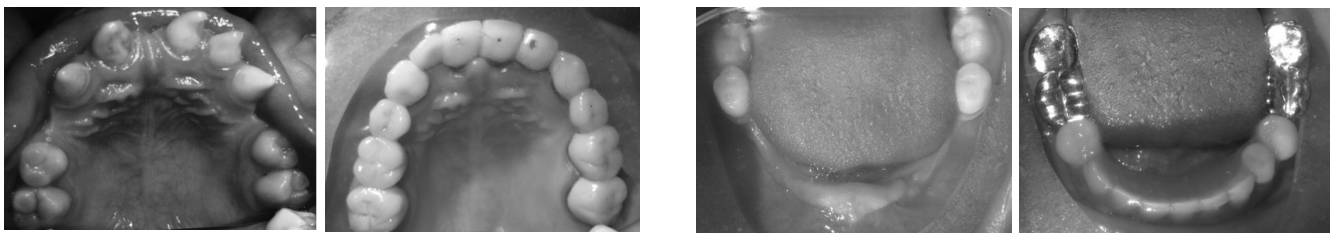


Figure 4: Pre and Post-treatment occlusal photographs of maxillary and mandibular arches

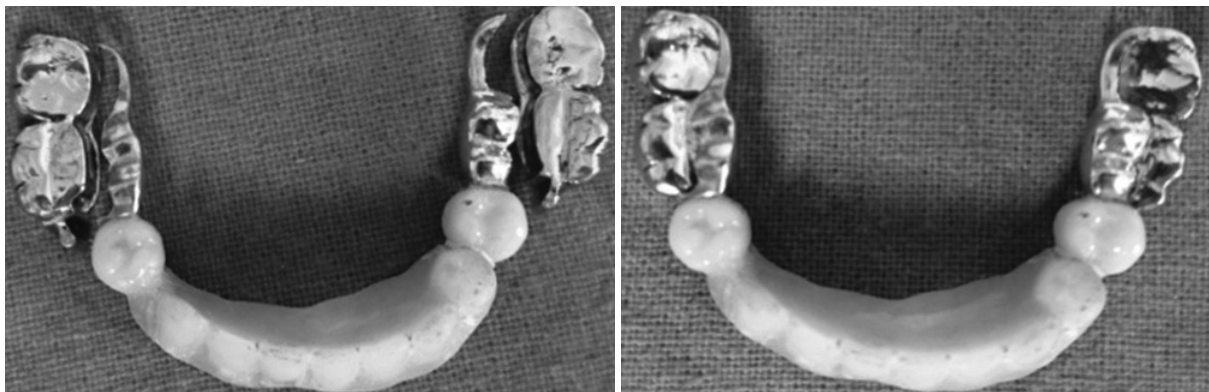

Figure 5: Lower denture with semi-precision attachment

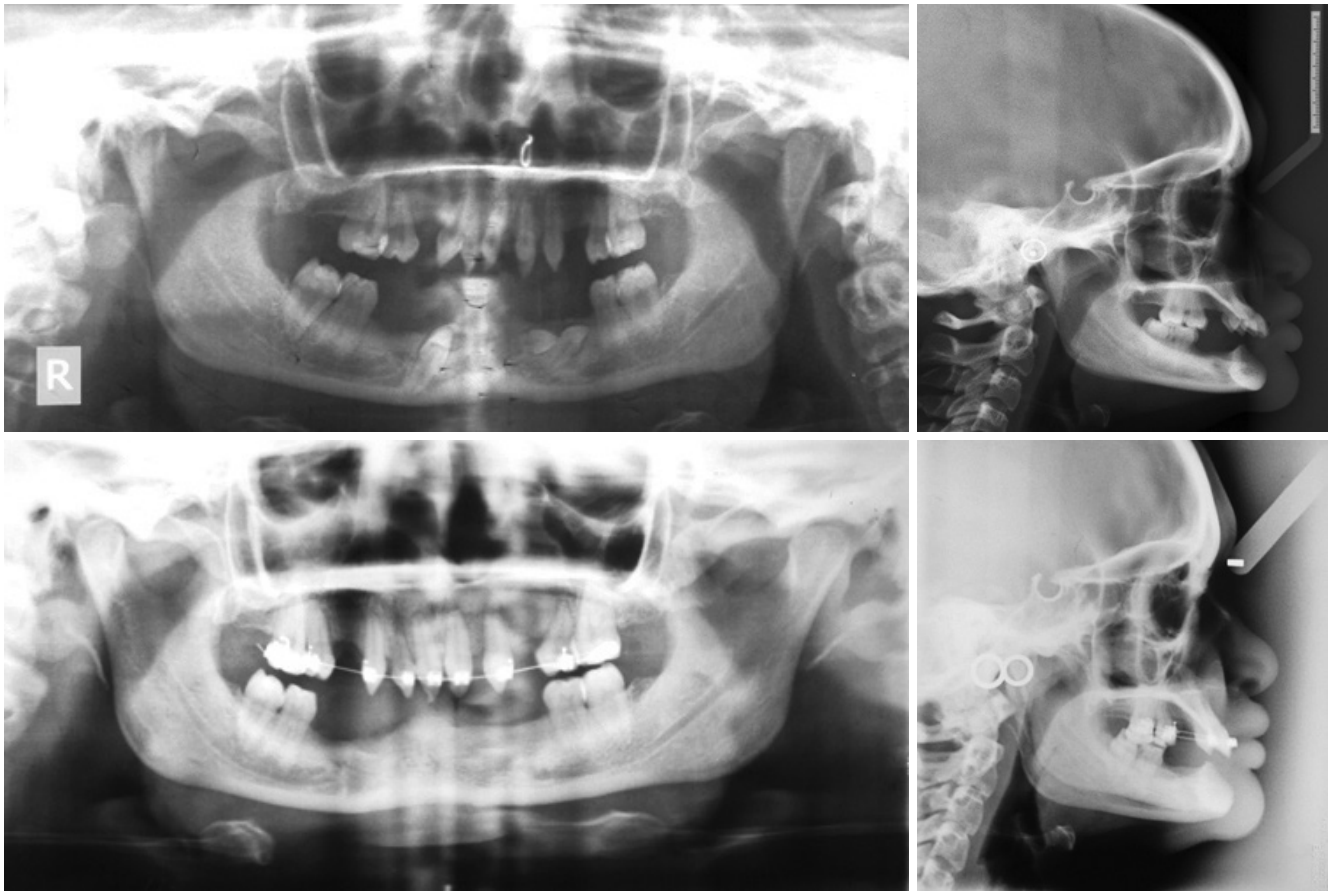


Figure 6: Pre and end-treatment radiographs

## DISCUSSION

The differential diagnosis of hypohidrotic ectodermal dysplasia includes Rothmund-Thomson syndrome which exhibits features of sun-sensitive rash with prominent poikiloderma and telangiectasias, saddle nose, sparse hair growth, juvenile cataracts and hypodontia. However none of the cases of ectodermal dysplasias of the anhidrotic or hidrotic type reported in literature exhibited cataracts in infancy or in later life. Other conditions to be considered while diagnosing hypohidrotic ectodermal dysplasia include Alopecia Areata, Aplasia Cutis Congenita, Focal Dermal Hypoplasia syndrome, Incontinentia

Pigmenti, Naegelle Franceschetti Jadassohn syndrome, Pachyonychia Congenita and Werner's syndrome.

The most frequent treatment for such group of patient is orthodontic alignment and rehabilitation followed by fixed or removable prosthodontics. In such patients; diagnosis should be made at earliest followed by thorough history and clinical examination of the patient and also of the family members. Multidisciplinary joint approach involving oral medicine, oral surgery, periodontics, orthodontics and prosthodontics is a need for the patient being treated for ectodermal dysplasia.

OJN

## REFERENCES

1. Rajendran R. Shafer's Textbook of Oral Pathology. 5th ed. 1983. 797-98.
2. Stevenson A, Kerr C. On the distribution of the frequencies of mutation to genes determining harmful traits in man. *Mutat Res.* 1967;4:339-52.
3. Abadi B HC. Clinical treatment of ectodermal dysplasia: a case report. *Quintessence Int.* 2001;32:743-5.
4. Freire-Maia N. Ectodermal dysplasias—a clinical and genetic study. New York Alan R Liss Inc. 1994.
5. Levin LS. Dental and oral abnormalities syndromes. *Birth Defects.* 1988;24:205-27.
6. Buyse ML. In: Birth defects encyclopedia Cambridge: Blackwell Scientific Publications. 1990;596-605.
7. Levin LS. Dental and oral abnormalities in selected ectodermal dysplasia syndromes. *Birth Defects.* 1988;24:205-27.