

Biomex Quad Helix

Dr Shirish M. Bapat,¹ Dr Preeti Bhardwaj,² Dr Atul Singh,³ Dr Nitesh Parasher, Dr Amit Goel⁴

¹Professor, ²Reader, ³Lecturer, ⁴PG Resident
Dept of Orthodontics, K.D. Dental College, Mathura, India

Correspondence: Dr Shirish M. Bapat; email: shirishmbapat@gmail.com

ABSTRACT

Introduction: Anterior deep bite with narrow maxillary arch is a most common clinical situation orthodontists have to deal with in Class I as well as Class II malocclusions.

Objective: To present a modification of the quad helix appliance which incorporates acrylic anterior bite plane for simultaneous bite opening with maxillary expansion (Biomex Quad helix).

Appliance design: The appliance is made of 0.036 inch stainless steel wire. The anterior bridge of the quad helix is modified by extending it anteriorly. The wire is soldered to the stainless steel bands on the maxillary first permanent molars. Acrylic anterior bite plane is added to this anterior extension keeping the anterior helices exposed. It combines advantages of a quad helix with that of anterior bite plane. Hence it can be useful for simultaneous bite opening with maxillary expansion, deprogramming, and relieving TMJ symptoms by unlocking the occlusion.

Conclusion: Biomex Quad Helix is a versatile appliance which is simple in design, easy to fabricate, comfortable for the patient, and economical for the operator and the patient.

Key words: anterior bite plane, bite opening, expansion, Quad Helix

INTRODUCTION

Anterior deep bite with narrow maxillary arch is a common clinical situation orthodontists have to deal with Class I as well as Class II malocclusions. These problems can be treated by using various expansion and bite opening devices. Quad helix and its modifications^{1,2,3,4,5,6} and anterior bite plane^{7,8} are most commonly used appliances in these situations.

Aim of this article is to present a modification of quad helix appliance which incorporates acrylic anterior bite plane for simultaneous bite opening with maxillary expansion (Biomex Quad helix).

APPLIANCE DESIGN

The appliance is made of 0.036 inch stainless steel wire soldered to the stainless steel bands on permanent first molars. The anterior bridge of the quad helix is modified by extending it anteriorly. Two symmetric v-bends are placed in the anterior extension wire in the vertical plane (Figure 1, 2) keeping at least 2-3 mm clearance from the anterior palate and alveolar process. These two vertical v-bends along with the horizontal bends at both lateral ends of the anterior extension wire provide sufficient retention, stability and resistance against rotation for the acrylic anterior bite plane. After the wire is soldered to the stainless steel bands; it is placed on the

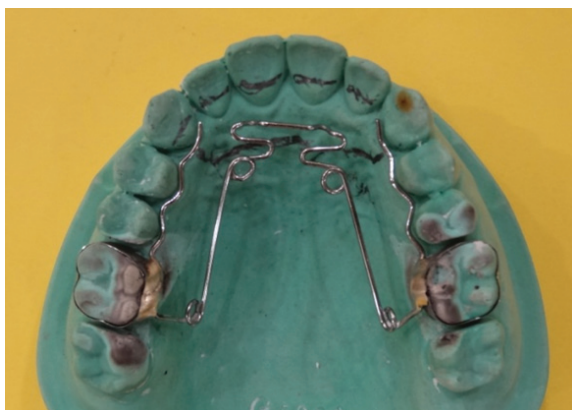

Figure 1: Biomex Quad Helix wire showing modified anterior bridge




Figure 2: Anterior view of Biomex Quad Helix wire showing two symmetric vertical v-bends



Figure 3: Biomex Quad Helix wire placed on the working cast and outline of the anterior bite plane is drawn with lead pencil



Figure 4: Biomex Quad Helix (rear view)

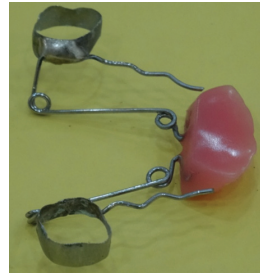

Figure 5: Biomex Quad Helix (lateral view)

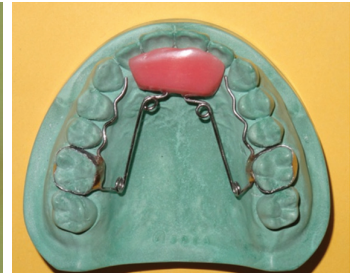

Figure 6: Biomex Quad Helix on the maxillary cast

working cast and outline of the anterior bite plane is drawn on the cast with a lead pencil (Figure 3). Acrylic anterior bite plane is added to this anterior extension keeping the anterior helices exposed (Figure 4, 5, 6).

Biomex Quad Helix combines advantages of a quad helix with that of the anterior bite plane. Hence it is useful for simultaneous bite opening with maxillary expansion, deprogramming, and relieving TMJ symptoms by unlocking the occlusion.

DISCUSSION

Quad helix appliance was introduced by Ricketts¹ in 1978. This versatile appliance has been one of the most popular fixed appliances used for expansion of the maxillary arch. It can cause orthopedic palatal expansion in the mixed dentition stage,² and dental expansion in the adults.^{1,2} It combines capability of expanding in the anterior or posterior region separately or simultaneously. As the forces exerted by the quad helix are in the physiological limits, it can be used effectively in the cleft palate patients, or adult patients, particularly those with periodontal involvement.¹

Having been used extensively all over the world, this appliance has been modified to suit individual requirements in different patients. Such modifications include incorporation of the tongue spikes,^{1,3} extension of anterior arm on to the incisors,^{1,4} Hexahelix⁵ etc. Some patients need anterior bite opening along with expansion of the maxillary arch. Incorporating anterior bite plane to the quad helix is useful in such situations. Pato *et al*⁶ used Planas Equiplan-Quadhelix combination for above purpose.

The present article presents a modification of the quad helix appliance which incorporates acrylic anterior bite plane for bite opening with maxillary expansion (Biomex Quad helix). It combines advantages of a quad helix^{1,2,3,4,5} with that of anterior bite plane.^{6,7,8} Hence it can be useful for simultaneous bite opening with maxillary expansion, deprogramming, and relieving TMJ symptoms by unlocking the occlusion.^{6,7,8}

CONCLUSION

Biomex Quad Helix is a versatile appliance which is simple in design, easy to fabricate, comfortable for the patient, and economical for the operator and the patient.

OJN

REFERENCES

1. Ricketts RM, Bench RW, Gugino CF, Hilgers JJ, Schulhof RJ. J Clin Orthod 1978;12:279-298.
2. Bell RA, LeCompte EJ. The effects of maxillary expansion using a quad-helix appliance during the deciduous and mixed dentitions. Am J Orthod Dentofacial Orthop 1981;79:152-161.
3. Cozza P, Giancotti A, Rosignoli L. Use of a modified quadhelix in early interceptive treatment. J Clin Orthod 2000;34:473-476.
4. Nute SJ, Dibiasi DD. Modified quadhelix for Class III treatment. J Clin Orthod 1998;35:626-629.
5. Yaseen SM, Acharya R. Hexa Helix: modified quad helix appliance to correct anterior and posterior crossbites in mixed dentition. Case Rep Dent 2012; 2012:860385. Doi: 10.1155/2012/860385. Epub 2012 Oct 16.
6. Pato JMS, De Saboia SVM, Pato BJM, Pato JMM. The Equiplan- Quadhelix combination in deep bite cases. J Clin Orthod 2002;36:434-436.
7. Madsen R. Bonded acrylic lingual bite planes. J Clin Orthod 1998;35:311-317.
8. Carl PJ, Foley TF. The use of a deprogramming appliance to obtain centric relation records. Angle Orthod 1999;69:117-123.