

Case Report

Footprints of Surprise: A 4-Year Odyssey of an Intruder in a Teenage Foot- A Case Report

Amir Ratna Shakya¹, Nirab Kayastha¹, Ritesh Sinha¹, Mohit Thapa Magar¹, Alok Singh¹

¹Nepalese Army Institute of Health Sciences, Kathmandu, Nepal

ABSTRACT

Glass foreign body injuries, especially in the foot, are common occurrences in our part of the world owing to barefoot walking practice. Despite exploration, there are chances of retention of foreign bodies in the wound which can later result in complications such as chronic pain, granuloma formation, infection, and secondary migration features. Here we present a case of a teenage girl with a retained glass foreign body in her foot for a duration of 4 years which had been missed in the first visit to a health facility.

Keywords: Foreign Body; Foot; Glass; Removal.

INTRODUCTION

Foreign body-related injuries as a result of penetration injuries or impalement are common presentations to the emergency department in both developing and developed countries.¹ Glass-associated injuries account for 13% of these injuries.² The initial management involves the exploration and removal of these foreign bodies.³ However, in some instances detection of these materials can be difficult and are retained inside.⁴ The human body's remarkable defense mechanism often reacts by encapsulating these foreign bodies and isolating them in the forms of granulomas. They may be symptom-free initially following primary wound care only to present as a problem later. These retained foreign bodies in later stages may present with pain, infection or features of secondary migration.^{3, 5-7} Here, we present a case of 16 years old girl who had foot pain of recent onset hindering her daily activities with the odyssey of intruder in her foot.

was then sutured. The post-suturing wound healed and she was symptom-free with resumption of normal activities. She denies any radiological investigation done during that time. On examination, there was firm, nodular swelling of around 1x1.5 cm on the plantar aspect of the 3rd and 4th metatarsal neck region of the left foot. There was no local rise in temperature or discharge. However, tenderness was present.

X-ray showed multiple linear radio-opacities in plantar soft tissues of the left foot underlying the 2nd, 3rd, and 4th metatarsal with associated thickening of surrounding soft tissues. USG revealed multiple hyperechoic areas in a plantar subcutaneous plane with posterior acoustic shadowing.

CASE REPORT

A 16-year girl presented to our outpatient department with complaints of pain and swelling over the lateral aspect of the plantar surface of her left foot for a duration of 4 months which was gradually progressive and increasing in severity causing hindrance to her daily activities. At the time of the presentation, she was reluctant to bear weight on the same foot. She recalls having a glass cut injury over the same foot 4 years back for which she was taken to a local hospital where pieces of glass were removed from the wound which

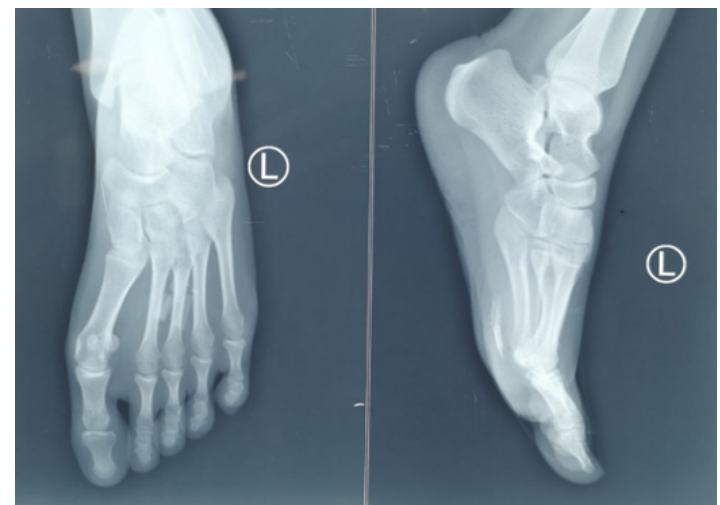

Fig. 1: X-ray Left foot showing radiopaque foreign bodies in plantar aspect

Correspondence:

Dr Alok Singh
Nepalese Army Institute of Health Sciences, Shree Birendra Hospital,
Chhauni, Kathmandu,
Tel: +977-9851281862, Email: aloksingh15364@gmail.com

She underwent direct exploration of foreign bodies under spinal anesthesia. Localization of glass pieces was done

using a probing technique with a syringe needle and fluoroscopy. Multiple pieces of glass were present along the longitudinal fibers of the plantar fascia. These fibers were dissected along their alignment to remove six pieces of glass, the largest one measuring 18x05 mm. Fluoroscopy was done to ensure complete removal.

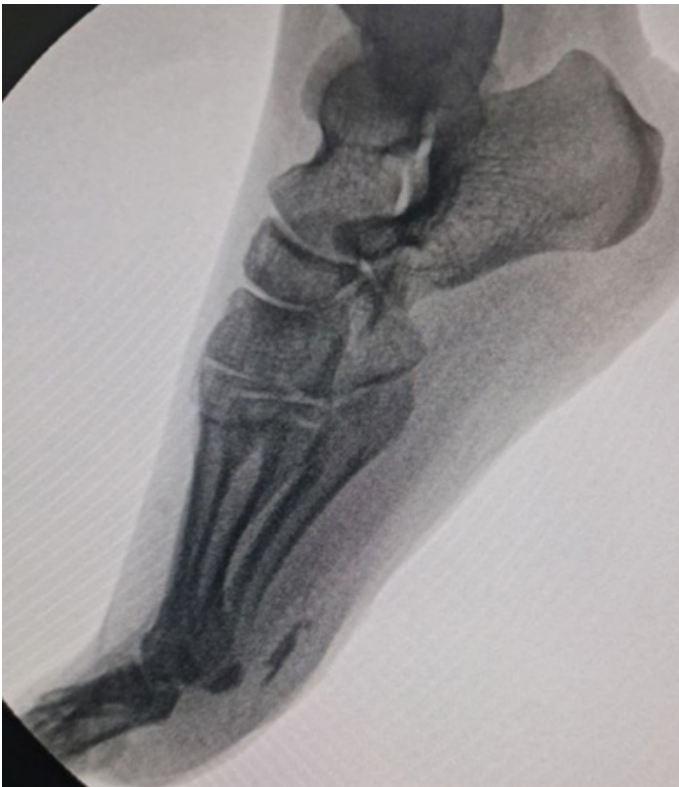

Fig. 2: Intra operative fluoroscopy image

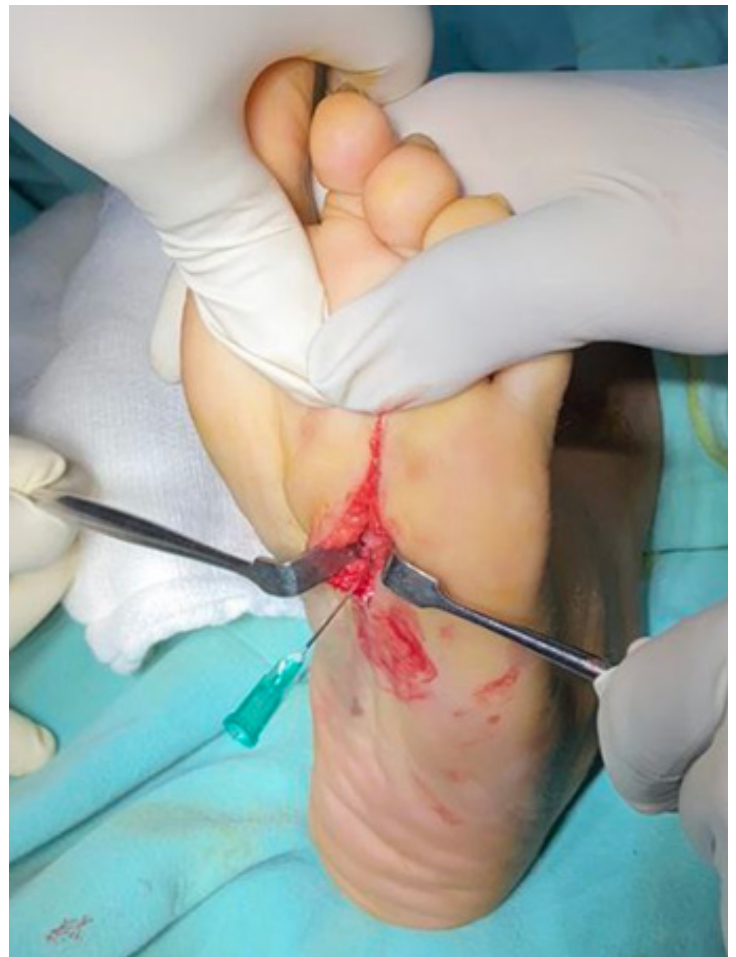

Fig. 4: Glass piece localization via probing technique with syringe needle

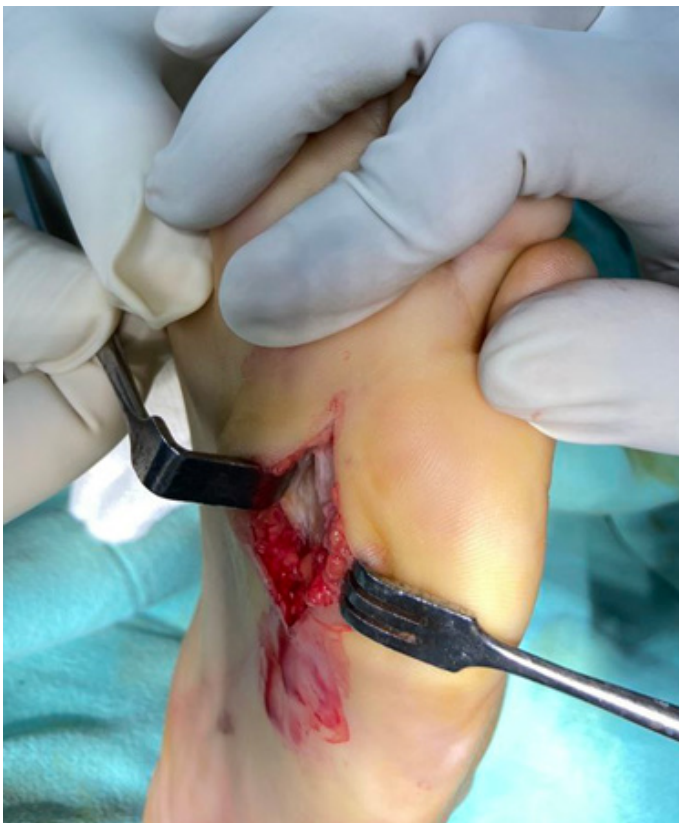

Fig. 3: Glass pieces embedded in plantar fascia

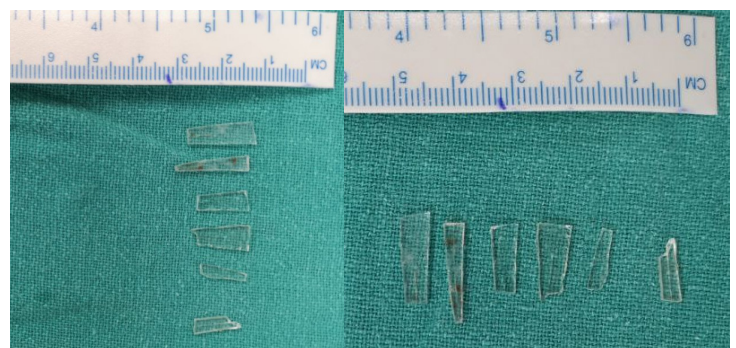


Fig. 5: Glass pieces retrieved

DISCUSSION

Foreign bodies can frequently be impacted in the foot and remain in a dormant state for a long time. The diagnosis and management of these retained foreign bodies are a real challenge for surgeons and emergency physicians. The absence of pain can make the diagnosis even more difficult.^{7, 8} Stepped on glass as a mechanism is a common mode of injury to the foot in our part of the world where barefoot walking practice is common. Plantar puncture wounds when compared to lacerations are more likely to have retained glasses. The

other mechanism of injury more likely associated with retained glass foreign bodies is motor vehicle accidents.⁴

The initial management involves proper exploration of the wound to retrieve any foreign bodies. Though the chances of the presence of retained foreign body is lessened, a negative wound exploration however does not rule out the presence of foreign body. The frequency of foreign bodies missed by exploration ranged from 15 % to 31% as detected by radiography.⁴ Sometimes the detailed history of trauma is not reliable and foreign bodies cannot be detected at the first setting. Clinical examination too is not sufficient to exclude the presence of glass in the wound.^{4, 6} Hence, difficult cases may require radiographic or sonographic evaluation for diagnosis and removal of the glass foreign bodies.^{4, 6, 7}

Retained foreign body especially glass can give a displeasing sensation or a feeling that there is something inside.^{4, 6, 7} A positive perception has a low predictive value of around 31%. Though the negative predictive value was as high as 89%, the chances of missing glass foreign bodies based on patient perception alone were around 57%.^{4, 6} A positive patient perception also was correlated with a positive radiograph when the wound exploration was negative suggesting an advantage of the investigation in confirmation of presence or absence of glass where wound exploration is difficult.⁴ However, there are no clinical predictors for wounds defining the risks for glass retention that can be used as an indication for radiographic studies. The X-ray was reliable in detecting glass foreign bodies of size 2 mm and more. In the study by Courter, 2 mm pieces of glass were visualized 99% of the time with two view radiographs, 1mm pieces 83% of the time, and 0.5mm pieces 61% of the time.⁹

Ultrasounds, despite being operator dependent have become an ideal investigation to identify and localize the radiopaque and non-radiopaque foreign bodies. Other modes of investigation include computed tomography and magnetic resonance imaging when the foreign bodies are deeply positioned in the tissue or close to an important anatomic structure.⁷

Retained foreign bodies can lead to several complications increasing the morbidity and cost of treatment such as infections, non-healing wounds, granuloma formation, chronic pain, and injuries secondary to migration. The incidence of infection in retained glass is theoretically small since glass is considered to be relatively inert.^{1, 3, 4, 6-8}

The decision to remove a foreign body is based on the nature and size of the foreign body, the anatomical location, wound contamination, presence or absence of symptoms, anticipation of symptoms that will be produced, and potential loss of function. Similarly, any foreign bodies located adjacent to tendons, nerves, or vessels should be removed owing to the potential for mechanical injury of these structures during motion. Similarly small, asymptomatic, inert foreign bodies that are difficult to localize and those that do not interfere with function can be left alone.⁶

CONCLUSION

Retained foreign bodies are a common occurrence. Clinicians should always consider the potential of the presence of such

foreign bodies in cut or penetration injuries. Radiological investigations can aid in the diagnosis and localization of such foreign bodies

CONFLICT OF INTEREST

None

ACKNOWLEDGEMENT

Dr. Bishnu Babu Thapa, Dr. Sushil Rana Magar, Nepalese Army Institute of Health Sciences

CONSENT

Written informed Consent was taken from the patient

REFERENCES

- Joshi R, Dwivedi R. Presentation and Management of Soft Tissue Foreign Bodies in a Teaching Hospital of Western Nepal. *Journal of Lumbini Medical College*. 2016;3:50. <https://doi.org/10.22502/jlmc.v3i2.73>
- Hollander JE, Singer AJ, Valentine S, Henry MC. Wound registry: development and validation. *Ann Emerg Med*. 1995;25(5):675-85. [https://doi.org/10.1016/s0196-0644\(95\)70183-3](https://doi.org/10.1016/s0196-0644(95)70183-3)
- Wani R, Rashid A, Malik M. Diagnosis and management of neglected foreign body foot in children. *International Surgery Journal*. 2021;8. <https://doi.org/10.18203/2349-2902.ISJ20211947>
- Steele MT, Tran LV, Watson WA, Muelleman RL. Retained glass foreign bodies in wounds: predictive value of wound characteristics, patient perception, and wound exploration. *Am J Emerg Med*. 1998;16(7):627-30. [https://doi.org/10.1016/s0735-6757\(98\)90161-9](https://doi.org/10.1016/s0735-6757(98)90161-9)
- Montano JB, Steele MT, Watson WA. Foreign body retention in glass-caused wounds. *Ann Emerg Med*. 1992;21(11):1360-3. [https://doi.org/10.1016/s0196-0644\(05\)81902-x](https://doi.org/10.1016/s0196-0644(05)81902-x)
- Tuncer S, Ozcelik IB, Mersa B, Kabakas F, Ozkan T. Evaluation of patients undergoing removal of glass fragments from injured hands: a retrospective study. *Ann Plast Surg*. 2011;67(2):114-8. <https://doi.org/10.1097/sap.0b013e3181f211e1>
- Vargas B, Wildhaber B, La Scala G. Late migration of a foreign body in the foot 5 years after initial trauma. *Pediatr Emerg Care*. 2011;27(6):535-6. <https://doi.org/10.1097/pec.0b013e31821dc6b7>
- Joat RR, Dhok A, Mitra K, Phatak S, Wattamwar GK. An Aberrant Case of Foreign Body Granuloma in the Left Forearm Due to an Impacted Piece of Glass Bangle. *Cureus*. 2023;15(6):e40925. <https://doi.org/10.7759%2Fcureus.40925>
- Courter BJ. Radiographic screening for glass foreign bodies--what does a "negative" foreign body series really mean? *Ann Emerg Med*. 1990;19(9):997-1000. [https://doi.org/10.1016/s0196-0644\(05\)82562-4](https://doi.org/10.1016/s0196-0644(05)82562-4)