

## Efficacy of selective nerve root block in lumbar radiculopathy in police force

Thakur GK<sup>1</sup>, Dumre AP<sup>1</sup>, Lamichhane N<sup>1</sup>, Pokharel RK<sup>2</sup>

<sup>1</sup>Consultant Orthopaedic Surgeon, Department of Orthopaedics, Nepal Police Hospital, Kathmandu

<sup>2</sup>Professor, Department of Orthopaedics and Trauma Surgery, Maharajgunj Medicine Campus, Institute of Medicine, Tribhuvan University Teaching Hospital, Kathmandu

### ABSTRACT

**INTRODUCTION:** Lumbosacral radicular pain due to disc herniation is one of the common disabling conditions in orthopaedic clinics. Most of these patients generally recover well even with non-operative treatment. Selective Nerve Root Block (SNRB) is one of the non-operative procedures for lumbar radiculopathies, both for diagnostic and therapeutic purpose. The aim of our study was to evaluate the efficacy of SNRB in lumbar radiculopathy patients of Nepal Police force due to single level disc prolapse.

**METHODS:** This study was conducted at Nepal Police Hospital from January 2019 to June 2019. There were 29 radicular pain patients who were confirmed by MRI. All patients who met the inclusion criteria were subjected to SNRB with 80 mg of injectable methylprednisolone and 2 ml of 2 % lignocaine. Outcome of the treatment was prospectively evaluated till 6 months of follow up using Numeric Rating Scale (NRS) and Roland Morris Disability Questionnaire (RMDQ).

**RESULTS:** Twenty (69%) patients had disc prolapse at L4-L5 level. Right sided radiculopathies were common (n=19, 65.5%) among them. There was improvement in Numeric Rating Scale (NRS) from pre-procedure average 8.37 to 2.8 post-procedure and Roland Morris Disability Questionnaire (RMDQ) from 15.18 to 6.8 at 6 months follow up. Two cases (6.9%) had to undergo discectomy after 6 weeks of SNRB due to relapse of symptoms.

**CONCLUSION:** Selective Nerve Root Block is effective in immediate reduction of pain in patients with single level disc prolapsed with lumbar radiculopathy. It decreases the disability even in the high level of activity patients like Police personnel.

**KEYWORDS:** Lumbar radiculopathy, Police personnel, SNRB

---

### INTRODUCTION

Lumbar back pain with radiculopathy due to prolapsed intervertebral disc (PIVD) is one of the major causes of physical morbidity.<sup>1</sup> Its lifetime incidence varies from 13% to 40% and the estimated prevalence is 3% to 5% of the population, affecting both men and women.<sup>2, 3</sup>

Radiculopathy is a sharp electric shooting pain that radiates along the course of nerve irritated. It was not clearly established that herniated disc causes pain till Mixter and Barr in 1934, described a clear relationship between lumbar herniated disc and pain.<sup>4</sup> The pathophysiology of pain in PIVD is not only due to mechanical

component, but also due to other factors like chemical inflammation.<sup>5</sup> The slipped nucleus pulposus tissue into the epidural space might induce local immunological reactions, where release of cytokines and other pro-inflammatory substances foster development of epidural inflammation, thus produce back and radicular pain.<sup>5, 6</sup> The majority of patients suffering from a radiculopathy caused by PIVD heal spontaneously without treatment.<sup>7</sup> Resorption of the herniated disc by cell autophagy phenomenon is credited for spontaneous relief of the symptoms<sup>8</sup> and is the scientific basis for its conservative treatment. Clinical course of PIVD varies from acute back pain with radiculopathy to chronic pain.<sup>7, 9</sup> There are different modalities to treat lumbar radiculopathy conservatively, like acupuncture, pain medications with oral steroid and rest.<sup>10</sup> Discectomy surgeries are indicated in cases with cauda equina syndrome, progressive neurological deficits or with severe radicular pain and has very good immediate relief of pain. However, surgery needs expertise and has its own complications.<sup>11, 12</sup>

The local inflammation causing pain due to endoneural edema and increase in nerve root microvascular permeability can be reduced by infiltration of anti-inflammatory agents like steroid in the epidural space through caudal or transforaminal route.<sup>13</sup> Selective Nerve Root Block (SNRB) is practised as a part of the conservative management of radicular pain due to a particular affected nerve root in both cervical and lumbar region.<sup>14, 15</sup> Our study aimed to evaluate the efficacy of single dose SNRB with 80mg of injectable methylprednisolone and 2ml of 2% lignocaine in patients with single level unilateral disc prolapse with lumbar radiculopathy treated in central hospital for police personnel.

## MATERIALS AND METHODS

This study was conducted at Orthopaedics Department, Nepal Police Hospital from Jan

2019 to Jun 2019. All patients (active police personnel) complaining of radicular pain demonstrating a positive Straight Leg Raise Test (SLRT) in 30-60 degrees and not responding to conservative management were selected for the root block procedure. MRI was done in all patients as a standard protocol to confirm the level and type of disc prolapse. Twenty-nine patients having single level postero-lateral disc prolapse affecting a single nerve root were enrolled in this study. Patients with bilateral and multilevel radiculopathies who received SNRB were excluded from the study. Cases with predominant back pain without radiculopathy, progressive neurological deficits, cauda equina syndrome, and history of previous surgery and local infection were excluded from the study.

After obtaining informed consent and obtaining normal routine haemogram, random blood sugar and bleeding profile (PT/INR), patient were shifted to procedure room and positioned in semi prone (oblique) position or in prone position on a fluoroscopy compatible table. Painting and draping done under aseptic precautions. Targeted neural foramen was identified under fluoroscopy by adjusting its inclination till "running dog sign" seen in image intensifier screen. One percent lignocaine was infiltrated along the tract of spinal needle targeting just below the neck of dog. Spinal Needle (22G) was inserted along the tract to reach the desired root canal, triangle of safety (Figure 1). Typical root irritation by tip of the spinal needle was elicited clinically and course of the nerve root was confirmed under fluoroscopy by injecting 0.5ml of iodine based dye. Inj. Methylprednisolone (80mg, 2ml) mixed with 2 ml of 2% Lignocaine was slowly injected after clinical and fluoroscopic confirmation (Figure 2). Local dressing was applied and the patient was observed for 30 minutes in recovery room of operation theatre. Patient was sent home after evaluating immediate relieve of symptoms and neurology of the limb.

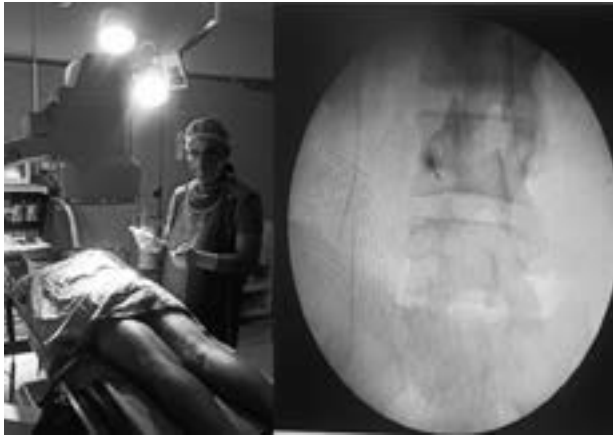


Figure 1: A. Positioning of patient  
B. Positioning the tip of spinal needle under fluoroscopy guidance

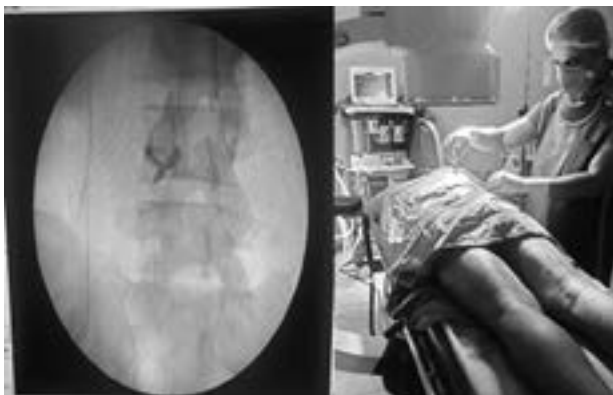

Figure 2: A. confirmation of correct placement of spinal needle with dye injection  
B. Injection of the steroid mixed with lignocaine after confirming correct placement of spinal needle

Numeric Rating scale (NRS) and Roland Morris Disability Questionnaire (RMDQ) were recorded pre-procedure, and at 1 week, 1 month, 3 months and 6 months follow up and statistical analysis was done using SPSS version 24.

**RESULTS**

There were 29 patients (28male and 1 female), all from police force with the mean age of the 35.3 years and ranging from 22 to 48 years. Radiculopathy was of less than 6 months’ duration in 28 (96.2%) patients, one patient had chronic pain of 1-year duration. Right sided radiculopathy was more common (n= 19, 65.5%) than left (n=10, 34.5%). L4-L5 level was involved in 20 (69%) patients, L5-S1 was in

8(27.6%) and 1 (3.4%) patient had involvement of L3-L4 level.

Pre-procedure mean Numeric Rating Scale was 8.37 (range 7 to 10), and mean RMDQ was 15.18 (range 12 to 22).

Patients had excellent immediate relief of radicular pain after the procedure. Mean NRS was 2.8 at 1 week and 3.6, 3.4 and 2.6 at subsequent follow up of 1, 3 and 6 months respectively; and the mean RMDQ was 6.8 at 1 week and 9.1, 7.2, and 6.4 at subsequent follow up at 1,3 and 6 months respectively (Table 1).

Table 1: Mean Numeric Rating Scale and RMDQ

Time of evaluation	Mean NRS	Mean RMDQ
Pre Procedure	8.37	15.18
1 week	2.8	6.8
1 month	3.6	9.1
3 months	3.4	7.2
6 months	2.6	6.4

**DISCUSSION**

Natural course of PIVD usually has favourable prognosis due to spontaneous decrease in size of the herniated disc.<sup>16</sup> Teplick<sup>17</sup> first reported spontaneous regression of herniated nucleus pulposus (HNP), and suggested three theoretical possibilities: i) Dehydration and shrinkage of the HNP; ii) regression of the HNP into the annulus via the tear in the annulus; and iii) fragmentation and subsequent sequestration at a distance from the annulus and from the nerve root. Macrophages act locally and the herniated disc is reabsorbed.<sup>7</sup> Cell autophagy has been said to be protective against disc degeneration and the reabsorption of lumbar disc herniation, which might be the basis for conservative treatment of PIVD.<sup>8</sup>

Patients having lumbar radiculopathy with or without minor neurological deficits usually recover regardless of treatment modality, non-operative or operative.<sup>18</sup> Despite an abundant literature there is still a controversy concerning

the treatment of radiculopathies related to lumbar intervertebral discs.<sup>14, 19-21</sup> The pathophysiology of back and radicular pain in disc herniation is combination of inflammatory, immunological, and mechanical factors leading to nerve root oedema.<sup>5, 6</sup> The immunosuppressant and anti-inflammatory properties of corticosteroids injected around the root to bath it should reduce swelling and nerve root impingement.<sup>22</sup> This is the basis for the practice of epidural steroid injection for sciatic neuralgia, and it can be injected through caudal, transforaminal or interlaminar routes.<sup>23</sup> Use of autologous platelet rich plasma (PRP) in epidural space may be an alternative to steroid injection as a new approach in horizon in management of PIVD.<sup>22</sup>

In 1971, Macnab<sup>24</sup> introduced selective nerve root blocks (SNRBs) first, and is widely practiced these days. SNRBs can be used for both diagnostic and/or therapeutic purpose, and has permanent to temporary symptomatic relieving effect in PIVD and spinal canal stenosis.<sup>14, 25</sup>

We have been practicing SNRB in our centre to treat lumbar radicular pain after other conservative treatment is exhausted and patient is still symptomatic with severity of pain >7 NRS with or without mild neurological deficits. Patients are counselled for surgery if SNRB does not work. Radiculopathies was acute in 28 (96.2%) patients, but one had chronic pain. Lower lumbar disc prolapse were common, 69% at L4-5 level and 27.6% at L5-S1 level which is similar to other studies.<sup>26-28</sup> Pre-procedure mean Numeric Rating Scale was 8.37 (range of 7 to 10), and mean RMDQ was 15.18 (range of 12 to 22).

Patients had excellent immediate relief of radicular pain. Two patients (6.9%) in our series had recurrence of symptoms and had to undergo discectomy surgery after 6 weeks of injection. Rest of 27 patients were happy with the result and avoided surgery. Mean NRS was 2.8 at 1 week and 3.6, 3.4 and 2.6 at 1, 3 and 6 months follow up respectively; and the mean RMDQ was 6.8 at

1 week and 9.1, 7.2, and 6.4 at subsequent follow up at 1, 3 and 6 months respectively. (Table 1) Gaurav et al<sup>28</sup> reported positive clinical efficacy of SNRB in similar age but in general Nepalese people. He found that VAS and disability index scores significantly become better till around six months and then they plateau. There is no difference in outcome at 6 months and one year. However, unlike a steady recovery in their study, in our series, immediate relief of symptom was very good at 1<sup>st</sup> week follow-up, the NRS and RMDQ became slightly worse during 1 and 3 months. This might be because police personnel are exposed high-level activity and they were advised to resume their work after 1 month of procedure. At 6 months, final follow-up of this study the outcome was good and that is in accordance with previous studies.<sup>26, 28, 29</sup>

There are studies concluding that SNRB has small and short-lived benefits and recurrence is expected needing surgery.<sup>20, 21, 27</sup> Our result however, further supports recommendations from a systemic review by Benoy Benny and PariAzari that SNRB has long term pain relief in most of the patients.<sup>30</sup> There is a strong evidence for transforaminal injections in the treatment of lumbosacral radicular pain for both short term and long-term relief, and is less expensive and less invasive treatment modality to treat lumbar radiculopathy.<sup>26, 29</sup>

Larger sample size and longer follow up period would have further strengthened the findings of our study.

## CONCLUSION

Selective Nerve Root Block is a reliable option for acute pain management in patients with single level lumbar disc prolapse and radiculopathy. It results in significant improvement in pain and disability even in patients with high level of activity like police personnel. Furthermore, this procedure has an advantage of being a day care procedure without any severe complications.

## REFERENCES

1. Wheeler SG, Wipf JE, Staiger TO, Deyo RA, Jarvik JG. Evaluation of low back pain in adults. *UpToDate*. 2016.
2. Tarulli AW, Raynor EM. Lumbosacral radiculopathy. *Neurologic clinics*. 2007;25(2):387-405.
3. Schoenfeld AJ, Laughlin M, Bader JO, Bono CM. Characterization of the incidence and risk factors for the development of lumbar radiculopathy. *Clinical Spine Surgery*. 2012;25(3):163-7.
4. Mixer WJ, Barr JS. Rupture of the intervertebral disc with involvement of the spinal canal. *New England Journal of Medicine*. 1934;211(5):210-5.
5. Wheeler AH, Murrey DB. Chronic lumbar spine and radicular pain: Pathophysiology and treatment. *Current pain and headache reports*. 2002;6(2):97-105.
6. McCARRON RF, Wimpee MW, Hudkins PG, Laros GS. The inflammatory effect of nucleus pulposus. A possible element in the pathogenesis of low-back pain. *Spine*. 1987;12(8):760-4.
7. Benoist M. The natural history of lumbar disc herniation and radiculopathy. *Joint Bone Spine*. 2002;69(2):155-60.
8. Diao Z-J, Jiang H, Liu J-T. Significance of cell autophagy in resorption of lumbar disc herniation. *Zhongguo gu shang= China journal of orthopaedics and traumatology*. 2018;31(4):386-90.
9. Cowan N, Bush K, Katz D, Gishen P. The natural history of sciatica: a prospective radiological study. *Clinical radiology*. 1992;46(1):7-12.
10. Saal JA, Saal JS. Nonoperative treatment of herniated lumbar intervertebral disc with radiculopathy. An outcome study. *Spine*. 1989;14(4):431-7.
11. Weinstein JN, Lurie JD, Tosteson TD, Skinner JS, Hanscom B, Tosteson AN, et al. Surgical vs nonoperative treatment for lumbar disk herniation: the Spine Patient Outcomes Research Trial (SPORT) observational cohort. *Jama*. 2006;296(20):2451-9.
12. Gugliotta M, da Costa BR, Dabis E, Theiler R, Jüni P, Reichenbach S, et al. Surgical versus conservative treatment for lumbar disc herniation: a prospective cohort study. *BMJ open*. 2016;6(12):e012938.
13. Stafford M, Peng P, Hill D. Sciatica: a review of history, epidemiology, pathogenesis, and the role of epidural steroid injection in management. *British journal of anaesthesia*. 2007;99(4):461-73.
14. Narozny M, Zanetti M, Boos N. Therapeutic efficacy of selective nerve root blocks in the treatment of lumbar radicular leg pain. *Swiss medical weekly*. 2001;131(0506).
15. Chung J-Y, Yim J-H, Seo H-Y, Kim S-K, Cho K-J. The efficacy and persistence of selective nerve root block under fluoroscopic guidance for cervical radiculopathy. *Asian spine journal*. 2012;6(4):227.
16. Takada E, Takahashi M, Shimada K. Natural history of lumbar disc hernia with radicular leg pain: Spontaneous MRI changes of the herniated mass and correlation with clinical outcome. *Journal of orthopaedic surgery*. 2001;9(1):1-7.
17. Teplick JG, Haskin ME. Spontaneous regression of herniated nucleus pulposus. *American Journal of Roentgenology*. 1985;145(2):371-5.
18. Weber H. The natural history of disc herniation and the influence of intervention. *Spine*. 1994;19(19):2234-8; discussion 3.
19. Balaji V, Chin K, Tucker S, Wilson L, Casey A. Recovery of severe motor deficit secondary to herniated lumbar disc prolapse: is surgical intervention important? A systematic review. *European Spine Journal*. 2014;23(9):1968-77.
20. Kennedy DJ, Zheng PZ, Smuck M, McCormick ZL, Huynh L, Schneider BJ. A minimum of 5-year follow-up after lumbar transforaminal epidural steroid injections in patients with lumbar radicular pain due to intervertebral disc herniation. *The Spine Journal*. 2018;18(1):29-35.
21. Acaroğlu E, Nordin M, Randhawa K, Chou R, Côté P, Mmopelwa T, et al. The Global Spine Care Initiative: a summary of guidelines on invasive interventions for the management of persistent and disabling spinal pain in low-and middle-income communities. *European Spine Journal*. 2018;27(6):870-8.
22. Lee JH, Kim DH, Kim DH, Shin K, Park SJ, Lee GJ, et al. Comparison of clinical efficacy of epidural injection with or without steroid in lumbosacral disc herniation: A systematic review and meta-analysis. *Pain physician*. 2018;21:449-68.
23. Pandey RA. Efficacy of epidural steroid injection in management of lumbar prolapsed intervertebral disc: A comparison of caudal, transforaminal and interlaminar routes. *Journal of clinical and diagnostic research: JCDR*. 2016;10(7):RC05.
24. Macnab I. Negative disc exploration: an analysis of the causes of nerve-root involvement in sixty-eight patients. *JBJS*. 1971;53(5):891-903.
25. Weiner BK, Fraser RD. Foraminal injection for lateral lumbar disc herniation. *The Journal of bone and joint surgery British volume*. 1997;79(5):804-7.
26. Vashishtha S, Singh SK, Verma A, Anand A. A study on effectiveness of selective nerve root blocks in lumbar radiculopathies. *International Journal of Orthopaedics*. 2019;5(3):191-9.

27. Arun-Kumar K, Jayaprasad S, Senthil K, Lohith H, Jayaprakash K. *The outcomes of selective nerve root block for disc induced lumbar radiculopathy. Malaysian orthopaedic journal. 2015;9(3):17.*
28. Dhakal GR, Hamal PK, Dhungana S, Kawaguchi Y. *Clinical Efficacy of Selective Nerve Root Block in Lumbar Radiculopathy due to Disc Prolapse. Journal of Nepal Health Research Council. 2019;17(2):242-6.*
29. Khan KS, SAH S, Rafiq T, Dolan M, Devitt A, editors. *The Role Of Selective Nerve Root Block In Patients With Lumbar Radiculopathy. Orthopaedic Proceedings; 2004: The British Editorial Society of Bone & Joint Surgery.*
30. Benny B, Azari P. *The efficacy of lumbosacral transforaminal epidural steroid injections: a comprehensive literature review. Journal of back and musculoskeletal rehabilitation. 2011;24(2):67-76.*

**Address for correspondence:**

**GOPESH KUMAR THAKUR**

Nepal Police Hospital, Kathmandu, Nepal

Phone Number: 977- 9851280300

Email: drgopesh2011@gmail.com