

Functional Outcome of Complex Tibial Plateau Fracture Treated by Dual Plating

Mishra AK, Adhikari V, Chalise PK, Shrestha P, Singh RP

Department of Orthopaedics, Nepal Medical College Teaching Hospital, Jorpati, Kathmandu, Nepal

ABSTRACT

INTRODUCTION: Tibial Plateau fractures are very complex due to involvement of joint and the metaphyseal region. Among tibial plateau fracture, 35.8% accounts for bicondylar tibial plateau fracture, which consists of Schatzker type V and VI. Open reduction with minimal soft tissue dissection and fixation of fracture with dual plating is the treatment of choice. The aim of our study is to assess the functional outcome and complication after the fixation of bicondylar tibial plateau fracture with dual plating.

METHODS: The study included total of 30 patients with bicondylar tibial plateau fractures who met the inclusion criteria, were treated with open reduction and internal fixation with dual plates. Bicondylar tibial plateau fractures includes both Schatzker type V (n= 17) and Type VI (n=13).

RESULTS: Knee society score in Schatzker type V out of 17 patients, 9 had excellent results, 7 had good results and 1 had fair results. Knee society score in Schatzker type VI out of 13 patients, 7 had excellent results, 4 had good results and 2 had fair results. Among the 30 patients, we found superficial wound infection in 3 patients during the follow up.

CONCLUSION: The high energy Schatzker type V and VI tibial plateau fractures using double plate fixation through dual incision technique provides stable fixation, a minimal soft tissue dissection with satisfactory functional outcome and low complication rates.

KEYWORDS: Tibial Plateau fracture, Schatzker type V and VI, Bicondylar dual plating, Functional outcome

INTRODUCTION

Proximal tibial fractures are increasing in incidence due to increase in road traffic accidents, fall injury from height and sports activity.¹ Tibial plateau is one of the commonest intra articular fractures. The fractures are very complex due to involvement of joint and the metaphyseal region. The axial loading along with varus/valgus stress force causes the tibial plateau fracture which may involve medial, lateral or both the tibial plateau. Among them, 35.8% accounts for bicondylar tibial plateau fracture, which consists of Schatzker type V and VI.² In one third of the cases, there is involvement of posteromedial

fragment. The goal of the treatment is restoration of articular surface, anatomic alignment and minimal soft tissue dissection with stable fixation for early mobilization of knee.^{3,4} Conservative treatment has lots of complication and poor functional outcomes, so it is not advisable nowadays.⁵ The surgical intervention, especially in bicondylar fracture, is challenging due to significant articular comminution, severe soft tissue injury and intra or post-operative complications.⁶⁻⁹ Open reduction with minimal soft tissue dissection and fixation of fracture with dual plating to medial and lateral side with restoration of articular congruity, maintaining

the alignment, providing the stable fixation for early mobilization of knee is the treatment of choice for bicondylar tibial plateau fracture.¹⁰⁻¹³ The aim of our study is to assess the functional outcome and complication after the fixation of bicondylar tibial plateau fracture with dual incision using dual plates depending upon the fracture geometry for fixation of fracture fragments.

MATERIALS AND METHODS

This is a prospective study which included total of 30 patients admitted in Nepal Medical College and Teaching Hospital from September 2014 to February 2018 with bicondylar tibial plateau fractures Schatzker type V and VI who were treated with open reduction and internal fixation with dual plates through anterolateral approach for lateral fragment and medial or poster medial approach for medial and posteromedial fragment after the soft tissue condition improved. The fracture with unicodylar involvement (Schatzker type I-IV), open fractures, pathological fractures, fractures with neurovascular involvement and polytrauma were ex-cluded from the study.

Preoperative planning consisted of anteroposterior and lateral views X ray of knee in all cases to visualize articular congruity, displacement, depression and angulation.

Once the clinical signs of soft tissue recovery like wrinkling of the skin, healing of the blisters was seen, the patient was taken for surgical intervention. The patients who had significant articular depression and comminution on x rays, computerized tomography (CT) scans was done.

All the patients underwent the same postoperative regimen of iv antibiotics followed by oral antibiotics till suture removal at 2 weeks, Knee mobilization and physiotherapy was started as soon as tolerated by patient with non-weight bearing for 6 weeks followed by partial weight bearing and full weight bearing was allowed after 12-16 weeks when radiograph revealed bony union. Patients were followed up at 2, 6, 12, 24 weeks and 1 year after the operation and

RESULTS

Among the 30 patients which were included in the study there were 19 males and 11 females, with a mean age of 37 years (18 - 57 years) (Table 1).

Table 1: Distribution and type of Fracture

Fracture	Schatzker type V	Schatzker type VI
Male	11	8
Female	6	5

The right sided knee was involved in 17 patients and 13 patients had a left sided knee involvement. At the final follow up, out of 17 patients knee society score in Schatzker type V, 9 had excellent results, 7 had good results and 1 had fair results.

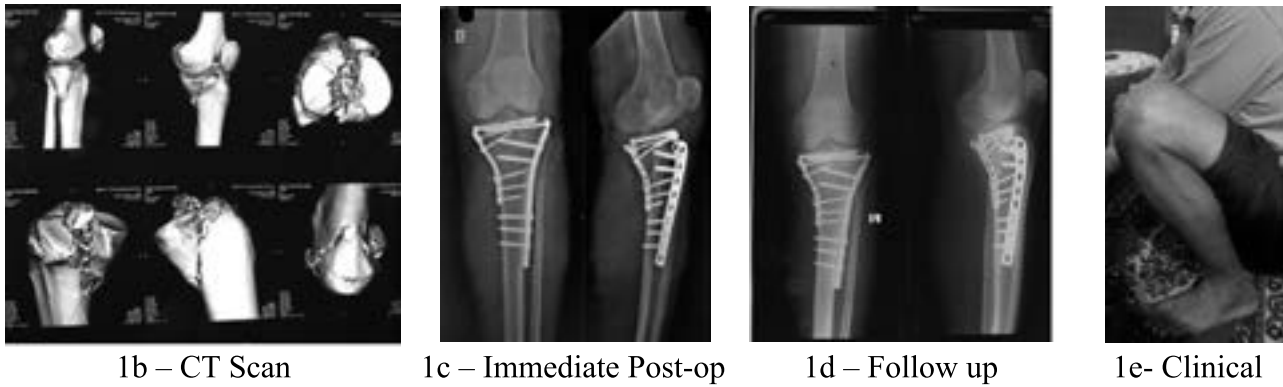
(Table 2) (Fig. 1a-e)

Table. 2: Knee society score in Schatzker type V fracture

S. No	Result	Number (Percentage)
1.	Excellent	9 (52.94%)
2.	Good	7 (41.17%)
3.	Fair	1 (5.89 %)

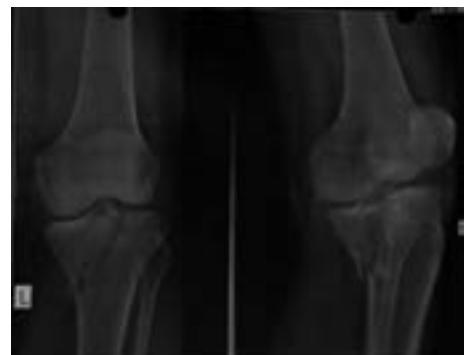

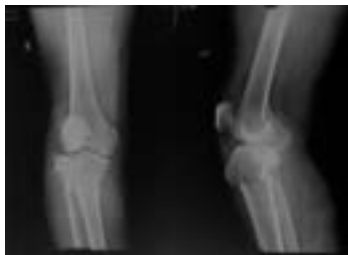Fig. 1a – Preoperative



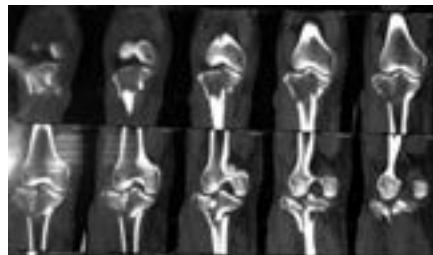
Out of 13 patients, Knee society score in Schatzker type VI, 7 had excellent results, 4 had good results and 2 had fair results. (Table 3) (Fig. 2 a-e).

Table. 3: Knee society score in Schatzker type VI fracture

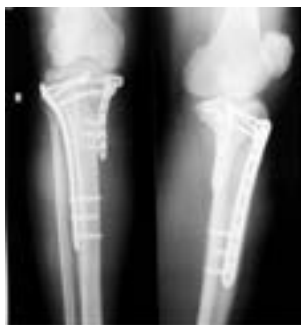S. No	Result	Num-ber(Percentage)
1	Excellent	7 (53.84 %)
2	Good	4 (30.76 %)
3	Fair	2 (15.4 %)



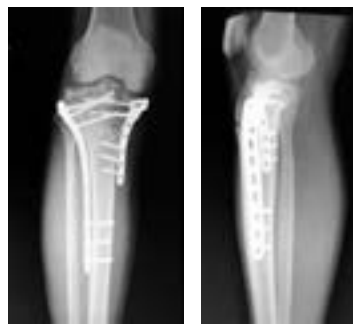2a – Preoperative



2b-CT Scan



2c – Immediate post-op



2d- Follow up



2e- Clinical

All the fractures were healed, bony union was considered when the 3 cortices were obliterated and which was achieved during the average of 14 weeks.

Among the 30 patients, we found superficial wound infection in 3 patients during the follow up. Two cases were resolved by oral antibiotics and one case required debridement which later on resolved.

DISCUSSION

Tibial plateau fractures are very complex injuries due to the involvement of joint and metaphyseal - diaphyseal dissociation, specially Schatzker type V and VI fractures.^{14,15} The optimal treatment of Schatzker type V and VI tibial plateau fractures is the most difficult to treat due to various problems like wound dehiscence, varus collapse and severe comminution leading

to malalignment causing arthritis of knee joint later on.¹⁶ Schatzker type V and VI tibial plateau fracture remains a challenging and problematic, despite the development of implants for fracture fixation and better technique for the soft tissue care. The goal of treatment in tibial plateau fractures are restoration of the articular surface and alignment with preservation of soft tissues and stable fixation that allows for early mobilization of knee joint.¹⁷ There are basically two methods of fixation, external fixator or open reduction and internal fixation with plate and screws for tibial plateau fractures. The surgical treatment of tibial plateau fractures can lead to many complications like neurovascular injury, compartment syndrome, wound dehiscence, infection, varus collapse, nonunion, implant failure and osteoarthritis.¹⁸⁻²⁰

The tibial plateau fractures treated with external fixator leads to fewer complications related to soft tissues but have high rate of infection around the pins site and stiff knee due to delayed mobilization of knee joint, whereas open reduction and internal fixation with plates maintain anatomic articular congruity, alignment and allow early mobilization of knee joint.²¹⁻²³

In the present study, we are focused on functional outcome and complication after the fixation of Schatzker type V and VI tibial plateau fractures with lateral plating through anterolateral approach and medial or posterior plating through posteromedial approach.

In our series, out of 17 patients of Schatzker type V, 52.94% (n=9) had excellent, 41.17% (n=7) had good and 5.89% (n=1) had fair results of knee society score. Out of 13 patients of Schatzker type VI, 53.84% (n=7) had excellent, 30.76% (n=4) had good and 15.4% (n=2) had fair results of Knee Society score. Our finding is similar with other studies done by Yu et al, Prasad et al, Barei et al in Schatzker Type V and VI tibial plateau fractures.^{24,25,26}

In our study, 10% patients (n=3) had a superficial infection whereas no patient had significant deep infection, requiring implant removal prior to bony union. The soft tissue consideration should

be taken prior to definitive surgery to avoid the post-operative wound complication. The average wound infection rate in the literature is around 20% in the dual plating group.²⁷ In our study, it is 10% which is definitive surgery done once the soft tissue condition improved and with minimal soft tissue dissection during surgery.

CONCLUSION

The high energy Schatzker V and VI tibial plateau fractures using dual plate fixation through dual incision technique provides stable fixation, a minimal soft tissue dissection with satisfactory functional outcome and low complication rates. However, studies involving larger number of patients are required to establish our findings.

REFERENCES

1. Yao, Lv H, Zan J, Zhang J, Zhu N, Ning R, Jing J. A comparison of lateral fixation versus dual plating for simple bicondylar fractures. *Knee* 2015; 22: 225–229.
2. Zhang YZ. *Clinical epidemiology of orthopedic trauma. Fracture of tibia and fibula.* People's Medical Publishing House, Beijing 2014: 289–294.
3. Barei DP, Nork SE, Mills WJ, Coles CP, Henley MB, Benirschke SK. Functional outcomes of severe bicondylar tibial plateau fractures treated with dual incisions and medial and lateral plates. *J Bone Joint Surg Am* 2006; 88: 1713–1721.
4. Yao Y, Lv H, Zan J, Li J, Zhu N, Jing J. Functional outcomes of bicondylar tibial plateau fractures treated with dual buttress plates and risk factors: a case series. *Injury* 2014; 45: 1980–1984.
5. Lansinger O, Bergman B, Körner L, Andersson GB. Tibial condylar fractures. A twenty-year follow-up. *J Bone Joint Surg Am* 1986; 68: 13–9.
6. Gosling T, Schandelmaier P, Muller M, Hankemeier S, Wagner M, Krettek C. Single lateral locked screw plating of bicondylar tibial plateau fractures. *Clin Orthop Relat Res* 2005; 439: 207–214.
7. Barei DP, Nork SE, Mills WJ, Coles CP, Henley MB, Benirschke SK. Functional outcomes of severe bicondylar tibial plateau fractures treated with dual incisions and medial and lateral plates. *J Bone Joint Surg Am* 2006; 88: 713–1721.
8. Chang SM, Hu SJ, Zhang YQ, Yao MW, Ma Z, Wang X, Dargel J, Eysel P. A surgical protocol for bicondylar four-quadrant tibial plateau fractures. *Int Orthop* 2014; 38(10): 2559–2564.

9. Zhai Q, Hu C, Luo C. Multi-plate reconstruction for severe bicondylar tibial plateau fractures of young adults. *Int Orthop* 2014; 38: 1031–1035.
10. Lee MH, Hsu CJ, Lin KC, Renn JH. Comparison of outcome of unilateral locking plate and dual plating in the treatment of bicondylar tibial plateau fractures. *J Orthop Surg Res* 2014; 9: 62.
11. Higgins TF, Klatt J, Bachus KN. Biomechanical analysis of bicondylar tibial plateau fixation: how does lateral locking plate fixation compare to dual plate fixation?. *J Orthop Trauma* 2007; 21: 301–306.
12. Egol KA, Su E, Tejwani NC, Sims SH, Kummer FJ, Koval KJ. Treatment of complex tibial plateau fractures using the less invasive stabilization system plate: clinical experience and a laboratory comparison with double plating. *J Orthop Trauma* 2004; 57: 340–346.
13. Ali AM, Saleh M, Bolongaro S, Yang L. The strength of different fixation techniques for bicondylar tibial plateau fractures—a biomechanical study. *Clin Biomech (Bristol, Avon)* 2003; 18: 864–870.
14. Watson JT. High-energy fractures of the tibial plateau. *Orthop Clin North Am* 1994; 25: 723–52.
15. Wang J, Wei J, Wang M. The distinct prediction standards for radiological assessments associated with soft tissue injuries in the acute tibial plateau fracture. *Eur J Orthop Surg Traumatol* 2015; 25: 913–20.
16. Rohra N, Suri HS, Gangrade K. Functional and radiological outcome of Schatzker type V and VI tibial plateau fracture treatment with dual plates with minimum 3 years follow-up: a prospective study. *J Clin Diagn Res* 2016; 10: RC05–10.
17. Terry Canale S. *Tibial Plateau Fractures. Campbell's Operative Orthopaedics. Pennsylvania: Mosby Elsevier* 1998 : 2094-109.
18. Mckee MD, Pirani SP, Stephen DJ. *The Canadian Orthopedic Trauma Society, Open reduction and internal fixation compared with circular fixator application for bicondylar tibial plateau fractures. Results of a multicenter, prospective, randomized clinical trial. J Bone Joint Surg Am* 2006; 88: 2613-23.
19. Young MJ, Barrack RL. Complications of internal fixation of tibial plateau fractures. *Orthop Rev* 1994; 23: 149-54.
20. Moore TM, Patzakis MJ, Harvey JP. Tibial plateau fractures: Definition, demographics, treatment rationale and long-term results of closed traction management or operative reduction. *J Orthop Trauma* 1987; 1: 97-119.
21. Kumar A, Whittle AP. Treatment of complex (Schatzker Type VI) fractures of the tibial plateau with circular wire external fixation: retrospective case review. *J Orthop Trauma* 2000; 14: 339-44.
22. Hutson JJ Jr, Zych GA. Infections in periarticular fractures of the lower extremity treated with tensioned wire hybrid fixators. *J Orthop Trauma* 1998; 12: 214-8.
23. Watson JJ and Wiss AD. *Rockwood and Green's fractures in adults: Fractures of the proximal tibia and fibula. Bucholz RW and Heckman JD Ed. 5th ed. Philadelphia: Lip-pincott Williams and Wilkins* 2001; 2: 1799-1839.
24. Yu Z, Zheng L, Zhang Y, Li J, Ma B. Functional and radiological evaluations of high energy tibial plateau fractures treated with double-buttruss plate fixation. *Eur J Med Res* 2009; 14(5): 200-05.
25. Prasad GT, Kumar TS, Kumar RK, Murthy GK, Sundaram N. Functional outcome of Schatzker type V and VI tibial plateau fractures treated with dual plates. *Indian J Orthop* 2013; 47(2): 188–94.
26. Barei DP, Nork SE, Mills WJ, Coles CP, Henley MB, Benirschke SK. Functional outcomes of severe bicondylar tibial plateau fractures treated with dual incision and medial and lateral plates. *J Bone Joint Surg Am* 2006; 88(8): 1713-21.
27. Mckee MD, Pirani SP, Stephen DJ. *The Canadian Orthopedic Trauma Society, Open reduction and internal fixation compared with circular fixator application for bicondylar tibial plateau fractures. Results of a multicenter, prospective, randomized clinical trial. J Bone Joint Surg Am* 2006; 88: 2613-23.

Address for correspondence:**ANIL K. MISHRA**

Department of Orthopaedics,
Nepal Medical College Teaching Hospital, Jorpati, Kathmandu, Nepal
e-mail: dranilmishra3@gmail.com