

Radiographic Measurements of Normal Knee Joint Space in Adults

Kayastha P¹, Khatun N², Paudel S³, Regmi PR⁴, Dhakal P⁵,
Adhikari G⁵, Upadhyaya RU⁵, Maharjan S⁵

¹Assistant Professor, ²Technologist, ³Associate Professor, Department of Radiology, Tribhuvan University Teaching Hospital (TUTH), ⁴Pediatric Radiologists, Department of Radiology, Hospital for Advanced Medicine and Surgery (HAMS), ⁵Consultant Radiologist, Department of Radiology, Grande International Hospital, Kathmandu, Nepal

Received: October 16, 2021

Accepted: November 19, 2021

Published: December 31, 2021

Cite this paper:

Kayastha P, Khatun N, Regmi PR, et al. Radiographic measurements of normal knee joint space in adults. *Nepalese Journal of Radiology*. 2021;11(2):19-25. <https://doi.org/10.3126/njr.v11i2.44384>

ABSTRACT

Introduction:

The knee joint is the space between the femoral and tibial condyles. The tibiofemoral articulations are separated by articular cartilages and menisci; with little contributions from cruciate ligaments. These are collectively seen on a radiograph as a radiolucent area between the bony tibial and femoral condyles. This study was conducted to measure the normal knee joint space in patients referred for X-Ray to the Department of Radiology of a tertiary care hospital.

Methods:

This descriptive cross-sectional study was performed from 1st January to 1st April 2021 in the Department of Radiology and Imaging, Tribhuvan University Teaching Hospital (TUTH). A total of 157 patients were involved. The radiographic joint space width in the knee joint was measured in both medial and lateral compartments of bilateral knees in correlation with age and gender.

Results:

The mean right medial, left medial, right lateral, and left lateral spaces for females were 0.25±0.08 cm, 0.23±0.09 cm, 0.49±0.10 cm, and 0.49±0.29 cm respectively. Similarly, the mean right medial left medial, right lateral, and left lateral spaces for males were 0.26±0.07 cm, 0.10±0.09 cm, 0.18±0.09 cm, and 0.17±0.08 cm respectively. There was a strong positive correlation between both right and left joint spaces about age.

Conclusion:

The radiographic reference values for the joint space width were obtained, showing a positive correlation with age and no significant gender variations in bilateral knees.

Keywords: Cartilage, Articular; Knee Joint; X-Rays

Correspondence to: Dr. Sharma Paudel
Department of Radiology and Imaging,
Tribhuvan University Teaching Hospital (TUTH)
Kathmandu, Nepal
E-mail address: sharmapaudel@gmail.com



Licensed under CC BY 4.0 International License which permits use, distribution and reproduction in any medium, provided the original work is properly cited

INTRODUCTION

The knee is a weight-bearing synovial hinge joint comprising two condyles (between the femoral and corresponding tibial condyles); and a saddle joint (between the patella and the patellar surface of the femur). The tibiofemoral articulations are separated by articular cartilages and menisci; with little contributions from cruciate ligaments. The measurement of the distance between the distal femur and the proximal tibia known as joint space width (JSW), is an indirect way of measuring cartilage thickness. This has become the standard and reproducible tool for the assessment of progressive knee cartilage degenerative conditions with fairly good precision. These are seen on a frontal radiograph as a radiolucent area between the bony tibial and femoral condyles, measuring between 3 to 8 mm.^{1,2} Usually, the lateral knee JSW is wider than the medial and males tend to have wider JSW than females.³

Osteoarthritis (OA), a degenerative disease, is a leading cause of knee joint narrowing. It is the most common joint disorder and is responsible for substantial economic, social, and psychological costs. The majority of individuals over the age of 65 years in developed nations demonstrate radiographic evidence of OA. Osteoarthritis may be idiopathic or secondary to previous inflammation or trauma. One of its earliest signs may be the narrowing of the medial compartments of the joint. This is followed by subchondral sclerosis and cystic changes of the articular surface. As a result of wear and tear over time, there is a gradual reduction in JSW with increasing age.^{3,4}

The techniques of quantitatively assessing knee joint spaces using, digital radiographs have a low inter-observer coefficient of variation ranging from 1% to 3.3%; and are better than that obtained by the use of dividers and rulers. The computerized measurement of joint space width from standard radiographs is applicable to monitor the progression of knee degenerative conditions and is of value in the evaluation of disease-modifying therapies for osteoarthritis.⁴⁻⁸ Therefore, we are measuring the JSW in bilateral knees in the adult population in this study thereby correlating the JSW with age and differences between the right and left knees.

METHODS

This was a quantitative, radiographic study conducted in the Department of Radiology and Imaging, Tribhuvan University Teaching Hospital (TUTH) for three months. A purposive non-probability sampling technique was used in the sampling of the subjects. The adult population above 20 years referred for X-Ray Knee was included in the study. Knee with fractures was excluded from the study. An anteroposterior weight-bearing x-ray was performed. The patient stood in front of the cassette with the posterior thigh in contact with the cassette. Irradiation was applied in the horizontal direction. Measurements were taken of erect bilateral knees in anteroposterior (AP) view projection.^{3,9,10}

Statistical analysis was carried out with the help of SPSS version 20 and Microsoft Excel 2013. The mean, SD, and comparison of different knee joint space measurements were expressed in tables and bar diagrams. Data were presented as mean and SD for all the variables. The patient's age, gender, right medial space, right lateral space, left medial space and left lateral space were recorded. Data were tested for normal distribution using the Shapiro-Wilk test. Mann-Whitney test, Spearman's correlation, paired t-test, and the pear correlation coefficient was used for statistical analysis. A 95% confidence interval was taken and $p < 0.05$ was taken as statistically significant.

Table 1: Measurement of joint space based on age group in female

Age Group	RMS	RLS	LMS	LLS
20-29	0.21±0.04	0.50±0.02	0.22±0.06	0.51±0.04
30-39	0.26±0.08	0.46±0.09	0.27±0.09	0.46±0.08
40-49	0.23±0.08	0.48±0.07	0.18±0.08	0.49±0.08
50-59	0.28±0.08	0.49±0.11	0.25±0.09	0.50±0.09
60-69	0.23±0.08	0.52±0.09	0.21±0.07	0.51±0.11
70 Above	0.19±0.08	0.46±0.23	0.25±0.08	0.51±0.15

RMS-right medial space, RLS-right lateral space, LMS- left medial space, LLS-left lateral space

RESULTS

The data was collected from 157 subjects with the age above 20 years. Among them 95(60.51%) were female and 62(39.49%) were male. The mean age

group of the sample population was 47.27 ± 13.499 years (Fig. 1).

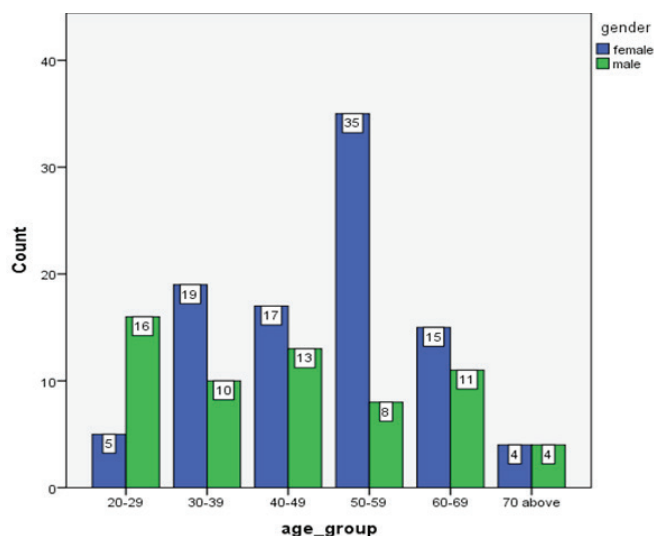


Figure 1: Bar diagram of the distribution of sample size according to age group

The mean right medial left medial, right lateral, and left lateral for females were 0.25 ± 0.08 , 0.23 ± 0.09 , 0.49 ± 0.10 , and 0.49 ± 0.29 respectively. Similarly, the mean right medial left medial, right lateral, and left lateral for males were 0.26 ± 0.07 , 0.10 ± 0.09 , 0.18 ± 0.09 , and 0.17 ± 0.08 respectively. There was a strong positive correlation between RMS and LMS ($r=0.677$, $p<0.001$), which is statically significant at $p<0.05$. There was also a strong positive correlation between RLS and LLS ($r=0.632$, $p<0.001$) which is statically significant at $p<0.05$.

Table 2: Measurement of joint space based on age group in male

Age Group	RMS	RLS	LMS	LLS
20-29	0.22 ± 0.03	0.45 ± 0.06	0.23 ± 0.04	0.47 ± 0.08
30-39	0.21 ± 0.00	0.43 ± 0.02	0.19 ± 0.04	0.45 ± 0.04
40-49	0.29 ± 0.05	0.47 ± 0.08	0.29 ± 0.10	0.45 ± 0.05
50-59	0.28 ± 0.08	0.43 ± 0.09	0.31 ± 0.03	0.50 ± 0.12
60-69	0.29 ± 0.10	0.52 ± 0.14	0.30 ± 0.02	0.48 ± 0.12
70 Above	0.31 ± 0.06	0.43 ± 0.11	0.25 ± 0.07	0.53 ± 0.08

RMS-right medial space, RLS-right lateral space, LMS- left medial space, LLS-left lateral space

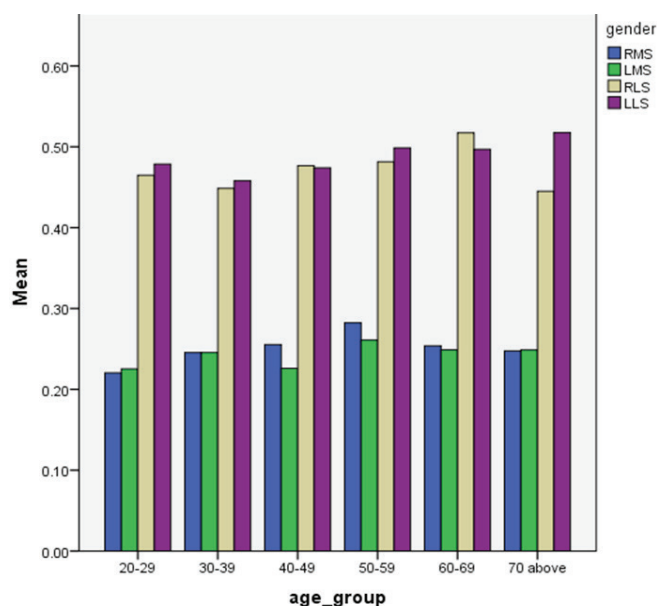


Figure 2: Bar chart showing the relationship between the age group and measured Joint space width (JSW)

Table 3: Evaluation of different joint spaces based on gender

	Female		Male	
	Range (maximum-minimum)	Mean±SD	Range (maximum-minimum)	Mean±SD
RMS	0.47-0.12	0.25 ± 0.08	0.46-0.16	0.26 ± 0.07
LMS	0.45-0.10	0.23 ± 0.09	0.44-0.10	0.10 ± 0.09
RLS	0.72-0.18	0.49 ± 0.10	0.70-0.18	0.18 ± 0.09
LLS	0.71-0.29	0.49 ± 0.29	0.65-0.17	0.17 ± 0.08

It represents the articular cartilage and the menisci while the inter-condylar notch of the femur and the inter-condylar eminence of the tibia is seen opposite to one another. The medial and lateral condyles of the tibia, as well as the head and neck of the fibula, appear well corticated.^{1,2,7} On the lateral view of the knee joint, the fabella is seen as sesamoid bone in the lateral head of the gastrocnemius. It can be shown behind the lateral condyle of the femur if present. The patella is seen in front of the femoral condyles while the tibial tuberosity is seen on the front of the upper end of the tibia.^{1,7,11}

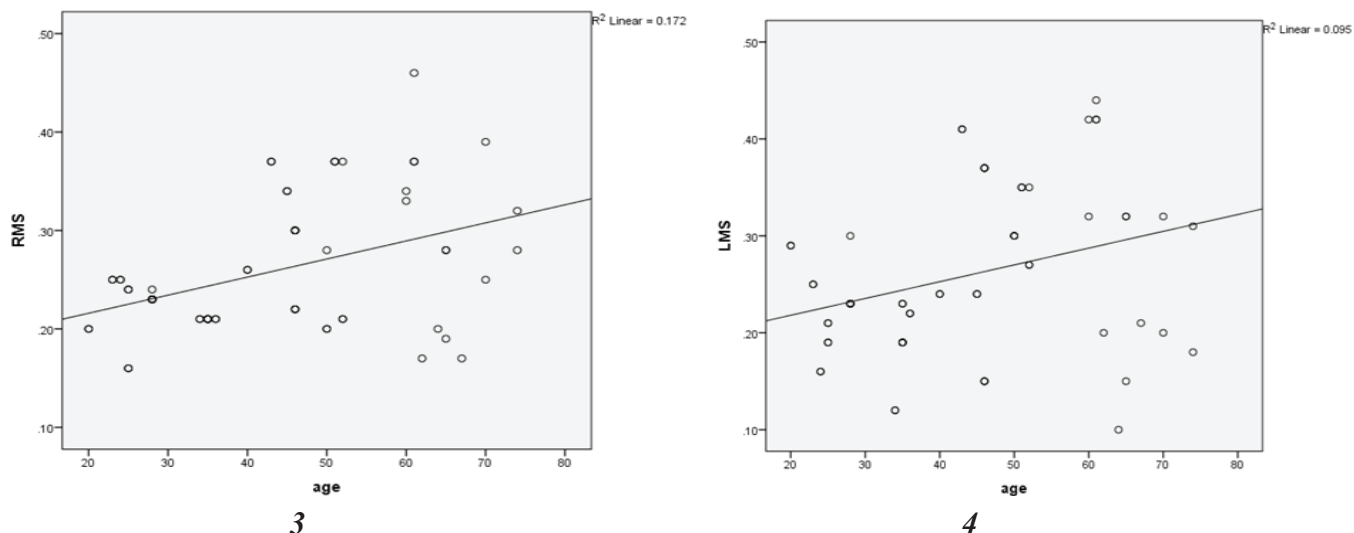


Figure 3: A strong positive correlation was observed between age and RMS (right medial space) with $r=0.677$ ($p<0.001$) which is statistically significant at $p<0.05$.

Figure 4: A strong positive correlation was observed between age and LMS (left medial space) with $r=0.677$ ($p<0.001$) which is statistically significant at $p<0.05$

DISCUSSION

The knee is a synovial hinge joint between thigh and leg. The articular surfaces include the condyles and the patellar surfaces of the femur, the tibial articular surfaces on the tibial plateau, and the deep surface of the patella.^{1,2}

1. Normal Radiographic Anatomy of the knee

The anteroposterior knee radiograph shows the well corticated two femoral condyles and the adductor tubercle. The joint space is the radiolucent area between the articular surfaces of the femur and tibia.

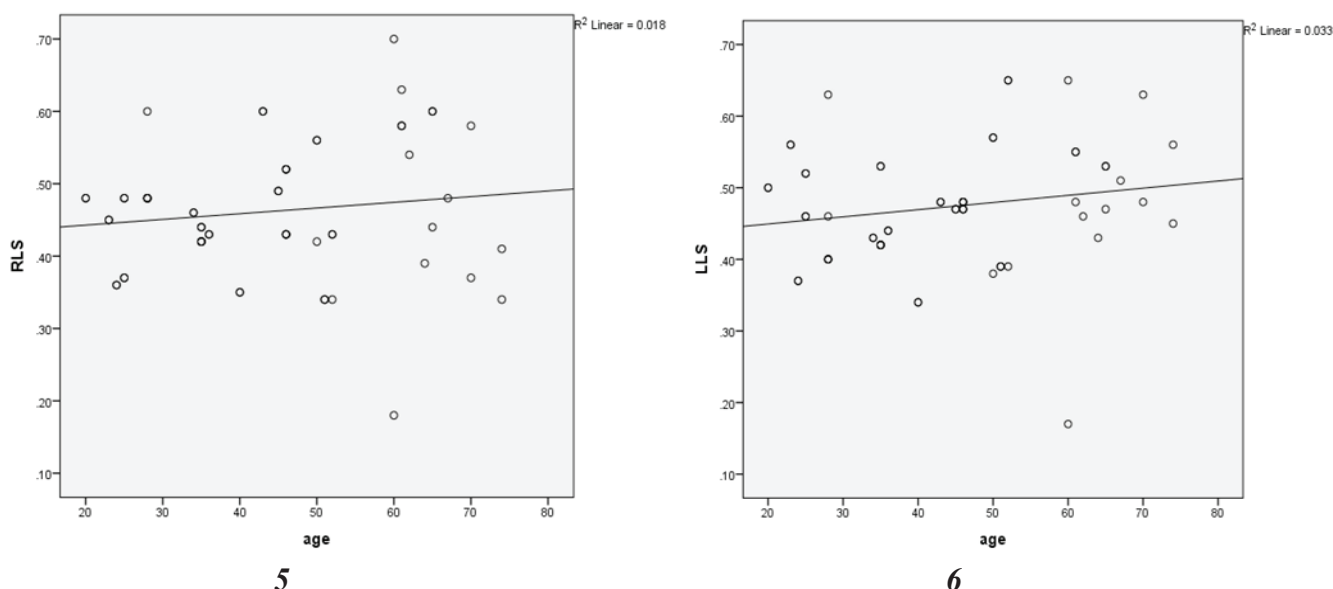


Figure 5: A strong positive correlation was observed between age and RLS (Right lateral space) with $r=0.632$ ($p<0.001$) which is statistically significant at $p<0.05$

Figure 6: A strong positive correlation was observed between age and LLS (left lateral space) with $r=0.632$ ($p<0.001$) which is statistically significant at $p<0.05$

The head of the fibula is seen overlapping the tibial meta-diaphysis. The intercondylar eminence of the tibia can be identified as the bony elevation at the midpoint of the tibial condyles. The 16 tibial tuberosity is very variable in appearance, particularly during the growth period. Asymmetry and irregularity on radiographs may be quite normal.⁷ Subcutaneous and intra-articular fat (the infrapatellar fat pad) outlines some of

the soft tissues around the joint. The suprapatellar bursa is best seen on radiographs when distended with fluid. It is then seen as a soft-tissue density above the patella.¹

We measured the knee joint space on two sides (medial and lateral width) on bilateral erect knee AP radiographs of normal adults. The medial and lateral width of knee joint space differs on each side. In our study, the mean right medial left medial, right lateral, and left lateral for females were 0.25 ± 0.08 , 0.23 ± 0.09 , 0.49 ± 0.10 , and 0.49 ± 0.29 respectively. Similarly, the mean right medial left medial, right lateral, and left lateral for males were 0.26 ± 0.07 , 0.10 ± 0.09 , 0.18 ± 0.09 , and 0.17 ± 0.08 respectively. There was a strong positive correlation between RMS and LMS ($r=0.677$, $p<0.001$), which is statically significant at $p<0.05$. There was also a strong positive correlation between RLS and LLS ($r=0.632$, $p<0.001$) which is statically significant at $p<0.05$. No statistically significant difference between right and left joint space width as well as no statistically significant difference between male and female knee joint space was seen. There are several publications similar to our study.¹²⁻²¹

The study by Anas et al. in 2012 measured the mean right medial and lateral joint space width to be 4.74 ± 0.75 and $5.63\text{mm}\pm 0.86$, respectively.³ The mean left medial and lateral joint space width measured $4.74\text{ mm}\pm 0.76$ and 5.66 ± 0.87 . No statistically significant difference was found between the right and left joint space compartments similar to our study. Déborah et al. performed on 2009 performed knee radiographs on women from the OFELY (Os des Femmes de Lyon) Cohort. Posteroanterior

radiographs of both knees were taken in semi-flexion with a standardized fluoroscopically assisted protocol.²² Joint space narrowing, osteophytes, and sclerosis were assessed from radiographs of 606 women (ages 39-90 years, mean 62 years) for each tibiofemoral compartment and each side. They found that in all subjects, JSW significantly decreased with age in every compartment including in 358 subjects without any radiographic abnormality related to osteoarthritis (OA) at baseline. The longitudinal analysis confirmed a significant loss over four years of $\sim 0.30\text{ mm}$ (6%) for the medial compartment.

In 2008, Beattie et al. performed minimum joint space width and tibial cartilage morphology in the knees of healthy individuals. Out of 119 healthy participants, 73 were female and 47 were male: mean (SD) age $38.2(13.2)$ years, mean BMI $25.0(4.4)\text{ kg/m}^2$.²³ Minimum JSW values were calculated for each sex and decade of life. Analysis revealed mean JSW did not significantly decrease with increasing decade ($p>0.05$) in either sex. These data suggest that medial JSW values do not decrease with aging in healthy individuals but remain fairly constant throughout the lifespan with healthy values of 4.8 mm for females and 5.7 mm for males. Similar trends were seen for cartilage. The study by Jain et al., performed a radiographic evaluation of knee joint space width using a fixed flexion view on the knees of Indian adults.²⁴ They measured the mean left medial and lateral joint space width to be $5.34\text{mm}\pm 1.26\text{ mm}$ and $5.21\text{mm}\pm 1.04\text{ mm}$ and on the right side $5.26\pm 1.11\text{ mm}$ and $5.57\pm 1.57\text{ mm}$ respectively. No statistically significant differences were found between right and left knee joint space width compartments. From their study, they concluded that there were no statistical differences found between right and left knee joint space width compartments similar to our study.

CONCLUSION

The medial and lateral space of bilateral knee joints were measured in a radiograph of erect knee AP view. Variation exists in radiographic images in the

medial and lateral width of knee joint space. No statistically significant difference between right and left joint space width compartments is seen. There is no statistically significant difference between the genders.

CONFLICT OF INTEREST

None

SOURCES OF FUNDING

None

REFERENCES

1. Ryan S, Nicholas MM, Eustace S. The knee joint. In: Anatomy for Diagnostic Imaging. 2nd ed. London:Elsevier Limited;2004.p.286-9.
2. Butler P, Mitchell PWM, Ellis H. The knee Joint. In: Applied radiological Anatomy. 2nd Ed. Cambridge:Cambridge University Press;1999.p.363-6.
3. Anas I, Musa TA, Kabiru I, et al. Digital radiographic measurement of normal knee joint space in adults at Kano, Nigeria. *Egypt J Radiol Nucl Med.* 2013;44(2):253–8. <http://dx.doi.org/10.1016/j.ejrn.2013.03.005>
4. Messieh SS, Fowler PJ, Munro T. Anteroposterior radiographs of the osteoarthritic knee. *J Bone Joint Surg Br.* 1990;72-B(4):639–40. <http://dx.doi.org/10.1302/0301-620x.72b4.2380220>
5. Gaballah MF, Badawy ZH. Lower limb radiographic anatomy[Internet]. <http://www.medicine.cu.edu.eg/elearning/mod/resource/view.php?id=1190>
6. Mérida-Velasco JA, Sánchez-Montesinos I, Espín-Ferra J, Rodríguez-Vázquez JF, Mérida-Velasco JR, Jiménez-Collado J. Development of the human knee joint. *Anat Rec.* 1997;248(2):269–78. [http://dx.doi.org/10.1002/\(SICI\)10970185\(199706\)248:2<269::AID-AR14>3.0.CO;2-N](http://dx.doi.org/10.1002/(SICI)10970185(199706)248:2<269::AID-AR14>3.0.CO;2-N)
7. Ogunlade SO, Alonge TO, Omololu AB, Adekolujo OS. Clinical spectrum of large joint osteoarthritis in Ibadan, Nigeria. *Eur J Res.* 2005;11:116-22.
8. Rida-Velasco JAM, Sa' Nchez-Montesinos I, Espi'N-Ferra J et. al Development of the Human Knee Joint. *Anat. Rec.* 1997; 248:269-78. <https://dissertation.npmcn.edu.ng/index.php/FMCR/article/download/1657/215/>
9. Chan WP, Lang P, Stevens MP, et al. Osteoarthritis of the knee: comparison of radiography, CT, and MR imaging to assess extent and severity.*Am J Roentgenol.* 1991;157(4):799–806. <http://dx.doi.org/10.2214/ajr.157.4.1892040>
10. Colebatch AN, Hart DJ, Zhai G, Williams FM, Spector TD, Arden NK. Effective measurement of knee alignment using AP knee radiographs. *Knee.* 2009;16(1):42–5. <http://dx.doi.org/10.1016/j.knee.2008.07.007>
11. Duren DL, Sherwood RJ, Chumlea WC, Siervogel RM, Towne B. Radiographic joint space of the knee in healthy young adults. *Hum Biol.* 2006;78(3):353–64. <http://dx.doi.org/10.1353/hub.2006.0042>
12. Felson DT, McAlindon TE, Anderson JJ, et al. Defining radiographic osteoarthritis for the whole knee. *Osteoarthritis Cartilage.* 1997;5(4):241–50. [https://doi.org/10.1016/s1063-4584\(97\)80020-9](https://doi.org/10.1016/s1063-4584(97)80020-9)
13. Dacre JE, Scott DL, da Silva JAP, Welsh G, Huskisson EC. Joint space in radiologically normal knees. *Rheumatology.*1991;30(6):426–8. <http://dx.doi.org/10.1093/rheumatology/30.6.426>
14. Mason RB, Horne JG. The posteroanterior 45° flexion weight-bearing radiograph of the knee. *J Arthroplasty.* 1995;10(6):790–2. [http://dx.doi.org/10.1016/s0883-5403\(05\)80076-2](http://dx.doi.org/10.1016/s0883-5403(05)80076-2)
15. Ravaut P, Auleley G-R, Chastang C, et al. Knee joint space width measurement: An experimental study of the influence of radiographic procedure and joint positioning.

- Rheumatology*. 1996;35(8):761–6. <http://dx.doi.org/10.1093/rheumatology/35.8.761>
16. Le Graverand M-PH, Vignon EP, Brandt KD, et al. Head-to-head comparison of the Lyon Schuss and fixed flexion radiographic techniques. Long-term reproducibility in normal knees and sensitivity to change in osteoarthritic knees. *Ann Rheum Dis*. 2008;67(11):1562–6. <http://dx.doi.org/10.1136/ard.2007.077834>
17. Bruyère O, Henrotin YE, Honoré A, et al. Impact of the joint space width measurement method on the design of knee osteoarthritis studies. *Aging Clin Exp Res*. 2003;15(2):136–41. <http://dx.doi.org/10.1007/bf03324491>
18. Buckland-Wright JC, Macfarlane DG, Williams SA, Ward RJ. Accuracy and precision of joint space width measurements in standard and macroradiographs of osteoarthritic knees. *Ann Rheum Dis*. 1995;54(11):872–80. <http://dx.doi.org/10.1136/ard.54.11.872>
19. Deep K, Norris M, Smart C, Senior C. Radiographic measurement of joint space height in non-osteoarthritic tibiofemoral joints: A comparison of weight-bearing extension and 30° flexion views. *J Bone Joint Surg Br*. 2003;85-B(7):980–2. <http://dx.doi.org/10.1302/0301-620x.85b7.13930>
20. Hilliquin P, Pessis E, Coste J, et al. Quantitative assessment of joint space width with an electronic caliper. *Osteoarthritis Cartilage*. 2002;10(7):542–6. <http://dx.doi.org/10.1053/joca.2002.0809>
21. Gensburger D, Arlot M, Sornay-Rendu E, Roux J-P, Delmas P. Radiologic assessment of age-related knee joint space changes in women: a 4-year longitudinal study. *Arthritis Rheum*. 2009;61(3):336–43. <http://dx.doi.org/10.1002/art.24342>
22. Beattie KA, Duryea J, Pui M, et al. Minimum joint space width and tibial cartilage morphology in the knees of healthy individuals: a cross-sectional study. *BMC Musculoskelet Disord*. 2008;9(1):119. <http://dx.doi.org/10.1186/1471-2474-9-119>
23. Jain RK, Jain A, Mahajan P. Radiographic evaluation of knee joint space width using fixed flexion view in knees of Indian adults. *Int J Res Orthop*. 2018;5(1):38. <http://dx.doi.org/10.18203/issn.2455-4510.intjresorthop20184730>