

# Implications of Ultrasonography in the Diagnosis and Management of Patients Presenting with Non-Traumatic Acute Abdominal Pain in a Tertiary Hospital of Mid-Western Region of Nepal

Ghimire P, Paudel N, Koirala D, Singh BP

Department of Radiology, Nepalgunj Medical College and Teaching Hospital, Kohalpur, Banke, Nepal

Received: November 10, 2017

Accepted: February 10, 2018

Published: December 30, 2018

## Cite this paper:

Ghimire P, Paudel N, Koirala D, Singh BP. Implications of ultrasonography in the diagnosis and management of patients presenting with non-traumatic acute abdominal pain in a tertiary hospital of mid-western region of Nepal. *Nepalese Journal of Radiology* 2018;8(12):30-34. <https://doi.org/10.3126/njr.v8i2.22980>

## ABSTRACT

**Introduction:** Acute abdomen is the most common condition for patients presenting in the emergency. Ultrasound among other imaging modalities is the most common diagnostic tool employed in the diagnosis of such cases.

**Methods:** A prospective study of consecutive patients presenting with acute abdomen fulfilling the inclusion and exclusion criteria were included in the study. Ultrasound was performed by single radiologist and findings were correlated to the clinical, pathological and surgical findings.

**Results:** A total of 248 patients fulfilled all criteria and were included in the study. The age of patients ranged from 15-62 years with mean age of 41.3 years. There was female predominance with a male to female ratio of 1:1.8. Ultrasound accurately diagnosed 233 cases (93.9 %). Urolithiasis was the most common finding (45.16%) followed by acute appendicitis (19.35%).

**Conclusion:** Ultrasound has pivotal role in the diagnosis and overall management of patient presenting with acute abdomen. Urolithiasis is the most common etiology for non-traumatic acute abdomen.

**Key words:** Abdomen, Acute; Abdominal Cavity; Emergencies

## INTRODUCTION

Acute abdomen is one of the most common cause for presentation of patient in the emergency department worldwide.<sup>1</sup> A delayed and incorrect diagnosis poses a significant morbidity and mortality among such patients. Imaging has gained immense role in diagnosis that influences the overall management of acute abdominal emergencies. Ultrasound

---

**Correspondence to:** Dr. Prasanna Ghimire  
Assistant Professor  
Department of Radiology  
Nepalgunj Medical College and Teaching  
Hospital, Kohalpur, Banke, Nepal  
Email: [drprasannaghimire@gmail.com](mailto:drprasannaghimire@gmail.com)



Licensed under CC BY 4.0 International License which permits use, distribution and reproduction in any medium, provided the original work is properly cited

have proved to have a significant role in the early diagnosis due to wide availability, lower cost, real time and can even be performed at bed side.<sup>2</sup> In our study, we studied spectrum of diseases and the significance of ultrasound in the diagnosis of non-traumatic abdominal emergencies.

## METHODS

All patients with age ranging from 15–62 years who presented in the Radiology department for non-traumatic abdominal pain during a 3 month- period from June 2017 to August 2017 were included in the study. Patients who had already had a prior ultrasound for the presenting complain were excluded from the study. Informed consent was taken from the patient or relative prior to the scan. All scan was performed on either ultrasound machine Logiq 6 (General electrics, USA) by a single radiologist with an experience of greater than 5 years in abdominal sonography. Ultrasound findings were noted and correlated to the final diagnosis based on surgical/ pathological / laboratory or follow up scans.

## RESULTS

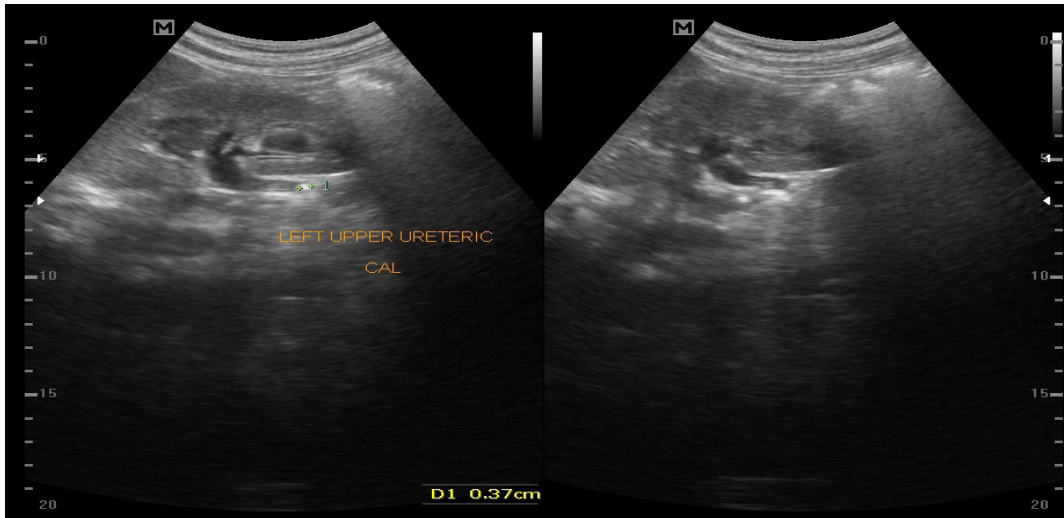
Among 320 patients, only 248 patients fulfilled all the inclusion and exclusion criteria. The age of the patients ranged from 15–62 years with mean age of 41.3 years. There was a female predominance with a male to female ratio of 90: 160 (1:1.8). Ultrasound correctly

diagnosed and correlated with the final diagnosis in 233 patients. The most common cause of abdominal pain was ureterolithiasis which was noted in 112 patients. Ultrasound correctly diagnosed 108 cases (96.4 %). Four patients who were diagnosed as normal due to the absence of initial hydroureteronephrosis but were diagnosed on computed tomography scan.

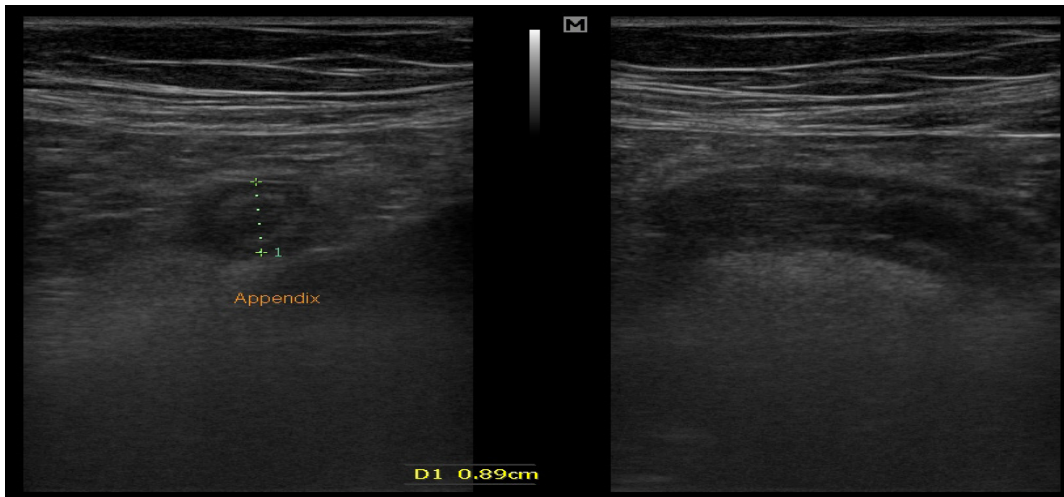
Appendicitis was the second most common cause of acute abdominal pain and was correctly diagnosed in all cases except two cases which were inconclusive for acute appendicitis due to non-visualization of appendix on ultrasound and were advised for computed tomography scan which confirmed the diagnosis. All two cases were female patients. Acute calculus cholecystitis was correctly diagnosed by ultrasound in all 29 cases. Acute pancreatitis was correctly diagnosed by ultrasound in five cases. Three cases were inconclusive due to limitation of gas. CT scan confirmed the diagnosis in those cases. Acute pelvic inflammatory disease (PID) was suggested by ultrasound in 2 cases which was confirmed by follow up scan and clinical resolution with treatment. Sigmoid volvulus could not be diagnosed by ultrasound due to hinderance from bowel gas. Mesenteric ischemia was mis-diagnosed by ultrasound in one case. Pneumoperitoneum was diagnosed by ultrasound however the site of hollow viscus perforation could not be delineated by ultrasound in 2 cases.

**Table 1: Frequencies of pathologies presenting as acute abdomen diagnosed in ultrasound**

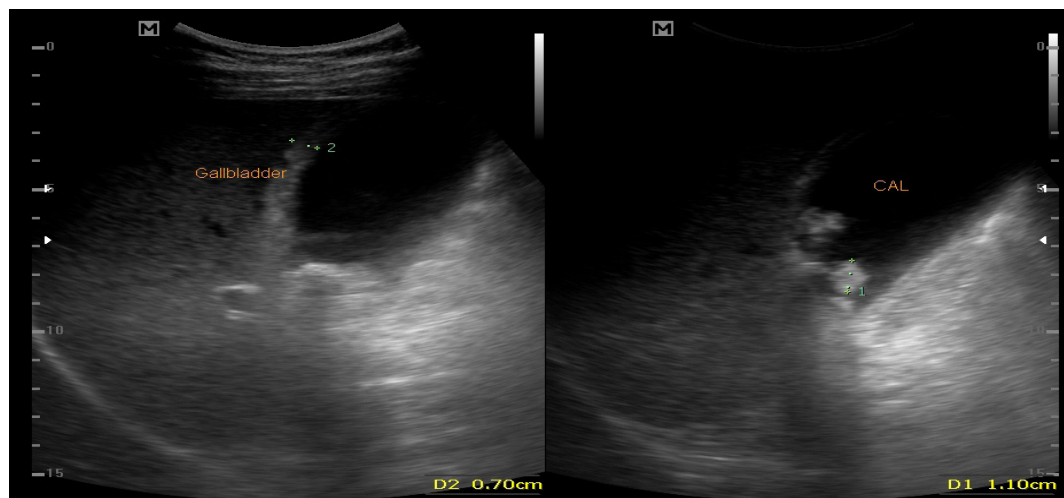
	Etiology	No of cases	Correctly diagnosed
1	Ureterolithiasis	112	108
2	Acute appendicitis	47	45
3	Acute calculus cholecystitis	29	29
4	Hemorrhagic ovarian cyst	18	17
5	Intestinal obstruction	11	10
6	Acute pancreatitis	8	5
7	Splenic abscess	2	2
6	Hollow viscus perforation	6	4
7	Sigmoid volvulus	2	1
8	Acute PID	2	2
9	Ovarian torsion	2	2
10	Intussusception	6	6
11	Sigmoid carcinoma	1	1
12	Mesenteric ischemia	1	0
13	Ruptured ectopic pregnancy	1	1
<b>TOTAL</b>		<b>248</b>	<b>233</b>



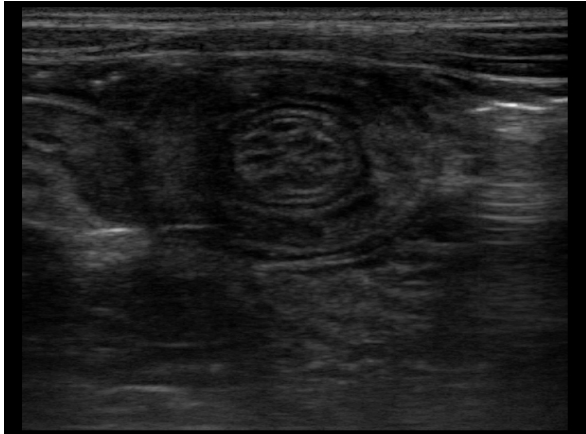*Figure 1: Ultrasound scan in a 20-year old male demonstrates left upper ueteric calculus with upstream mild hydronephrosis.*



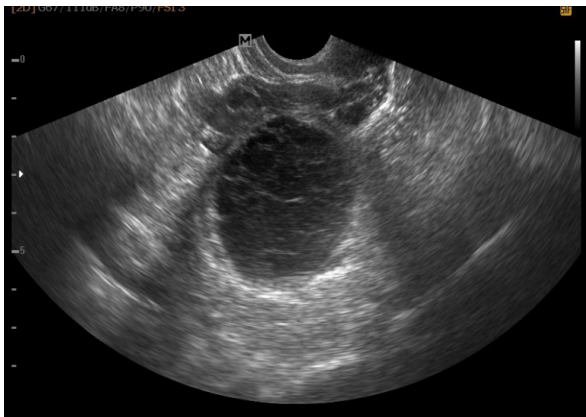
*Figure 2A and B: Ultrasound scan in a 23-year old female who presented with right lower quadrant pain demonstrates inflamed appendix in cross-sectional and longitudinally.*



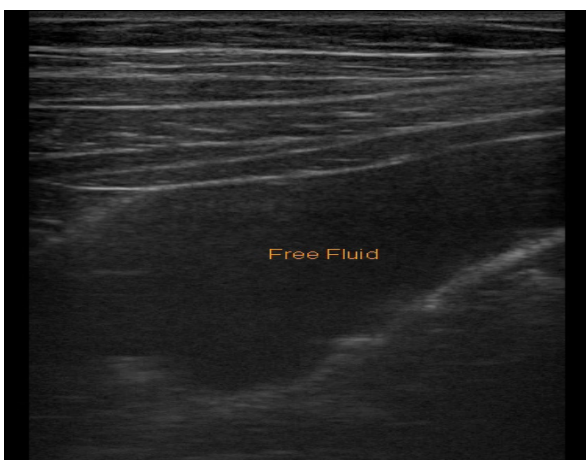
*Figure 3: Ultrasound scan in a 35-year old female demonstrates multiple calculi with thickened gallbladder wall.*



**Figure 4:** *Ultrasound scan in a 19-year-old male demonstrates invagination of one bowel loop into another forming telescopic appearance in a case of ileo-ileal intussusception.*



**Figure 5:** *Endovaginal ultrasound in a 25-year old female demonstrates a cystic lesion with reticular strands in a case of right ovarian hemorrhagic cyst.*



**Figure 6:** *Ultrasound in a 29-year old male demonstrates mild intraperitoneal collection in a case of hollow viscus perforation.*

## CONCLUSION

Ultrasound is the widely used initial imaging modality of choice for evaluation of patient presenting with non-traumatic acute abdomen.<sup>2,3</sup> Its wide availability, low cost has made it imperative in point of care of acute abdominal emergencies. Moreover, due to no radiation hazards, it had gained importance in the pregnant ladies and children. An accurate diagnosis by ultrasound is thus critical in the overall management of such cases.

In our study, ultrasound correctly diagnosed 233 patients out of 248 patients (93.9 %). The most common cause for an ultrasound in acute abdomen in our study was ureterolithiasis which accounted to 45.16 % of cases. This was significantly higher than most of the studies performed elsewhere. This regional differences may be attributable to the environmental as well local dietary habits.<sup>4</sup> Ultrasound was found to have increased sensitivity and specificity in the diagnosis of ureterolithiasis. However, various studies have shown absence of initial hydronephrosis can make diagnosis difficult or misleading as was noted in four patient in our study.<sup>5,6</sup> Acute appendicitis is considered the most common cause of acute abdomen worldwide.<sup>7,8</sup> In our study, acute appendicitis was the second most common cause of acute abdomen account for 47 of 248 patients (19.35 %) which was significantly lower than other similar studies. Ultrasound was inconclusive in two cases which were confirmed by other imaging techniques as computed tomography in our study.<sup>9</sup> Various studies have illustrated the limitations of ultrasound in the diagnosis of acute appendicitis due to factors as presence of intraabdominal gas, retrocaecal appendix, and obesity as well as other co-morbid factors.<sup>9</sup>

Ultrasound unlike other cross-sectional imaging techniques is operator dependent.<sup>10</sup> In our study, ultrasound was performed by a single radiologist with experience of more than 5 years in body imaging. This may have



an impact in the greater number of cases being diagnosed correctly by ultrasound compared various studies which have been performed by emergency physicians or radiology resident on training.<sup>11</sup> In conclusion, our study shows that although it has few limitations, ultrasound is an indispensable tool in a resource limited setting for the diagnosis of acute abdomen at the bed side substantially influencing the overall management.

## CONFLICT OF INTEREST

None

## SOURCES OF FUNDING

None

## REFERENCES

1. Cervellin G, Mora R, Ticinesi A et al. Epidemiology and outcomes of acute abdominal pain in a large urban Emergency Department: retrospective analysis of 5,340 cases. *Ann Transl Med* 2016;4(19):362. <https://doi.org/10.21037/atm.2016.09.10>
2. Mazzei MA, Guerrini S, Squitieri NC et al. The role of US examination in the management of acute abdomen. *Critical Ultrasound Journal* 2013 1;5(S1):S6. <https://doi.org/10.1186/2036-7902-5-S1-S6>
3. Sharma P, Singh B, Singh D, Gupta A. Comparative Study between Plain Radiography and Ultrasound Abdomen in Non Traumatic Surgical Acute Abdominal Conditions. *Nepalese Journal of Radiology* 2013;2(2):20-27. <https://doi.org/10.3126/njr.v2i2.7681>
4. Pandeya A, Prajapati R, Panta P, Regmi A. Assessment of kidney stone and prevalence of its chemical compositions. *Nepal Med Coll J* 2010;12(3):190-192. Available from: <https://pdfs.semanticscholar.org/fb26/e42a7385d855265247ef63033bf333ebef47.pdf> [Accessed 20th December 2018]
5. Tiselius HG. Epidemiology and medical management of stone disease. *BJU Int* 2003;91(8):758-767. <https://doi.org/10.1046/j.1464-410X.2003.04208.x>
6. Ripolles T, Agramunt M, Errando J, Martinez MJ, Coronel B, Morales M. Suspected ureteral colic: plain film and sonography vs unenhanced helical CT. A prospective study in 66 patients. *Eur Radiol* 2004;14(1):129-136. <https://doi.org/10.1007/s00330-003-1924-6>
7. Almstrom M, Svensson JF, Svenningsson A, Hagel E, Wester T. Population-based cohort study on the epidemiology of acute appendicitis in children in Sweden in 1987-2013. *BJS Open* 2018;2(3):142-150. <https://doi.org/10.1002/bjs5.52>
8. Fagerstrom A, Miettinen P, Valtola et al. Long-term outcome of patients with acute non-specific abdominal pain compared to acute appendicitis: prospective symptom audit after two decades. *Acta Chir Belg* 2014;114(1):46-51. <https://doi.org/10.1080/00015458.2014.11680976>
9. Tomizawa M, Shinozaki F, Hasegawa R et al. Abdominal ultrasonography for patients with abdominal pain as a first-line diagnostic imaging modality. *Exp Ther Med* 2017;13(5):1932-1936. <https://doi.org/10.3892/etm.2017.4209>
10. Lee JH, Jeong YK, Park KB, Park JK, Jeong AK, Hwang JC. Operator-dependent techniques for graded compression sonography to detect the appendix and diagnose acute appendicitis. *Am J Roentgenol* 2005;184(1):91-97. <https://doi.org/10.2214/ajr.184.1.01840091>
11. Unluer EE, Yavasi O, Eroglu O, Yilmaz C, AkarcaFK. Ultrasonography by emergency medicine and radiology residents for the diagnosis of small bowel obstruction. *Eur J Emerg Med* 2010;17(5):260-267. <https://doi.org/10.1097/MEJ.0b013e328336c736>