

## Role of Ultrasound in Determining the Nature of Pleural Effusion

Agarwal N<sup>1</sup>, Kansal HM<sup>2</sup>, Bhargava SK<sup>1</sup>

<sup>1</sup>Department of Radiology, <sup>2</sup>Department of TB and Chest Diseases, School of Medical Sciences and Research, Sharda University, Greater Noida. UP- 201306, INDIA

### Abstract

**Purpose of the study:** The differentiation of pleural effusion into transudate and exudate may affect the diagnostic approach and patients' management. The conventional Light criteria require both pleural fluid and blood samples along with three biochemical tests. This study was undertaken to assess the usefulness of ultrasound as an alternative in differentiating the type of pleural effusion. **Method:** A prospective cross sectional study was conducted over a period of one year. Eighty patients clinically diagnosed to have pleural effusion underwent high frequency ultrasound and also lab tests for Light criteria. The efficacy of ultrasound was then assessed in differentiating transudate from exudate. **Results:** It was concluded in our study that all pleural effusions which were echogenic on ultrasound, with or without septations or with pleural thickening more than 3 mm (n=46) were exudates (p< 0.01). The anechoic effusions on ultrasound could be transudates or exudates. **Conclusion:** Ultrasound acts as a useful non invasive alternative for determining the type of pleural effusion.

**Keywords:** Ultrasound, pleural effusion, exudates, transudate

### Introduction

Pleural effusions are classically divided into transudates and exudates.<sup>1</sup> A transudate is caused by systemic factors that influence the formation and absorption of pleural fluid, thus the pleural surfaces are not as such involved by the primary disease.<sup>2</sup> Increased plasma osmotic pressure or elevated systemic or pulmonary hydrostatic pressure are alterations that produce transudates.<sup>3</sup>

However, an exudate is caused by diseased pleural surfaces, such as occurs in tuberculosis, pneumonia, malignancy, pancreatitis, pulmonary infarction or connective tissue disorders.

Differentiation between a transudate and an exudate may affect the diagnostic approach and the patients' management.

The most commonly accepted criteria for differentiating exudates from transudates in pleural effusions was established by Light et al in 1972.<sup>4</sup> As per Light's criteria, pleural fluid is an exudate if one or more of the following criteria are met.

---

**Correspondence to:** Dr. Neema Agarwal, School of Medical Sciences and Research, Sharda University, Greater Noida. UP- 201306.

E-mail: [neemaagarwal@yahoo.com](mailto:neemaagarwal@yahoo.com)

1. Pleural fluid protein > 0.5
2. Pleural fluid LDH/ serum LDH > 0.6
3. Pleural fluid LDH more than two-thirds of the upper limit of normal LDH

Thus Light criteria requires both pleural and blood samples, and three biochemical measurements.

Alternatively, we investigated the usefulness of high frequency, real time sonography in determining the nature of pleural effusion.

### Materials and methods

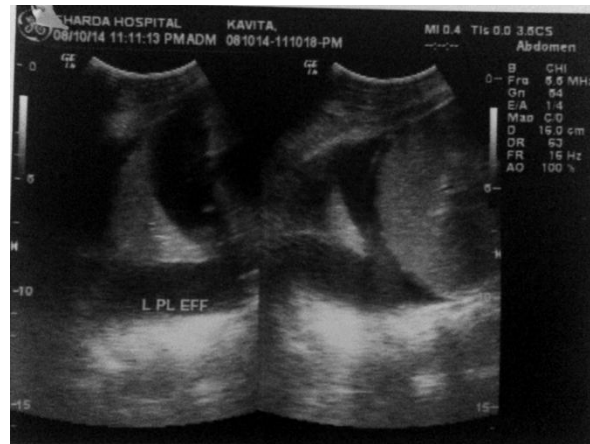
This prospective study was carried out by Department of TB and Chest Diseases and Department of Radiodiagnosis, Sharda Hospital, SMS & R, Greater Noida, India. Eighty adult patients of both sexes diagnosed to be having pleural effusion were included in this study. The study was conducted over a period of one year from April 2013- March 2014.

Patients without definite clinical diagnosis and patients previously diagnosed and on treatment were not included in the study.

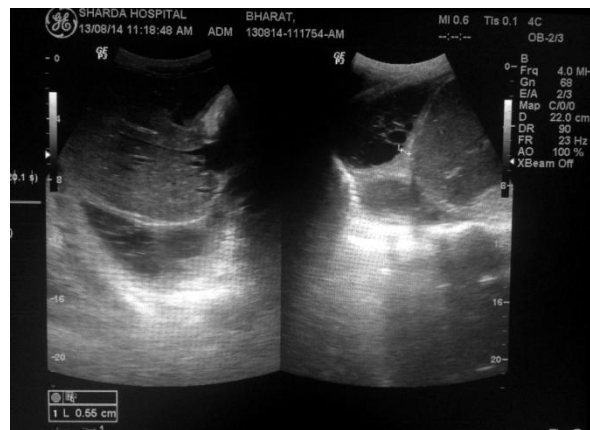Diagnostic tapping of the pleural fluid was done in every case. Blood samples were also taken of each patient. Samples from each patient were tested for pleural fluid protein, pleural fluid LDH and serum LDH in order to assess the Light's criteria. Protein was measured by the biuret method and LDH by UV spectro-photometry at 37 degree Celsius and 340 nm.

Further investigations, such as computed tomography of the chest, bronchoscopy, fine needle aspiration cytology, were also done to

determine the etiology of pleural effusion when needed.



**Fig.1: Anechoic pleural effusion as visualized on ultrasound.**



**Fig.2: Pleural effusion showing multiple septations and pleural thickening > 3mm.**

All patients were then examined with high resolution sonographic unit (GE Logiq 5 Pro) with 3.5-7.5 MHz linear and convex transducers. The radiologists had no clinical information concerning the patients and results were then compared with the lab results. Radiologists used three criteria to determine the nature of pleural effusion

1. Anechoic effusion,
2. Echogenic pleural effusion with or without septations,
3. Thickening of pleura more than 3 mm.

**Table 1:**

	<b>Transudate</b>	<b>Exudates</b>
<b>Lab results &amp; other tests</b>	<b>29</b>	<b>51</b>
<b>Ultrasound</b>	<b>34</b>	<b>46</b>

**Table 2:**

	<b>Anechoic</b>	<b>Echogenic</b>	<b>Pleural thickening</b>
<b>USG findings</b>	<b>34</b>	<b>41</b>	<b>5</b>

**Table 3:**

	<b>Anechoic (n=34)</b>	<b>Echogenic (n=41)</b>	<b>Pleural thickening (n=5)</b>
<b>Transudate (n=29)</b>	23	0	0
<b>Exudate (n=51)</b>	11	41	5

**Table 4:**

<b>On ultrasound:</b>	<b>Sensitivity</b>	<b>Specificity</b>
<b>Transudate</b>	<b>93</b>	<b>86</b>
<b>Exudate</b>	<b>86</b>	<b>93</b>

The echogenicity of the bile in gall bladder was used as a reference for defining the effusion as anechoic and echogenicity of liver was used as a reference for echogenic fluid.

Data was analysed by using chi-square test and a p-value of less than 0.05 was considered significant.

**Results**

The collected data showed that in lab results we had 29 transudate and 51 exudate and in ultrasound results we had 34 transudate and 46 exudate.

In our study, we found that out of 80 patients having pleural effusion, as per lab results and other investigations, 29 effusions were

finally diagnosed as transudate and 51 as exudate. (Table 1)

On ultrasound the conclusion drawn was that out of 80, 34 effusions were anechoic and so labelled as transudate and 46 showed either echogenicity or pleural thickening more than 3 mm, and thus labelled as exudates (Table 2). However, further analysis of data revealed that out of 34 anechoic effusions, 11 were exudates and were wrongly diagnosed as transudate on ultrasound.

So it was concluded in our study that all pleural effusions which were echogenic on ultrasound, with or without septations or with pleural thickening more than 3 mm (n=46) were exudates (p< 0.01).

The anechoic effusions on ultrasound could be transudate or exudate.

Further, the sensitivity and specificity of ultrasound in diagnosing transudative pleural effusion are 93% and 86% respectively. And, the sensitivity and specificity of ultrasound in diagnosing exudative pleural effusion are 86% and 93% respectively (Table 4).

### Discussion

The value of sonography for the detection of pleural effusions is well known. However, previous studies on the use of sonography to determine the nature of pleural effusion are limited and most of the reported studies were done with contact B scans and not with real time high resolution ultrasound systems.<sup>5,6</sup> Use of high frequency, real time, linear and convex transducers greatly improve the image resolution in the detection of type of pleural effusion.

The present study revealed that ultrasonography can be used to determine the nature of pleural effusion. Transudates are usually anechoic, whereas an anechoic effusion can be a transudate or an exudate. Pleural effusions with complex septated, complex non septated or homogeneously echogenic patterns are always exudates ( $p < 0.01$ ). An echogenic effusion may sometimes be confused with a solid lesion. However, if the lesion changes shape with respiration and tiny echoes can be seen swirling, then it is fluid.

### Conclusion

Ultrasound is non invasive, a readily available modality in hospitals, possible at patients' bedside and uses non ionizing radiation. It visualizes not just the pleural fluid, but also its nature and pleural nodules,

thickening or consolidation, if any, thereby aiding in reaching the diagnosis.

### References

1. Paddock FK. The diagnostic significance of serous fluids in disease. *N Engl J Med* 1940;223: 1010-1015
2. Stead WW, Sproul JM. Pleural effusion. *DM July*1964: 1-48
3. Agostoni E, Taglietti A, Setnikar. Absorption force of the capillaries of the visceral pleura in determination of the intrapleural pressure. *Am J Physiol* 1957; 191:277-282.
4. Light RW, Macgregor MI, Luchsinger PC, Ball Jr WC. Pleural effusions: the diagnostic separation of transudates and exudates. *Annals of Internal Medicine* 1972; 77(4):507-513.
5. Doust BD, Baum JK, Maklad NF, Doust VL. Ultrasound evaluation of pleural opacities. *Radiology* 1975;114:134-140
6. Laing FC, Filly RA. Problems in the application of ultrasonography for the evaluation of pleural opacities. *Radiology* 1978;126:211-214.