

# Imaging and Initial Management of Loin Pain in Pregnant Women in District General Hospital

**Kadi N**

Department of Education, North Cumbria University Hospitals, Carlisle, United Kingdom.

Loin pain in pregnancy has an incidence of one per 1500- 2500. The investigation of loin pain in pregnancy poses a difficult diagnostic as well as therapeutic dilemma. This article highlights the usual imaging modalities that are used to investigate loin pain and the initial management in pregnant women.

**Keywords:** imaging, loin pain, pregnancy.

## INTRODUCTION

Hydronephrosis in pregnancy can be physiological and may begin as early as the sixth week of gestation. Ninety percent of pregnant women will have some element of physiological hydronephrosis by the 28<sup>th</sup> week.<sup>1,2</sup> The mechanism of hydronephrosis is unclear, but it may be the result of a combination of pressure on the ureters at the pelvic brim and smooth muscle relaxation secondary to the hormonal changes of pregnancy.<sup>1,3</sup> Hydronephrosis is more common on the right, possibly because of dextrorotation of the uterus and the sigmoid colon cushioning the ureter on the left.<sup>1,3</sup> Most of the patients with hydronephrosis remain asymptomatic<sup>1</sup> and the hydronephrosis resolves post-delivery. However, a small percentage may complain of loin pain.<sup>1,4-11</sup> Moreover, up to 28% of cases of loin pain are misdiagnosed in pregnant women<sup>11</sup> because of common pregnancy symptoms such as vomiting, back pain and urinary frequency.

## ASSESSMENT

Assessment of patient with loin pain includes history and thorough clinical examinations. The initial investigations include blood tests to check white

cell count and differentiation, urea and electrolytes, urine dipstick, urine for culture and sensitivity, and requesting urgent renal imaging.

## Primary Imaging

Ultrasound scans are the preferred first line imaging modality in pregnancy, as they are non-invasive and they do not involve radiation. It is best to avoid ionising radiation in pregnancy, particularly during the first trimester when organogenesis takes place. However, ultrasound scans are operator dependent and sensitivity ranges from 34 to 92.5%.<sup>12-13</sup> Another useful radiological modalities is limited (three shot) intravenous urogram (IVU). It involves limited radiation exposure. Lead shielding of the pelvis is commonly used. A control film is taken followed by 15 and 30 or 60 min images post intravenous contrast administration.<sup>14-18</sup> Magnetic resonance imaging (MRI) is generally safe in pregnancy but it provides limited information about ureteric calculi.<sup>15,19</sup>

## Usual course of loin pain in pregnancy

Ninety percent of patients with loin pain will respond to intravenous fluids, prophylactic antibiotics and analgesia. These patients are usually monitored during pregnancy and the definitive therapy is usually planned postpartum.<sup>1-13,20-22</sup> Urgent urological

## CORRESPONDENCE

Dr Nourdin Kadi

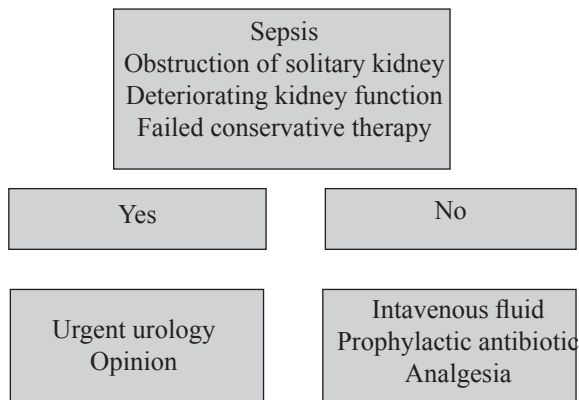
Department of Education,  
North Cumbria University Hospitals, Carlisle,  
Cumbria CA2 7HY, United Kingdom.

Email: [nourdin@hotmail.co.uk](mailto:nourdin@hotmail.co.uk)

Phone: 00447891892657

The papers in this journal are published under the terms of the Creative Commons Attribution License. Users are allowed to read, download, copy, distribute, print, search, or link to the full texts of the articles in this journal without asking prior permission from the publisher or the author.

opinion should be considered if patients have sepsis, intractable loin pain which is not controlled with analgesia (which mean failure of conservative therapy), patients who have obstruction of solitary kidney or if there is deteriorating renal function.<sup>1,6,9,15</sup>



**Figure 1. Algorithm of management of loin pain in pregnancy.**

### INTERVENTIONS

#### Percutaneous nephrostomy

Insertion of a percutaneous nephrostomy is a common method of interventions.<sup>6,23</sup> This procedure is usually performed under local anaesthesia with ultrasound guidance. This is especially useful in the presence of severe sepsis to avoid general anaesthesia.<sup>6,23,24</sup> The complications of nephrostomy are uncommon and include a 3% risk of tube dislodgement<sup>23-25</sup> and a 1.3 and 1.6% risk for major sepsis and haematuria respectively.<sup>26</sup> Periodic changes of the nephrostomy may be required prior to delivery (nephrostomy tube is at risk of encrustation and blockage during pregnancy due to elevated urinary sodium, uric acid and calcium concentrations).<sup>2,4</sup>

#### Cystoscopy

Cystoscopy and insertion of a retrograde ureteric stent is usually performed under general anaesthesia. This procedure can be performed with pelvic lead shielding and judicious use of fluoroscopy.<sup>6,14</sup> Ureteric stents are also at risk of encrustation and blockage during pregnancy.<sup>2,4</sup> Other disadvantages of this procedure include the risk of ascending pyelonephritis due to vesico-ureteric reflux and the lower urinary tract symptoms due to stent irritation.<sup>9,14,16,20-22</sup> Ureteric stent also might need to be changed periodically prior to delivery.

#### Primary ureteroscopy

There are published data of small series of patients treated by primary ureteroscopy.<sup>27-31</sup> Lithoclast and laser were used during ureteroscopy to treat ureteric calculi.<sup>27,31</sup> The risk of primary ureteroscopy in pregnancy include a 5% risk for minor abrasions,<sup>32,33</sup> 2% risk of perforation and creation of a false passage,<sup>32,33</sup> 1% risk of avulsion and stricture formation<sup>32,33</sup> and the risk of preterm labour and delivery. However, an experienced urologist should perform ureteroscopy with special interest in endoscopic surgery. Ureteroscopy is not recommended in the presence of sepsis or multiple calculi.<sup>6,8</sup> The choice of the investigations and interventions should be tailored to the individual patient's situation and discussed with the urologist and radiologist.

### CONCLUSIONS

In the absence of sepsis initial treatment in loin pain in pregnancy should be conservative, given that the majority of patients will recover with analgesia, antibiotics and hydration. Efforts should be made to minimise the radiation exposure of patient and fetus without delaying diagnosis or compromising early treatment. Intervention in loin pain in pregnancy should be considered in patients who have sepsis or a solitary kidney, symptoms refractory to conservative measures and worsening of renal function.

### REFERENCES

- Gulmi F, Felsen D, Vaughan ED. Pathophysiology of urinary tract obstruction. *Campbell's Urology*. 8th ed. Philadelphia: Saunders; 2002.
- Stables D. The Renal Tract. In: Cunningham FG, MacDonald PC, Gant NF, editors. *Physiology in childbearing with anatomy and related biosciences*. Edinburgh: Hauscent Publishing Limited; 2000. p. 236-46.
- Cunningham FG, MacDonald PC, Gant NF. Physiology of pregnancy: maternal adaptations to pregnancy. In: Cunningham FG, MacDonald PC, Gant NF, editors. *William's Obstetrics*. 20th ed. London: Prentice Hall International; 1999;2191-265.
- McAleer SJ, Loughlin KR. Nephrolithiasis and pregnancy. *Curr Opin Urol*. 2004;14(2):123-7.
- Biyani CS, Joyce AD. Urolithiasis in pregnancy I: pathophysiology, fetal considerations and diagnosis. *Br J Urol Int*. 2002;89(8):811-8.
- Biyani CS, Joyce AD. Urolithiasis in pregnancy II: management. *Br J Urol Int*. 2002;89(8):819-23.
- Lewis DF, Robichaux AG III, Jaekle RK, Marcum NG, Stedman CM. Urolithiasis in pregnancy: diagnosis, management and pregnancy outcome. *J Reprod Med*. 2003;48(1):28-32.

8. Butler EL, Cox SM, Eberts EG, Cunningham FG. Symptomatic nephrolithiasis complicating pregnancy. *Obstet Gynecol.* 2000;96:753-6.
9. Ferguson T, Bechtel W. Hydronephrosis of pregnancy. *Am Fam Physician.* 1991;43(6): 2135-7.
10. Meron M, editor. *Urinary lithiasis: aetiology, diagnosis and medical management.* Campbell's Urology. 8th ed. Philadelphia: Saunders; 2002.
11. Stothers L, Lee LM. Renal colic in pregnancy. *J Urol.* 1992;148(5):1383-7.
12. Enkin M, Keirse MJ, Neillson JP. *Infections in pregnancy: a guide to effective care in pregnancy and childbirth.* 3rd ed. Oxford: Oxford University Press; 2000.
13. Lingeman J, Lifshitz DA, Evan AP, editors. *Surgical management of urinary lithiasis.* Campbell's Urology. 8th ed. Philadelphia: Saunders; 2002.
14. Jarrard DJ, Gerber GS, Lyon ES. Management of acute ureteral obstruction in pregnancy utilizing ultrasound-guided placement of ureteral stents. *Urology.* 1993;42(3):263-7; discussion 267-8.
15. Murthy LN. Urinary tract obstruction during pregnancy: recent developments in imaging. *Br J Urol.* 1997; 80 (Suppl 1):1-3.
16. Hellawell GO, Cowan NC, Holt SJ, Mutch SJ. A radiation perspective for treating loin pain in pregnancy by double-pigtail stents. *Br J Urol Int.* 2002;90(9):801-8.
17. Irving SO, Burgess NA. Managing severe loin pain in pregnancy. *Int J Obstet Gynaecol.* 2002;109(9):1025-9.
18. ACOG Committee. Guidelines for diagnostic imaging during pregnancy. *Obstet Gynecol.* 2004;104(3):647-51.
19. Spencer JA, Chahal R, Kelly A, Taylor K, Eardley I, Lloyd SN. Evaluation of painful hydronephrosis in pregnancy: magnetic resonance urographic patterns in physiological dilatation versus calculous obstruction. *J Urol.* 2004;171(1):256-60.
20. Puskar D, Balagovic I, Filipovic A, Knezovic N, Kopjar M, Huis M, et al. Symptomatic physiologic hydronephrosis in pregnancy: incidence, complications and treatment. *Eur Urol.* 2001;39(3):260-3.
21. Fainaru O, Almog B, Gamzu R, Lessing JB, Kupferminc M. The management of symptomatic hydronephrosis in pregnancy. *Int J Obstet Gynaecol.* 2002;109(12):1385-7.
22. Zwergel T, Lindenmeir T, Wullich B. Management of acute hydronephrosis in pregnancy by ureteral stenting. *Eur Urol.* 1996;29(3):292-7.
23. Khoo L, Anson K, Patel U. Success and short-term complication rates of percutaneous nephrostomy during pregnancy. *J Vasc Interv Radiol.* 2004;15(12):1469-73.
24. Kavoussi LR, Albala DM, Basler JW, Apte S, Clayman RV. Percutaneous management of urolithiasis during pregnancy. *J Urol.* 1992;148:1069-71.
25. Peer A, Strauss S, Witz E, Manor H, Eidelman A. Use of percutaneous nephrostomy in hydronephrosis of pregnancy. *Eur J Radiol.* 1992;15(3):220-3.
26. Hausegger KA, Portugaller HR. Percutaneous nephrostomy and antegrade ureteral stenting: technique, indications, and complications. *Eur Radiol.* 2006;16(9):2016-30.
27. Akpınar H, Tufek I, Alici B, Kural AR. Ureteroscopy and holmium laser lithotripsy in pregnancy: stents must be used postoperatively. *J Endourol.* 2006;20(2):107-10.
28. Carringer M, Swartz R, Johansson JE. Management of ureteric calculi during pregnancy by ureteroscopy and laser lithotripsy. *Br J Urol.* 1996;77(1):17-20.
29. Lifshitz DA, Lingeman JE. Ureteroscopy as a first-line intervention for ureteral calculi in pregnancy. *J Endourol.* 2002;16(1):19-22.
30. Ulvik NM, Bakke A, Hoisaeter PA. Ureteroscopy in pregnancy. *J Urol.* 1995;154(5):1660-3.
31. Watterson JD, Girvan AR, Beiko DT, Nott L, Wollin TA, Razvi H, et al. Ureteroscopy and holmium: YAG laser lithotripsy: an emerging definitive management strategy for symptomatic ureteral calculi in pregnancy. *Urology.* 2002;60(3):383-7.
32. Carter SS, Cox R, Wickham JE. Complications associated with ureteroscopy. *Br J Urol.* 1986;58(6):625-8.
33. Johnson DB, Pearle MS. Complications of ureteroscopy. *Urol Clin North Am.* 2004;31(1):157-71.