

Correspondence

Dr Baburam Dixit Thapa
Department of Obstetrics
and Gynecology,
BPKIHS, Dharan, Nepal

Email:
baburamdixit@yahoo.com

Phone: +977-9842352481

Received: 5 Mar 2022
Accepted: 1 Dec 2022

Citation: Thapa BD,
Regmi MC. Late
presentation
of
vesicouterine
rupture
following vaginal birth
after caesarean. *Nep J
Obstet
Gynecol.*
2022;17(35):75-77. DOI:
<https://doi.org/10.3126/njog.v17i2.52381>

Late presentation of vesicouterine rupture following vaginal birth after caesarean

Baburam Dixit Thapa, Mohan Chandra Regmi
BPKIHS, Dharan, Nepal

ABSTRACT

Vesicouterine rupture is one of the complications of vaginal birth after cesarean section. Late presentation of bladder along with uterine rupture is rarely reported in literature. A case of vaginal birth after cesarean got admitted on seventh postpartum day due to hematuria and urinary retention. On Per abdominal examination bladder was palpable. A large defect was noted in the dome of bladder on cystoscopy. The posterior wall and fundus of uterus was acting as posterior wall of urinary bladder on laparotomy. Total hysterectomy was done and bladder was repaired.

Keywords: cystoscopy. hematuria. laparotomy. vesicouterine rupture

INTRODUCTION

For any woman who has undergone prior cesarean delivery, there are two choices about how to give birth again. She can have a scheduled cesarean delivery i.e. elective repeat cesarean delivery (ERCD) or trial of labor to achieve vaginal delivery i.e. vaginal birth after cesarean (VBAC).¹ One rare but serious risk with VBAC is that the cesarean scar on the *uterus* may rupture (break open) in about 0.7-0.9%.² Although a rupture of the uterus is rare, it is very serious and may harm both mother and *fetus*. Injury to the urinary tract along with uterine rupture is a known complication of VBAC but its incidence varies according to different studies.^{3,4} Usually patient with vesicouterine rupture present acutely during delivery or just after delivery with different signs and symptoms like postpartum hemorrhage, generalized peritonitis and hematuria.⁵ We present a case who didn't have any acute signs and symptoms of vesicouterine rupture, but presented after seven days of VBAC with hematuria and urinary retention.

CASE

A 28-year-old P₂L₂ who had VBAC seven days back presented to emergency room with complaints of abdominal distention and retention of urine. Her first child was delivered with lower segment cesarean section three years back for fetal distress which was uneventful. In this pregnancy, she presented to our labor room in the second stage of labor and underwent successful vaginal birth.

She had labor pain for last two hours only. She voided normally after delivery. Her intrapartum and postpartum period was uneventful and was discharged after 24 hours of delivery as per hospital protocol.

On 7th postpartum day, she presented in gynecology emergency with complain of abdominal distension and urinary retention. Her bowel habit was normal, and she did not have per vaginal bleeding. The bladder was palpable abdominally. Per speculum and per vaginal examination revealed normal findings. Foley catheterization was done and 400 ml of turbid urine containing mucus flakes was drained. Her hemoglobin was 10.2gm/dl, white blood count was 14000/mm³ and platelet count was 150,000/mm³. The urine routine and microscopy showed plenty of RBCs. The pelvic ultrasound showed normal findings. Foley was left in-situ, and she was started with intravenous antibiotics.

While she was on ward, intermittent hematuria was noted. Then, cystoscopy was performed keeping in mind the possibility of bladder rupture. Cystoscopy findings revealed a large defect in the dome of bladder with bladder full of mucus flakes. Both ureteric orifices were visualized and were draining normally. [Fig-1 and 2]

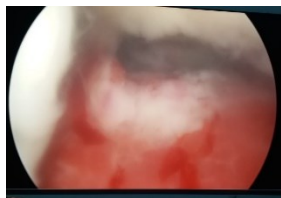


Figure-1: Defect in the fundus of

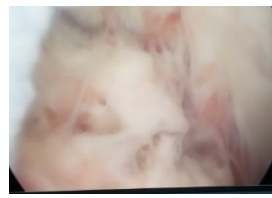

Figure-2: Bladder wall in cvstoscopy

Exploratory laparotomy was performed with midline incision. Per operatively, defect was noted in the dome of the bladder, anterior wall of the uterus was deficient, and the defect was covered with posterior wall and fundus of the uterus. Bladder trigone and

both ureteric orifices were normal. [Fig-3 and 4]

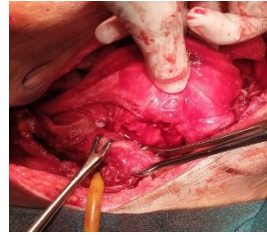


Figure-3: Bladder and uterus seen separately

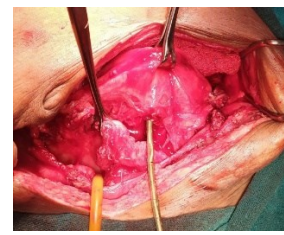


Figure-4: Bladder (defect in dome) and uterus (anterior wall)

Bladder and uterus were separated. The bladder defect was repaired. However, the defect in anterior wall of the uterus was not amenable to repair. Therefore, total abdominal hysterectomy was performed. Catheter was removed on 14th postoperative day and patient was discharged next day without any complaints.

DISCUSSION

The risk of uterine rupture after one previous lower segment cesarean in current pregnancy is about 0.7-0.9%.² Uterine rupture is an emergency condition with potentially fatal effects on mother and fetus. So, management of VBAC should be done in the center with the facility of continuous monitoring, blood transfusion, emergency cesarean with intensive care facility available to manage possible uterine rupture.⁶

The concomitant rupture of bladder along with uterine rupture is reported in 8-15% of cases of uterine rupture.^{3,4} Most of the reports suggest that clinical presentation of concomitant vesicouterine rupture are intrapartum or just after delivery. They may present like uterine rupture, non reassuring fetal heart rate, loss of presenting part, hematuria, abdominal pain or urinary incontinence.⁷ The late presentation of vesicouterine rupture like in our case is rarely reported in literature. Usually, the presentation of vesicouterine rupture is acute during intrapartum or immediate postpartum

period. Our patient and her baby were alright intrapartum and immediate postpartum as well. She did not have any complaints of pain abdomen, per vaginal bleeding, hematuria and abdominal distension.

There are various risk factors associated with uterine rupture. They may be classic uterine incision, interpregnancy interval of <18 months, use of prostaglandins, more than two previous cesarean sections and previous hysterotomy or myomectomy.^{8,9} The risk factor that can be postulated in our case is only precipitate labor. She had labor pain for only about two hours.

Ali MB et al⁵ had reported a case who had late presentation of uterine rupture after VBAC, who presented after 23 days postpartum with peritonitis, vaginal bleeding and palpable abdominal mass. In our case, patient with vesicouterine rupture presented with urinary retention, abdominal distension and intermittent hematuria.

In VBAC, uterine rupture along with bladder rupture usually occurs due to traumatic separation of dense adhesions between uterus and bladder during labor. Vesicouterine rupture needs laparotomy along with bladder repair and uterine repair or hysterectomy depending on nature of injury to the uterus.¹⁰

CONCLUSIONS

In patients with successful VBAC, bladder and uterine rupture should always be considered if they present with hematuria even when they do not have any signs and symptoms either intrapartum or immediate postpartum. Cystoscopy can be a good tool to diagnose bladder injury and do the management accordingly.

REFERENCES

1. Katz VL. Cesarean birth: guidelines, not rules. *Obstet Gynecol.* 2006;108(1):2-3. doi:10.1097/01.AOG.0000226428.00193.71.

2. Yap OWS, Kim ES, Laros RK. Maternal and neonatal outcomes after uterine rupture in labour. *Am J Obstet Gynecol.* 2001;184:1576-61.
3. Webb JC, Gilson G, Gordon L. Late second stage rupture of the uterus and bladder with vaginal birth after cesarean section: A case report and review of literature. *J Mat Fet Med.* 2000;9(6):1-3.
4. Klutkee JJ, Klutke CG. Simultaneous bladder and uterine rupture at the time of attempted vaginal birth after cesarean section. *Int Urogynecol.* 1992;3:83-6.
5. Ali MB, Ali MB. Late Presentation of Uterine Rupture: A Case Report. *Cureus.* 2019;11(10):e5950. PMID: 31799091. PMCID: PMC6863583. DOI: 10.7759/cureus.5950
6. Royal College of Obstetricians and Gynaecologists: Birth after previous caesarean birth (Green-top Guideline No. 45). (2015). Accessed: September 29, 2019: <https://www.rcog.org.uk/en/guidelines-research-services/guidelines/gtg45/>.
7. Jones RO, Nagashima AW, Hartnett-Goodman MM, Goodlin RC. Rupture of low transverse cesarean section scars during trial of labor. *Obstet Gynecol.* 1991;77:815-7.
8. Forsnes EV, Browning JE, Gherman RB. Bladder rupture associated with uterine rupture: a report of two cases occurring during vaginal birth after cesarean. *J Reprod Med.* 2000;45:240-2.
9. Lee JY, Cass AS. Spontaneous bladder and uterine rupture with attempted vaginal delivery after cesarean section. *J Urol.* 1992;147:691-2.
10. Ho SY, Chang SD, Liang CC. Simultaneous uterine and urinary bladder rupture in an otherwise successful vaginal birth after cesarean delivery. *J Chin Med Assoc.* 2010;73(12):655-9.