

Intrauterine Condom Tamponade in Management of Post Partum Hemorrhage

Joshi R,¹ Baral G¹

¹Paropakar Maternity and Women's Hospital, Kathmandu, Nepal

Received: 27-Jan-2017; Accepted: 20-May-2017

Aims: To analyze the outcome of intrauterine balloon tamponade using fluid filled latex condom attached to Foley's catheter (condom tamponade) in the management of postpartum hemorrhage.

Methods: This is a retrospective descriptive study of 29 women with postpartum hemorrhage unresponsive to pharmacological agents and managed with condom tamponade in Paropakar Maternity and Women's Hospital, Nepal from 13th February 2015 to 12th February 2016. Data were entered in Microsoft office excel (2007).

Results: Majority (n=20) of women were 20-29 years and 52% of them (n=15) were primipara. Seventy percent women (n=20) delivered at 37-40 weeks and vaginal delivery was the most common mode of delivery (72.41%, n=21). Sixty-two percent (n=18) had blood loss of <1000ml and condom tamponade was successful in 27 out of 29 women. One woman each needed internal iliac artery ligation and peri-partum hysterectomy.

Conclusions: Intrauterine condom tamponade is the effective method of arresting postpartum hemorrhage due to a wide variety of causes.

Keywords: Intrauterine condom tamponade, postpartum hemorrhage.

DOI: 10.3126/njog.v12i2.19944

INTRODUCTION

Maternal deaths due to pregnancy complications are unpredictable and unevenly distributed. Eleven to 17% occur around childbirth while 50-70% occurs in the postpartum period mostly in the first one week.¹ Obstetric hemorrhage is a significant contributor to the maternal morbidity and mortality.² It is one of the major direct causes of maternal deaths worldwide.^{1,2} Primary postpartum hemorrhage (PPH) is the most common form of major obstetric hemorrhage.^{2,3} The proportions of the maternal deaths depends upon the prompt and adequate management. It is more common in developing country like ours where it accounts for over one thirds of all maternal deaths.³⁻⁵

Atony of the uterus is the most common cause of the primary PPH.^{2,3} When the pharmacological measures fail to control the PPH due to atony, surgical hemostasis should be initiated as soon as possible. Uterine packing is now considered potentially traumatic and time consuming method which might not only conceal the ongoing hemorrhage but

also predispose to infections.⁵ Intrauterine balloon tamponade has been considered as the first line of surgical intervention to arrest the bleeding under such circumstance.² Some commonly used intrauterine balloon tamponades are hydrostatic Rusch balloon, Sengstaken-Blakemore esophageal catheter, Foley's catheter bulb, Bakri balloon and condom catheter.^{4,5} Many of these balloons are being used to control bleeding at other anatomical sites like urinary bladder, esophagus and to control problematic bleeding in conditions like cervical pregnancy, termination of pregnancy, cone biopsy, dysfunctional uterine bleeding.⁶ The male condom has been primarily used as a contraceptive device and in the prevention of sexually transmitted infections. However, another emerging use is as intrauterine balloon tamponade for managing postpartum hemorrhage. Various international and a few national case series have reported a success rate of balloon tamponade to be 71 to 100% in averting other invasive procedures and hysterectomy.³

The incidence of PPH in Paropakar Maternity and Women's Hospital (PMWH) was 1.7% in 2014/2015.⁷ This study was done to analyze the outcome of intrauterine tamponade using fluid filled condom attached to Foley's catheter (condom tamponade) in the management of PPH.

CORRESPONDENCE

Dr Rijuta Joshi (Jha)
Assistant Professor, MD (OBGYN), NAMS
Paropakar Maternity and Women's Hospital, Nepal
Phone No : +977-9851151830
Email : dr.rijutajoshi@jha@yahoo.com

METHODS

This is a retrospective descriptive study of 29 patients with postpartum hemorrhage unresponsive to pharmacological agents and managed with condom tamponade in PMWH, Nepal. The study period was from 13th February 2015 to 12th February 2016. The approval for the study was taken from the hospital ethical board. Only those cases with PPH where condom tamponade was used were abstracted for relevant maternal outcomes from the labor room and operation theatre record books. Clinical success of condom tamponade was defined as control of bleeding without need for further intervention. Data were entered in Microsoft office excel (2007) and results projected as graphs.

In all the cases active management of third stage of labour (administration of uterotonics, controlled cord traction and uterine massage) was done for prevention of primary PPH. The study included those cases who continued to bleed despite the use of pharmacologic measures like oxytocin, ergometrine, 15methyl analogue of prostaglandin F2 α (carboprost), prostaglandin E1 (misoprostol) and in which condom tamponade was used for the management of PPH. Genital tract trauma and retained placental tissues were ruled out/managed prior to the tamponade placement.

During the management of these cases, help was taken from the other health personnel on duty as needed and the procedure was performed under supervision. Patient and patient party were explained about the maternal condition. Verbal consent was taken for this procedure and informed written consent for possible need for other surgical interventions including hysterectomy was taken. "Condom tamponade sets" with all the required materials were available in labour room, birthing centre, operation theatre and Intensive Care Unit (ICU). Trans-vaginal insertions were done either in labour room or in operation theatre in lithotomy / dorsal position with proper light and adequate exposure. Sims speculum was used to expose the cervix. Under all aseptic and antiseptic precautions, the equipment was manually prepared by inserting the two latex male condoms over a 16 Fr Foley's catheter and tying it with a No.1 silk thread/ thick cotton thread at its distal end. The anterior and posterior lips of the cervix were grasped with sponge holder and the assembled catheter (Figure 1) was aseptically inserted into the uterine cavity under

direct vision by holding it with a sponge holder near to the tip. For cesarean delivery, the catheter was inserted through the uterine incision (pushing the tip to the fundus and the drainage port through the cervix into the vagina) or trans-vaginally and inflated after the uterine incision was closed. After catheter insertion, the condom was inflated with 350-500ml of warm sterile normal saline through Foley's catheter drainage port via the intravenous tubing set until the uterine fundus was firmly palpable or bleeding was controlled. The Foley's catheter draining port was then clamped with two plastic cord clamps and fundal height was marked and recorded. Vaginal packs (sterile gauze pads) were kept to retain the balloon tamponade inside the uterine cavity and oxytocin intravenous drip was continued. Failed catheter placement was defined as either the inability of the operator to insert the catheter inside the uterine cavity or the inability to inflate the balloon after intrauterine insertion. Failure of balloon tamponade was defined as the persistence of uterine bleeding after creation of tamponade with the need for additional procedures to stop the bleeding (negative "tamponade test"). The procedure was considered successful (positive "tamponade test") if bleeding stopped with the balloon inflation and creation of tamponade. In case of negative "tamponade test", laparotomy and other surgical interventions were carried out. When the "tamponade test" was positive, the patient was shifted to the ICU and condition monitored continuously (Figure 2). Periodic assessments for increase in fundal height and per vaginal bleeding were done as needed. Broad-spectrum antibiotics were administered until removal of the condom tamponade. It was continued as recommended for maximum of 24 hours. Balloons were deflated gradually under observations with the running oxytocin drip in the morning hours when senior consultant were present. Monitoring was done for per vaginal bleeding. If there was no bleeding for half an hour, the condom catheter was removed and oxytocin drip stopped.

RESULTS

At the time of the study, there were 17,696 deliveries and 266 women (1.5%) had PPH. Condom tamponade was used in total of 32 cases, 29 cases for PPH (24 for primary PPH and five for secondary PPH) and three cases (not included in further analysis) for intractable bleeding during evacuation of the incomplete abortions. In all the attempted cases,

there were successful placements of the condom tamponade. The “tamponade test” was positive in majority of the cases (27/29). It was negative in two cases, one case of LSCS with placenta increta (which needed additional measure of right internal iliac artery ligation) and next case of LSCS for breech presentation with cord prolapse (where re-laprotomy was done with B-lynch suture application followed by peripartum hysterectomy) (Figure 3).



Figure 1. Assembled Condom Tamponade

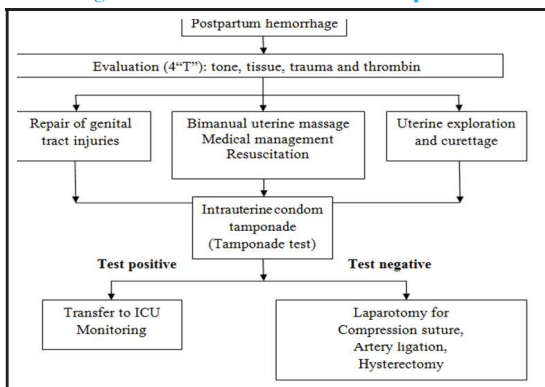


Figure 2. Procedural Framework

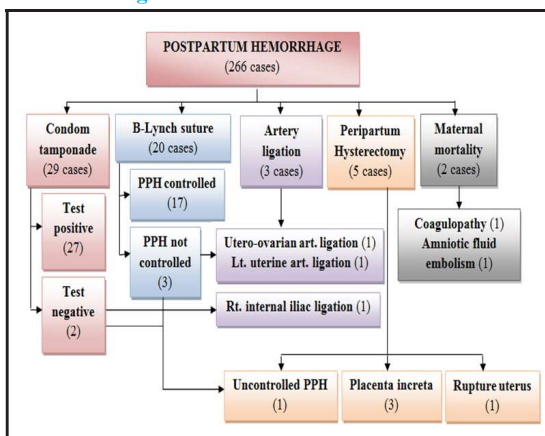


Figure 3. Flowchart showing the surgical management and outcome of PPH

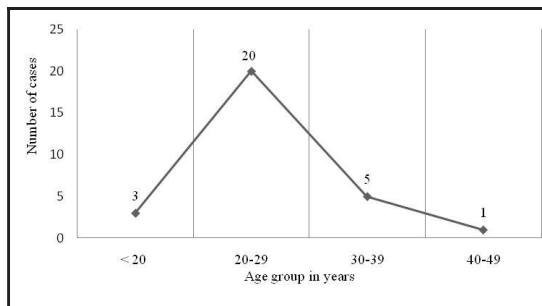


Figure 4. Age wise distribution

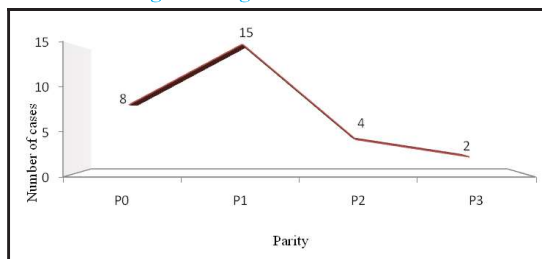


Figure 5. Parity wise distribution

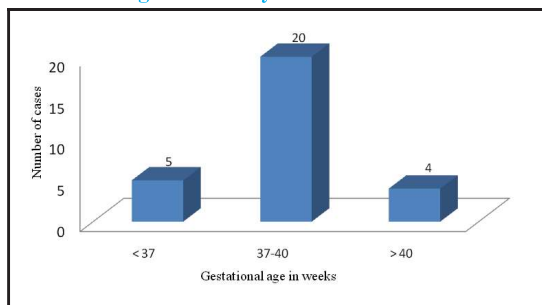


Figure 6. Distribution of cases according to period of gestation

Majority (n=20) of women in this study belonged to 20-29 years with the mean age of 24.7 years (Figure 4). Parity ranged from 0 to 3 and 52% of them (n=15) were primipara (Figure 5). The gestational age at delivery was from 32 to 42 weeks and 70% of the women (n=20) delivered at 37 to 40 weeks (Figure 6). In this study, 72.41% (n=21) of women had vaginal delivery including four instrumental deliveries (three forceps and one vacuum delivery) while only 27.5% (n=8) underwent LSCS. Among the women who had primary PPH, majority (n=18) had vaginal deliveries (Figure 7). The major etiology for PPH was atony of the uterus (n=16). Among the 10 cases which had retained tissues, six cases had retained placenta for which intrauterine balloon tamponade was kept after manual removal of placenta. There was a single case each for placenta increta, inversion of uterus and coagulopathy in which intrauterine balloon tamponade was used (Figure 8). Blood loss

after delivery ranged from 500 to 4200ml. In women with vaginal delivery with PPH who needed condom tamponade, majority (n=15) had minor PPH (<1000 ml). Among the women who underwent LSCS, three women each had mild (<1000 ml) and moderate PPH (1000-2000ml) while two women had severe (>2000 ml) PPH (Figure 9).

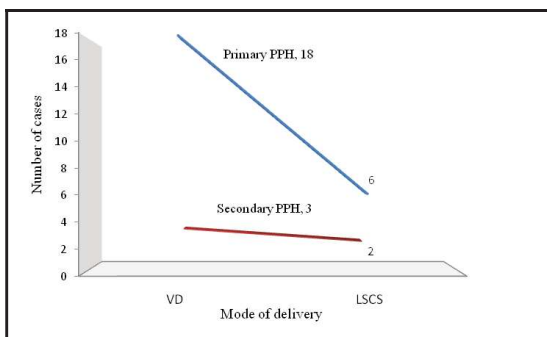


Figure 7. Distribution of cases according to mode of delivery

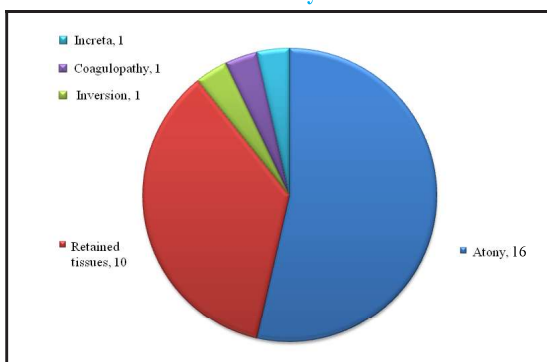


Figure 8. Etiology of PPH

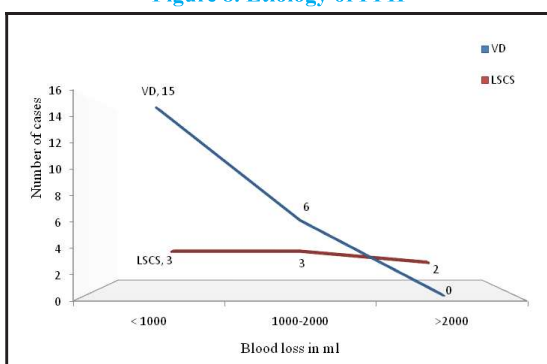


Figure 9. Distribution of cases according to blood loss

DISCUSSION

Primary PPH is blood loss of ≥ 500 ml within 24 hours after birth and any abnormal or excessive bleeding from the birth canal occurring between 24 hours and 6-12 weeks postnatal is secondary

PPH.^{3,5} Blood loss of 500-1000ml is termed as minor PPH while >1000ml is major PPH which is further divided into moderate (up to 2000ml) and severe PPH (>2000ml).² As the clinical estimation of blood loss is always underestimated, when there is transfusion of five or more units of blood or prophylaxis or treatment of coagulopathy (FFP, PRP) it is also termed as major PPH.^{2,5} The risk of dying from PPH depends not only upon the amount of blood loss but more in the blood volume and underlying health factors of the women.⁵ Various risk factors like grand multiparity, anemia, coagulopathy, operative vaginal delivery, cesarean section have been attributed to PPH.⁴ However, some of the women (20%) who have PPH do not have any identifiable clinical risk factors.³⁻⁵ PPH may result from failure of the uterus to contract adequately (inadequate tone: 70%), genital tract trauma / inversion / rupture of uterus (trauma: 20%), retained placental tissues / invasive placenta (tissue: 10%), or coagulopathies (thrombin:1%).^{3,4} Atony of the uterus is the main cause of primary PPH mortality worldwide.^{3,8} In secondary PPH also, atony is still the most likely cause of bleeding.⁴

The principle of using fluid filled intrauterine balloons is filling the uterine cavity in order to control the bleeding with pressure. Multiple hypothesis have been proposed for its tamponade effect: exerting inward-to-outward pressure ‘that is greater than the systemic arterial pressure’, hydrostatic pressure effect of the balloon on the uterine arteries and the release of natural prostaglandins by the intrauterine balloon tamponade.^{6,9} In a more recent study, the intra-luminal pressure within the tamponade balloon was not found to exceed the systolic blood pressure of the patient when the positive test was established.¹⁰

The various balloons used to create the intrauterine tamponade not only have various shapes but some have the drainage tip as well: Sengstaken-Blakemore esophageal catheter (SBOC), Foley’s catheter bulb and Bakri balloon. They vary in the price (SBOC-\$225 USD, Rusch ballon-\$32 USD, condom and catheter-19 cents US), material and have different recommended balloon capacities.^{6,11} There is no consensus about which of these balloons conform more to the shape of the uterine cavity and achieve a better haemostatic effect.⁶ However, these have not stopped their effective use as the intrauterine tamponade. The initial use of the condom tamponade in management of PPH was developed by Dr.

Sayeba Akhter, Bangladesh, 2001 and thus known as "Sayeba's method of PPH control".¹¹

The condom tamponade has certain advantages over other modalities: materials used are easily available and cheap, insertion is easy and rapid with minimal/no anesthesia, it can be performed by relatively inexperienced personnel, failed cases can be identified rapidly and removal is painless.⁵ Using this procedure as the clinical tool as "the diagnostic test", rapidly identifies women who need laparotomy and additional surgical measures.^{6,8} When positive, it also allows time for correction of any consumptive coagulopathy as well.⁸ The American College of Obstetricians and Gynecologists also suggests that "uterine tamponade can be effective in decreasing hemorrhage secondary to uterine atony and the procedure as uterine artery ligation or B-lynch suture may be used to obviate the need for hysterectomy".⁵ Uterine infection and latex allergy are contraindication to its use. There have been no immediate problems such as bleeding, sepsis or long term complications like menstrual problems or conception problem with this method.⁵

Compression sutures (brace sutures) for control of PPH are very useful when patient is stable and bimanual compression of the uterus successfully achieves the hemostasis.⁸ The advantage of this method over pelvic devascularization / hysterectomy is the ease of its application, no need for identification of specific blood vessels, less possibility of vessel injury and preservation of fertility. Need for laparotomy is the major disadvantage and pyometra, erosion through the uterine wall and uterine necrosis are its recognized complications.⁵ Uterine lacerations and necrosis are seen more often with the use of intrauterine balloon tamponade along with B-lynch sutures (attributed more to the B-lynch sutures).¹²

The success of pelvic devascularization is 40-100%.⁵ It needs a hemodynamically stable patient, laparotomy, substantial surgical expertise, and a desire to preserve fertility. There has been no impairment of subsequent fertility and pregnancy outcome with its use.² If it fails to control the bleeding, hysterectomy is required resulting in higher morbidity (compared to those patients undergoing hysterectomy without previous attempted arterial ligation). Although internal iliac artery ligation is very effective in arresting bleeding from all the sources of the genital tract, it can be technically challenging, time consuming and is associated with

a risk of injury to the surrounding structures like iliac vein and ureter.^{5,8} In a systematic review, the success rates for arresting the bleeding was 84% for balloon tamponade, 91.7% for compression sutures and 84.6% for pelvic devascularization.⁵ However, there was no statistically significant difference and it failed to show any of them were superior.

In PPH, hysterectomy is the final option which may be the only life-saving method at times when all other methods fail to control the bleeding. It has complications like urinary tract injuries, bowel injuries, vascular injury, pelvic hematoma, sepsis and fistula formation which occur as a result of the anatomical changes due to pregnancy and increased vascularity.⁵ Total or subtotal hysterectomy, both have significant psychological consequences to the women and her family along with the loss of child bearing potential. However, it should not be delayed if all the uterus conserving methods have failed.^{5,8}

The mean age of women (24.7 years) in this study is near to the study of Lohano et al¹² (26.4±4.2), Thapa et al¹⁴ (27.3 ± 6.6) and Akhter et al¹¹ (26.8) but lesser than of other studies (28.8-30 years).^{12,15} In other studies, similar to this study majority of women had parity of 0 to 3 and delivered at term.¹³⁻¹⁵ Vaginal delivery was the commonest mode of delivery (72.41%, n=21) in this study which correlates with other studies.^{11,13-15} In a study done by Kong and colleagues, delivery by cesarean section was common (12/19) and estimated intra-operative blood losses ranged from 1500-6320ml with median of 2000ml.¹⁶ Similarly in this study, severe PPH was more common in LSCS (>2000 ml: two in LSCS, none in vaginal delivery). Unlike in this study (500-4200ml), other studies had higher blood loss (1000-7000ml) with the mean blood loss of 1155.8±350.6 ml to 2695 ml.^{13,15,17} In all the cases of PPH, whole blood and fresh frozen plasma transfusions were done as required (range : four to 10 pints) depending upon the clinical condition of the patients and the blood loss. Atony of the uterus was the major cause for PPH in this study similar to other studies.^{12,15,17} In cases where retained tissues was the main cause of PPH, exploration of the uterus and removal of retained products of conception was carried out prior to balloon insertion. Higher incidence (40-47%) of coagulopathy was seen in some studies but in this study there was a single case of coagulopathy as the primary cause of PPH.^{16,17}

The intrauterine balloon tamponade was successful in 27 cases out of 29 cases (93.1%) which is near to study done by Lohano et al (126/140, 90%), Dabelea et al (18/20, 90%), and Panugthong et al (10/11, 90.9%).^{13,15,17} In some studies, it was 76 to 87% successful in preventing hysterectomy due to massive PPH.^{12,16} In a study done by Condous and colleagues, the “tamponade test” showed predictive value of greater than 87% for successful management of PPH and only two negative tests (12.5%) underwent surgery.¹⁸ In this study, there were no cases of re-bleeding after its removal similar to other studies.^{12,18} Over-inflating the balloon may not only cause significant pain to the women but there is a theoretical risk of uterine rupture or suture line breakage in case of cesarean section.⁶ Most of the women in the study had only mild pain abdomen (controlled with analgesics) and major complications due to the intrauterine tamponade were not seen which is comparable to other studies.^{11,16,19} A study had reported endomyometritis and massive secondary hemorrhage requiring hysterectomy after its use.¹²

The early use of intrauterine balloon tamponade has been found to allow time for resuscitation within “the golden hour” (the time at which the resuscitation must be started to ensure the best chance of survival), obtaining cross-matched blood, arrival of senior help, preparation/transfer for laparotomy and decreasing hemorrhage related mortality.^{5,6} In this study, condom tamponade was also used even in minor degree of PPH to aid in resuscitation and prevention of further blood loss with the aim to decrease the morbidity due to excessive blood loss. Its prophylactic use has been done successfully in some studies in anticipated cases with the identifiable risk factors of PPH.^{12,14}

An extensive systemic review of 13 studies (241 women) suggest that uterine balloon tamponade should be considered as an effective treatment for PPH in tertiary care and more so in a resource poor settings.

It is helpful in managing PPH secondary to a wide variety of causes like uterine atony, coagulopathy, retained placenta, placenta previa and placenta accreta.⁹ This method has been found to be equally effective in creating tamponade when the uterus is well contracted and there is ongoing hemorrhage from the placental bed as these devices exert uniform pressure over the open sinuses of the uterus controlling the bleeding immediately.^{11,20} During the study period, there were three successful insertion of condom tamponade to control hemorrhages after evacuation of incomplete abortions which is similar to studies of Akhter et al and Marcovici et al.^{11,21} However, further studies and randomized controlled trials are warranted to determine the ideal fluid volume for balloon inflation and duration of therapy. Insertion of condom tamponade is simple to learn and apply even without the surgical expertise. In a study, after a short structured training course, medical personnel with diverse clinical experience and operating at a wide range of facilities were easily and effectively able to apply the condom tamponade.²² Skilled birth attendants are successfully using the condom tamponade in management of PPH in various African countries and similar initiative has been started in Nepal as well.¹⁹

CONCLUSIONS

Intrauterine hydrostatic condom tamponade is the effective method of arresting PPH due to a wide variety of causes. Its early use aids in resuscitation, reduces total blood loss and hemorrhage related mortality. This simple cost-effective method with few contraindications not only has minimal adverse effects but preserves the reproductive capabilities of the women as well. It can be provided even by the primary health workers and could be a life saving procedure in management of PPH especially when surgical expertise is not readily available and during referrals to the equipped centre.

REFERENCES

1. World Health Organization. Attending to 136 million births, every year: make every mother and child count: chapter 4: risking death to give life. The World Health Report 2005. Geneva, Switzerland: WHO; 2005.
2. Royal College of Obstetricians and Gynecologists. Green-top Guideline No. 52. Prevention and management of postpartum haemorrhage. 2009.
3. World Health Organization. WHO guidelines for the management of postpartum hemorrhage and retained placenta. France: 2009.
4. Evensen A, Anderson J. Postpartum hemorrhage: third stage pregnancy. In: Advanced life support in obstetrics. 5th ed. Kansas. 2013;p.11-20.
5. Doumouchtsis SK, Arulkumaran. Postpartum hemorrhage: changing practices. In: Dunlop W, Ledger WL, editors. Recent advances in obstetrics and gynecology. No 24. UK. The Royal Society of Medicine Press; 2008.p.89-104.

6. Georgiou C. Balloon tamponade in the management of postpartum haemorrhage: a review. *BJOG*. 2009;116:748-75.
7. Paropakar Maternity and Women's Hospital. SMARIKA. Kathmandu: 2015;56:57.
8. Condous G, Bourne T. Post-partum uterine atony. In: Studd J, Tan SL, Chervenak FA, editors. *Progress in obstetrics and gynecology*. No 17. Churchill Livingstone; 2007.p.264-74.
9. Tindell K, Garfinkel R, Abu-Haydar E, Ahn R, Burke T, Conn K, et al. Uterine balloon tamponade for the treatment of postpartum hemorrhage in resource-poor settings: a systematic review. *BJOG*. 2013;120:5-14.
10. Georgiou C. Intraluminal pressure readings during the establishment of a positive 'tamponade test' in the management of postpartum hemorrhage. *BJOG*. 2010;117:295-303.
11. Akhter S, Begum MR, Rashid M, Laila TR, Zabeen F. Use of a condom tamponade to control massive postpartum hemorrhage. *Med Gen Med*. 2003;5(3):38.
12. S. Tirumuru, Saba S, Morsi H, Muammar B. *Open J Obstet Gynecol*. 2013;3:131-6.
13. Lohano R, Haq G, Kazi S, Sheikh S. Intrauterine balloon tamponade for the control of postpartum hemorrhage. *J Pak Med Assoc*. 2016;66:22-6.
14. Thapa K, Malla B, Pandey S, Amatya S. Intrauterine condom tamponade in management of post partum hemorrhage. *J Nepal Health Res Counc*. 2010;8(16):19-22.
15. Panugthong P. Management of intractable postpartum hemorrhage using condom tamponade. *KKMJ*.2012;45-9.
16. Kong MCZ, To WWK. Balloon tamponade for postpartum hemorrhage: case series and literature review. *Hong Kong Med J*. 2013;19:484-90.
17. Dabelea V, Schultze PM, McDuffie RS. Intrauterine balloon tamponade in management of postpartum hemorrhage. *Am J Perinat*. 2007;24(6):359-64.
18. Condous GS, Arulkumaran S, Symonds I, Chapman R, Sinha A, Razvi K. The "tamponade test" in the management of massive post partum hemorrhage. *Obest Gynaecol*. 2003;101(4):767-72.
19. Maya ET, Buntugu KA, Ako L, Srofenyoh EK. Condom tamponade in the management of primary postpartum hemorrhage: a report of three cases in Ghana. *Afr J Reprod Health*. 2015;19(3):151-7.
20. Frenzel D, Condous GS, Papageorghiou AT, McWhinney MA. The use of 'tamponade test' to stop massive haemorrhage in placenta accreta. *BJOG*. 2005;112:676-7.
21. Marcovici I, Scoccia B. Post partum hemorrhage and intra uterine balloon tamponade. *J Reprod Med*. 1999;44(2):122-6.
22. Pendleton AA, Natarajan A, Ahn R, Nelson BD, Eckardt MJ, Burke FTF et al. A qualitative assessment of the impact of a uterine balloon tamponade package on decisions regarding the role of emergency hysterectomy in women with uncontrolled postpartum hemorrhage in Kenya and Senegal. *BMJ*. 2016;6:e010083.