

# Minimally Invasive Surgery at Paropakar Maternity and Women's Hospital

Baral G<sup>1</sup>, Joshi R<sup>1</sup>

<sup>1</sup>Paropakar Maternity and Women's Hospital, Kathmandu

Received: 2-Dec-2017; Accepted: 30-Dec-2017

**Aims:** The purpose of this study is to review the reintroduced minimally invasive surgical practice in the hospital after a couple of decades long gap.

**Methods:** It is a two years (2015 to 2017) retrospective cross-sectional study carried out in Paropakar Maternity and Women's Hospital. The patients with pre-operative diagnosis of benign condition underwent laparoscopic surgery; hysteroscopy was diagnostic and operative both. Data were collected by demographics, indication of surgery, nature of surgery, complications, hospital stay and histo-pathological reports. Data were entered in the SPSS and MS-excel. Results were presented as tables and graphs.

**Results:** Sixty five and 39 women underwent laparoscopic surgery and hysteroscopy respectively. None of them had major complications and hospital stay was 1-3 days in majority. The most common age group was 31-35 years. Preoperative diagnoses of them were adnexal tumor in 47 women, fibroid uterus in six, AUB in two, ectopic pregnancies in four, PCOD in two and one woman each with primary sub-fertility and POP Q II with elongated cervix. Laparoscopic cystectomy was performed on 25 women for the adnexal masses while 13 women underwent laparoscopic oophorectomy for the ovarian masses. Total laparoscopic hysterectomy was the second commonest surgery (n=12). On histopathological examination of the ovarian tissues, mature cystic teratoma was the commonest finding (n=18) followed by the endometriotic cysts (n=9), benign serous cystadenoma (n=7) and mucinous cystadenoma (n=4).

**Conclusions:** Laparoscopy and hysteroscopy procedures have become the alternative in surgical modality at this hospital.

**Keywords:** hysteroscopy, laparoscopy, minimally invasive surgery.

DOI: 10.3126/njog.v12i2.19943

## INTRODUCTION

Minimally invasive surgeries (MIS) are carried out with the aid of an endoscope (a narrow telescope) through a small incision or without any incision.<sup>1</sup> In laparoscopy, an endoscope is introduced into the peritoneal cavity for visualization via umbilical port while other small ports are used for the introduction of the hand instruments.<sup>1,2</sup> In hysteroscopy, the endoscope is introduced intra-cervical for visualization of the interior of the uterus and tubal ostia.<sup>2</sup> In order to increase the operative space, pneumo-peritoneum is created with carbon-dioxide (CO<sub>2</sub>) or nitrous-oxide (N<sub>2</sub>O) in laparoscopy while distending medium as CO<sub>2</sub>, saline or glycine is used in hysteroscopy.<sup>1,2</sup> Today with the advancement in the technology, it is not only used for benign conditions but even for reconstructive as well as gynecologic cancers.<sup>3,4</sup> Hysteroscopy is not only used in treatment

of intrauterine pathologies, infertility, abnormal uterine bleeding, retained foreign bodies but also for insertion of the tubal occlusive devices.<sup>1</sup> With the invention of the flexible and smaller diameter hysteroscope, it is now associated with less intra-operative pain and has evolved to be an office procedure as well.<sup>1,2</sup>

MIS has become very popular among both patients as well as gynecologists due to its equivalent surgical outcome along with added benefits.<sup>1</sup> In comparison to the conventional surgeries, it has lesser post-operative pain, decreased hospital stay, faster recovery time, cosmetically better and decreased adhesion formation.<sup>1,3,4</sup>

MIS was commenced at Paropakar Maternity and Women's Hospital in 1971 AD. It was started with the diagnostic procedures followed by the tubal sterilization. This service has been delivered regularly since 2015 at the moment.

## METHODS

It was a retrospective cross-sectional study at Paropakar Maternity and Women's Hospital Kathmandu for two years from 2015 to 2017. The patients having

## CORRESPONDENCE

Dr Gehanath Baral  
Paropakar Maternity and Women's Hospital, Kathmandu  
Phone: +977-9841228829  
Email: gehanath@gmail.com

only benign conditions in pre-operative evaluation underwent laparoscopic surgery, and both diagnostic as well as therapeutic hysteroscopy procedures were included.

All laparoscopic surgeries were done under general anesthesia. Semi-lithotomy position was used. The primary port was made at lower margin of umbilicus for 30°-telescope with open technique. CO<sub>2</sub> was used to create pneumoperitoneum with the aid of the gas insufflator. Accessory ports (10 mm at right lower quadrant and two 5mm ports on left side umbilical and at right lower quadrant) were made under direct visualization and trans-illumination to avoid the epigastric vessels. Vaginal manipulators were used when indicated. Specimens were retrieved via the vaginal vault in cases of total laparoscopic hysterectomies. In rest of the cases, tissue retrieval was done with the aid of the tissue retrieval bag made out of the sterile surgical glove via 10mm port inserted on left iliac fossa. Specimens were sent for histo-pathological examination. Intravenous anaesthesia and rigid hysteroscope was used in all cases of hysteroscopy. Normal saline was used as the distending media in most of the cases and glycine in few cases. After the procedure, patients were kept in post-operative room for recovery.

Data were collected by demographics, indication of surgery, nature of surgery, complications, hospital stay and histo-pathological reports. Data were entered in the SPSS and MS-excel. Results were presented as tables and graphs.

## RESULTS

Total of 65 women had undergone laparoscopic surgery. They were from 19 to 60 years of age. Almost three fifth (41 out of 65) of them were of less than 35 years and peak age was at 31-35 years (Figure 1).

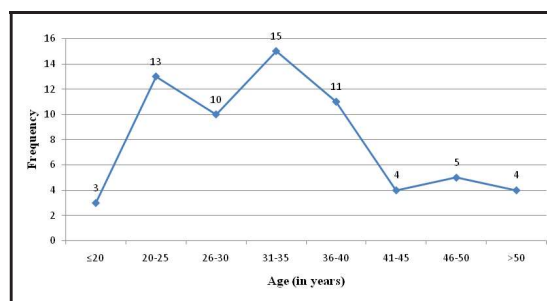


Figure 1. Age distribution

Majority (47/65) of the women had undergone laparoscopic surgery for the adnexal tumor.

Preoperative diagnoses of them were unspecified adnexal cyst in 23 women, dermoid cyst in 15 and endometrioma in eight and paraovarian cyst in one case. Fibroid uterus was the second commonest condition (n=6) for which five women underwent TLH and one underwent laparoscopic myomectomy. Two women with AUB refractory to medical management underwent TLH. For the five cases of suspected ectopic pregnancies, four underwent salpingectomy for the same diagnosis and one had negative finding. Laparoscopic ovarian drilling (4-5 drills in each ovary) was done for two cases of PCOD. For one woman each with primary sub-fertility, combined diagnostic laparoscopy-hysteroscopy was done and for the other woman with POP Q II with elongated cervix, TLH with vault suspension was done (Figure 2).

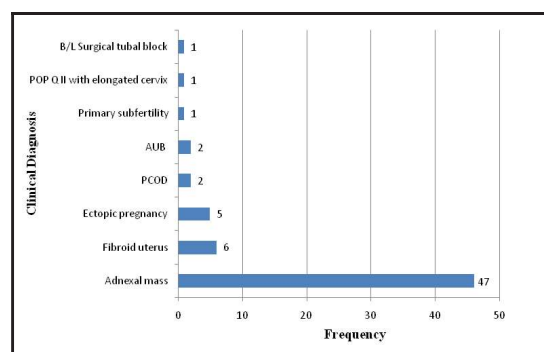
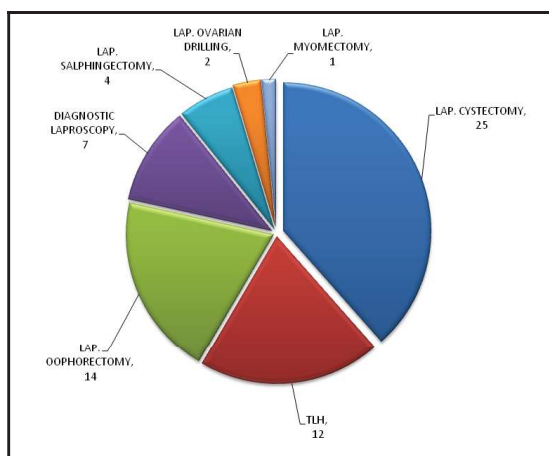


Figure 2. Distribution of Clinical Diagnosis

During the study period, laparoscopic cystectomy was performed on 25 women for the adnexal masses while 13 women underwent laparoscopic oophorectomy for the ovarian masses. Total laparoscopic hysterectomy was the second commonest surgery (n=12) which were done for fibroid uterus (n=4), abnormal uterine bleeding (n=2), dermoid cysts in over 45 years age women (n=5) and one case of POP Q II with elongated cervix. Diagnostic laparoscopy was performed in seven women, one case each of primary sub-fertility, bilateral surgical tubal block with suspected fimbriectomy (prior to re-canalization), pregnancy of unknown origin, suspected left adnexal cyst torsion, suspected uterine perforation, fibroid uterus with secondary sub-fertility and endometriosis (Figure 3).

On histopathological examination of the ovarian tissues, mature cystic teratoma was the commonest finding (n=18) followed by the endometriotic cysts (n=9), benign serous cystadenoma (n=7) and mucinous

cystadenoma (n=4). There were two cases of luteinized follicular cysts and one case each of epidermoid cyst, corpus luteal cyst and serous adenofibroma (with associated granulomatous salpingitis). Simple serous cyst was found on histopathology of the paraovarian cyst. Leiomyoma was present in seven cases and one case each of adenomyosis, adenomyosis with endometrial polyp and chronic cervicitis (POP-Q II with elongated cervix) were found in the uterine specimens. Tubal product of conception was seen in all four salpingectomy specimens of ectopic pregnancy.



**Figure 3. Laparoscopic procedures**

There were 39 women who underwent hysteroscopy. The commonest procedure was hysteroscopy guided endometrial biopsy (n=29) followed by polypectomy (n=4), Cu-T removal (n=4) and resection of submucous fibroid (n=2). On histopathology, none of the cases had malignancy.

## DISCUSSION

Even if we adopt minimally invasive surgery in our practice, at times we may have to convert or go back to open surgical procedure either because of the disease condition or due to inherent or procedural complication.

Two of the women required conversion to laparotomy for completion of the procedure- one for Cu-T induced uterine perforation and other due to marked adhesion at anterior abdominal wall. Complication varies in various regions and it ranges from 1/1000 to 12.5/1000 which depends largely on the complexity of the operations and experience of the surgeon.<sup>5</sup> Serious risks include injury to the bowel, bladder, uterus, ureter or major blood vessels but death due to complication is very rare in laparoscopy (3-8/100,000).<sup>1,6</sup> Shoulder

tip pain, wound bruising, wound infection and hernia at the site of entry are frequently encountered risks in laparoscopy.<sup>6</sup> Majority of the complications can be identified immediately and rectified while some appear in following days to weeks. In this study, none of them had major complications in intra-operative or in post-operative period. The most frequent minor complication was pain at wound site on the immediate post-operative period which was controlled with oral analgesics. Three of them had surgical emphysema which resolved on its own in few days. Three of the women had wound infection at the port site from where tissue retrieval was done. All of them were managed conservatively and one of them needed secondary suture at left 10mm port. Similar to this study, Nehzat et al did not have intra-operative or postoperative complications except umbilical port infection.<sup>7</sup>

Tissue retrieval via umbilical port have been advocated for shorter retrieval time, decreased post operative pain and improved cosmetically compared to the accessory port retrievals. Using accessory ports for tissue retrieval has been associated with slightly increased chances of the injury to the epigastric vessels and incisional hernia in later period.<sup>8</sup> However, in this study there was no any vessel injury.

Spillage of the cyst content have to be avoided especially in cases of malignancy or when malignancy cannot be ruled out preoperatively or intra-operatively with certainty.<sup>8</sup> Tissue retrieval bag made out of the sterile glove was used in all the cases to reduce or prevent the peritoneal spillage of the cyst contents. Inadvertent spillage of the contents of the cyst during laparoscopy requires copious lavage with warm fluid especially in cases of dermoid cysts to reduce the chemical peritonitis.<sup>8</sup> In cases of endometrioma, spillages of the contents are usually unavoidable even by standard surgical techniques which may lead to upstaging of the tumor if associated with it (which in itself is very rare).<sup>8</sup> In this study, copious irrigation was done when there was spillage of the contents and all the surgeries were carried out after ruling out the malignancy. In study done by Nehzat et al, there were no cases of chemical peritonitis even when the spillage rate was 42% (39/93) for the dermoid cysts.<sup>7</sup> In study done by Shawki et al, complication rates among spillage and non-spillage groups were not significant and size of the cyst did not have any impact on spillage rate.<sup>9</sup> Similar to this study other

studies used warm fluids for copious irrigation to suck out the spilled contents.<sup>7,9</sup>

In cases of endometrioma, oophorectomy was done when there was absence of the normal ovarian tissue while drainage of the endometrioma followed by stripping of the cyst wall was done in cases of presence of the normal ovarian tissue. Excision procedures are preferred over the ablative procedures because of improved pain relief, lesser recurrence and increased conception in cases of infertility.<sup>10</sup> In this study, stripping of the cyst wall was done when possible and excision with a rim of tissues were done in cases of dense adhesions. Both of these methods have been found to be equally good in tissue sparing and technical feasibility.<sup>11</sup>

In cases of polycystic ovarian disease with anovulation and infertility, laproscopic ovarian drilling (LOD) can be used as the second line therapy in women not responding to the clomiphene citrate (CC) or metformin therapy.<sup>12-14</sup> It is devoid of side effects of the hormonal therapy and causes less pelvic adhesions. However, it is an invasive procedure and the cost incurred could be one of the limiting factors.<sup>13</sup> The ovulation and pregnancy rates after LOD have been found to be favorable which is comparable to the CC and metformin.<sup>12,13</sup> In this study, two women with PCOD with infertility underwent LOD and tubal patency test. Although hysterosalpingography is considered the first line to detect the tubal factors of subfertility, diagnostic laparoscopy have the additional advantage of detecting the peritubal and periovarian adhesions as well as other associated pathologies like fibroids and endometriosis.<sup>15</sup> Chromotubation of the fallopian tubes during laparoscopy helps in direct visualization of the patency of the fallopian tubes during laparoscopy. In this study, tubal patency tests were performed by the Methylene-blue injected via the intra-cervical Foley catheter.

In a study done by Duggal and colleagues, laparoscopic management of the ectopic pregnancies was found to be safer and feasible. Although it was associated with longer operative time than open method (50-90 minutes vs. 50-65 minutes), the postoperative morbidity and hospital stay was shorter (2-3 vs. 7 days).<sup>16</sup> Similar findings were noted in other studies.<sup>17,18</sup> In this study, the women were admitted either on the same day or a day prior to the

procedure. Most of them were ambulating and taking orally on the same day of the procedure. The hospital stay for majority was 1-3 days and only four cases stayed for 5 days. Majority of them were discharged on the second or third post-operative day. Most of the women undergoing diagnostic procedures were discharged on the same day.

In total laparoscopic hysterectomies (TLH), the uterus and adnexal structures were delivered vaginally. In one nulliparous women with fibroid uterus, morcellation of fibroid was done transabdominally. The vaginal vault was sutured either transvaginally or transabdominally. In comparison to conventional total abdominal hysterectomy (TAH), TLH required more operating time (2-3 hours) however the hospital stays were lesser (2-3 days) without additional operative complications. Similar findings were seen in study done by Celik et al.<sup>19</sup> In another study done by Kulivers and colleagues, there was more post operative recovery and lesser complications following laparoscopic hysterectomies compared to the abdominal hysterectomies.<sup>20</sup>

Rigid hysteroscope and normal saline has been recommended for better view compared to the flexible hysteroscope and CO<sub>2</sub>.<sup>22</sup> However, constant infusion and higher flow rates of normal saline are needed for the proper distension of the uterine cavity which may lead to the fluid overload.<sup>23</sup> There is a potential risk of uterine perforation, fluid overload, gas embolism and hemorrhage during hysteroscopy.<sup>1</sup> There was no case of fluid overload in this study.

Laparoscopy has been found to be particularly advantageous in low and middle income countries like ours where there are limitations of hospital beds and sub-optimal support facility.<sup>23</sup> Lack of adequate trained personnel and equipments have been the main factor limiting its widespread use. However, inexpensive laboratory based trainers, reuse of disposable instruments and homemade tissue retrieval bag have aided in its services being available to the public hospitals as well.<sup>24</sup>

## CONCLUSIONS

Minimal invasive surgery has become an upgrade in surgical modality at this hospital. However procedural learning curve is yet to achieve by every service provider.

## REFERENCES

1. Minimally invasive surgery. In: Hoffman BL, Schorge JO, Schaffer JI, Halvorson LM, Bradshaw KD, Cunningham FG, Calver LE editors. *Williams Gynaecology*. 2nd ed. New York. Mc Graw Hill Medical; 2012.
2. Munro MG, Brill AI, Parker WH. *Gynecology Endoscopy*. In: Berek JS editor. *Berek & Novak's Gynecology*. 14th ed. Lippincott Williams & Wilkins; 2007.
3. Sharp HT, Francis SL, Murphy AA. *Te Linde's Operative Gynecology*. 10th ed. Lippincott Williams & Wilkins; 2008. Chapter 17; Diagnostic and Operative Laparoscopy. p.319-35.
4. Daniilidis A, Hatzis P, Pratilas G, Dinas K, Loufopoulos A. Laparoscopy in gynecology - how why when. In: Darwish A editor. *Advanced Gynecologic Endoscopy*. Intech; 2011. Available from: <http://www.intechopen.com/books/advanced-gynecologic-endoscopy/laparoscopy-in-gynecology-howwhy-when>.
5. RCOG. Preventing entry-related gynecological laparoscopic injuries. Green-top guideline No. 49; 2008.
6. RCOG. Diagnostic Laparoscopy. Consent Advice No. 2; 2008.
7. Nezhat CR, Kalyoncu S, Nezhat CH, Johnson E, Berlanda N, Nezhat F. Laparoscopic management of ovarian dermoid cysts: ten years' experience. *JSLs*. 1999;3:179-84.
8. RCOG/BSGE Joint Guideline I. Management of Suspected Ovarian Masses in Premenopausal Women. November. Green-top Guideline No. 62. 2011.
9. Shawki O, Soliman I, Ebrashy A, Sadek M, Bahnassy A. Laparoscopic management of ovarian dermoid cysts. *MEFSJ*. 2004;9(1):58-65.
10. Al Ebra NAA. Laparoscopic excision of endometrioma. *World J Lap Surg*. 2008;1(2):44-8.
11. Hema PL, Prathap T. Comparative study of two different techniques of laparoscopic stripping in ovarian endometrioma – a randomized control trial. *IJOGR*. 2016;3(2):95-100.
12. Jahan S, Habib SH, Khan MSH, Jahan A, Nayer R, Sharmin F et al. Comparative study between metformin and laparoscopic ovarian drilling for ovulation induction, achievement of pregnancy and live birth in Asian women with polycystic ovarian syndrome: a prospective trial. *OALibJ*. 2014;1: e645.
13. Hameed N, Ali MA. Laparoscopic ovarian drilling for polycystic ovarian syndrome: treatment outcome. *J Ayub Med Coll Abbottabad*. 2012;24(3-4):90-2.
14. Dudhat A. Laparoscopic ovarian drilling and its outcome. *Int J Collab Res Intern Med Public Health*. 2012;4(12):2075-81.
15. Shetty SK, Shetty H, Rai S. Laparoscopic evaluation of tubal factor in cases of infertility. *Int J Reprod Contracept Obstet Gynecol*. 2013;2:410-3.
16. Duggal BS, Tarneja P, Sharma RK, Rath SK, Wadhwa RD. Laparoscopic management of ectopic pregnancies. *Med J Armed Forces India*. 2004;60:220-3.
17. Shrestha J, Saha R. Comparison of laparoscopy and laparotomy in the surgical management of ectopic pregnancy. *J Coll Phy Surg Pak*. 2012;22(12):760-4.
18. Neupane BB, Karki GMS, Dahal P, Karki SB. Laparoscopic management of ectopic pregnancy at Birat Medical College and Teaching Hospital, Morang, Nepal. *BJHS*. 2017; 2(1):106-9.
19. Celik C, Abali R, Tasdemir N, Aksu E, Çalışkan H, Akkuş D. Total laparoscopic hysterectomy compared with abdominal hysterectomy; clinical outcomes. *J Clin Anal Med*. 2014;5(6):490-3.
20. Kluivers KB, Hendriks JCM, Mol BWJ, Bongers MY, Bremer GL, de Vet HCW, et al. Quality of life and surgical outcome after total laparoscopic hysterectomy versus total abdominal hysterectomy for benign disease: A randomized controlled trial. *J Minim Invasive Gynecol*. 2007;14:145–52.
21. RCOG. Best Practice in outpatient hysteroscopy. Green-top Guideline No. 59. 2011.
22. Baggish MS. *Te Linde's Operative Gynecology*. 10th ed. Chapter 18. Lippincott Williams and Wilkins. 2008. Operative Hysteroscopy; p.332-426.
23. Miller C, Hoan K, Minig L, Chuang L, Shahabi S. A review of minimally invasive gynecologic surgery in developing nations. *J Gynecol Women's Health*. 2017; 4(4): 555643.
24. Chao TE, Mandigo M, Opoku-Anane J, Maine R. Systematic review of laparoscopic surgery in low- and middle-income countries: benefits, challenges, and strategies. *Surg Endosc*. 2016;30:1.