

# A Clinicopathological Evaluation of 230 Cases of Mature Cystic Teratomas

Sherpa P<sup>1</sup>, Baral R<sup>2</sup>

<sup>1</sup>Lecturer, <sup>2</sup>Associate Professor, Patan Academy of Health Sciences.

**Received:** January 22, 2015 ; **Accepted:** May 15, 2015

**Aims:** Mature cystic teratomas (MCT) commonly known as dermoid cyst, is the most common benign tumor of ovary. The aim of this study was to evaluate the clinicopathological behavior of MCT.

**Methods:** A retrospective cross sectional study on a series of cases was performed in the Department of Pathology, Patan Academy of Health Sciences, Patan Hospital, Lalitpur, Nepal from April 2011 to March 2016. Data from the histopathology database were analyzed using SPSS version 16.0.

**Results:** MCT comprised 230 (57.6%) out of total 399 cases of ovarian neoplasms. The age range of the patients was 8-74 years. The sizes of the tumors ranged from 2.5-20cm. 12% of the cases were bilateral. Ischemic modifications, presumably due to torsion, were noted in 10% of the cases, mostly in tumors larger than 10cm. None of the tumors of less than 5cm presented with signs of torsion. Malignant transformation was present in 7 (3%) cases and was seen especially in older patients and in larger tumors. Squamous cell carcinoma was the most common malignant tumor seen in 5 cases. One case was a mixed germ cell tumor with components of MCT and yolk sac tumor.

**Conclusions:** MCT is the most common germ cell tumor in patients of the reproductive age group. Complications such as torsion and malignant transformation occur mostly in larger tumors.

**Keywords:** Mature cystic teratoma; malignant transformation; ovarian neoplasm; torsion.

## INTRODUCTION

Germ cell tumors comprise approximately 20% of all ovarian neoplasms, majority (95%) being mature cystic teratomas (MCT).<sup>1</sup> MCT, commonly known as dermoid cyst is the most common benign tumor of the ovary. It is originated from primordial germ cells and histologically composed of three well differentiated elements, namely ectoderm, mesoderm and endoderm. The germ cell layer derivatives mainly originate from the ectoderm.<sup>2</sup> MCT account for 25% of all ovarian neoplasms.<sup>3</sup> They are diagnosed with the highest frequency in patients aged between 20 to 40 years but may occur in postmenopausal women and children. They are bilateral in 10-15% of cases.<sup>4</sup> The common symptom is abdominal pain followed by a mass. Some of the patients may be asymptomatic or have symptoms of abdominal distension. The characteristic macroscopic appearance is a multicystic mass that contains hair, teeth and thick, sticky often foul smelling material.<sup>5</sup> Complications associated with dermoid cysts include torsion, rupture and infection.<sup>5,6</sup>

Malignant transformation of MCT is an uncommon complication occurring in approximately 0.17-2% of all cases and the most often reported malignancy is squamous cell carcinoma. Other malignancies include basal cell carcinoma, melanoma, adenocarcinoma, sarcoma and thyroid cancer.<sup>7</sup>

The current study aims to evaluate the prevalence, size of tumor, laterality, complications and surgical treatment modalities undertaken in patients diagnosed histopathologically with a MCT at Patan Academy of Health Sciences, Patan Hospital over a 5 year study period.

## METHODS

This is a retrospective cross sectional study performed in the Department of Pathology at Patan Academy of Health Sciences, Patan Hospital, Lalitpur, Nepal. This study included all cases of MCT surgically treated and histopathologically diagnosed at Patan Hospital from April 2011 to March 2016.

The variables entered in the database were histopathology number, patient identity number, name, age, surgery undertaken, histopathological diagnoses, size of the tumor, laterality, presence or absence of torsion and malignant transformation. Data were analyzed in SPSS version 16.0.

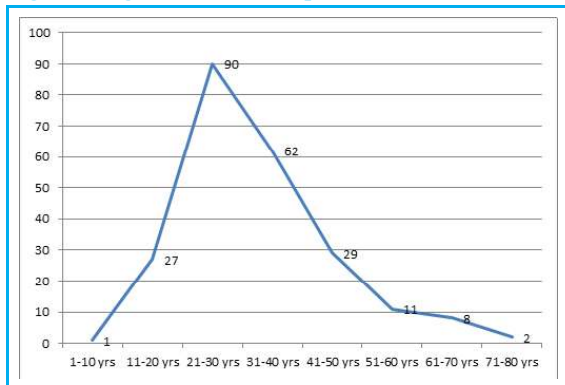
## CORRESPONDENCE

Dr. Palzum Sherpa  
Lecturer, Patan Academy of Health Sciences  
Phone No : 9849169852  
Email: palzumsherpa@pahs.edu.np

## RESULTS

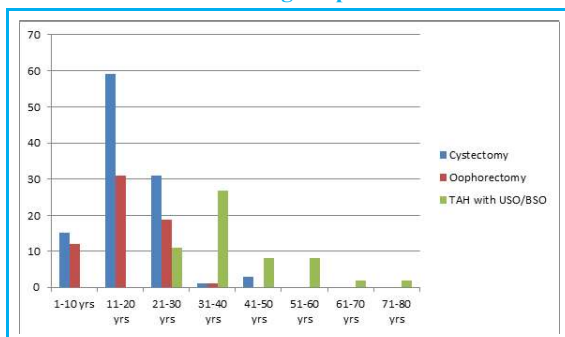
During the study period, MCT constituted 230 (57.6%) out of total 399 cases of all ovarian neoplasms diagnosed and treated at our institution. The age range of the patients was 8-74 years and the common age group was 21-30 years with 90 cases (39.1%). The mean age was 33 years. (Figure 1) The size of the tumors ranged from 2.5-20cm. Left sided tumors were seen in 92 cases (40%) which outnumbered the right sided tumors with 85 cases (37%). Bilaterality was noted in 28 (12%) and in 25 cases (11%), side was not mentioned.

Figure 1: Age distribution of patients with MCT



Ischemic modifications, presumably due to torsion, were noted in 10% of the cases, mostly in tumors larger than 10cm. None of the tumors of less than 5cm presented with signs of torsion. The surgical treatment modalities consisted of cystectomy, oophorectomy and hysterectomy with unilateral or bilateral salpingo-oophorectomy. The treatment modality was selected on the basis of age, desire for future fertility and presence of another pelvic pathology. Cystectomy and oophorectomy were performed for younger patients and hysterectomy with unilateral or bilateral salpingo-oophorectomy for the older age group. (Figure 2)

Figure 2: Distribution of surgical treatment modalities undertaken in relation to age of patients



On gross examination, cut sections of most of the tumors showed a uniloculated cyst with presence of cheesy material and hair. One case was a mixed germ cell tumor with components of MCT and yolk sac tumor. Malignant transformation was present in 7 (3%) cases. Squamous cell carcinoma was the most common malignant tumor seen in 5 cases and there was one case each of adenocarcinoma and carcinoid tumor. (Table 1) The age range of patients with malignant transformation was 30-70 years with a mean of 47.7 years.

Table 1: Incidence of Malignant transformation arising in MCT

Malignant transformation	Number	Percentage
No evidence of malignancy	223	97%
Malignancy present	7	3%
Squamous cell carcinoma	5	
Adenocarcinoma	1	
Carcinoid tumor	1	

## DISCUSSION

MCT is the most common germ cell tumor and also the commonest ovarian tumor in patients of reproductive age group.<sup>8</sup> MCT was the most prevalent tumor accounting for 230 (57.6%) out of total 399 cases in this study, followed by serous cystadenoma (22%) and mucinous cystadenoma (10%). In the present study, it was found that majority of the patients were in the age group of 21-30 years, followed by 31-40 years. Similar findings were observed in studies performed by Wu et al and Hursitoglu et al who reported that most of their subjects belonged to age group 21-40 years.<sup>4,9</sup>

The size of the tumors in the current study ranged from 2.5-20cm. Torsion was noted in 10% of the cases, mostly in tumors larger than 10cm. None of the tumors of less than 5cm presented with signs of torsion. A study done by Benjapibal et al also showed similar torsion rate of 11.1% and among cases with torsion, more than 90% of the tumors were found to be of intermediate size (6-15 cm).<sup>10</sup> Bilateral tumors were noted in 28 cases (12%), corroborating data from various studies.<sup>10,11</sup> Thus, in women with unilateral teratoma, careful inspection of the contralateral ovary is necessary at the time of surgery. However, histological studies of normal appearing contralateral ovaries led to identification of a teratoma in only 1.1% of cases.<sup>12,13</sup>

On gross examination most of the tumors showed a uniloculated cyst with presence of cheesy material and hair. On histopathological examination, skin and its appendages were the most frequently observed derivative. There was also a case of a mixed germ cell tumor with components of MCT and yolk sac tumor.

Malignant transformation of MCT is an uncommon complication occurring in approximately 0.17–2% of all cases.<sup>7</sup> In this study, 7 patients among all those diagnosed with MCT (3%) showed a malignant transformation. Squamous cell carcinoma was the most common malignant tumor seen in

5 cases, supporting previous findings reported in many literatures.<sup>14,15</sup> There was one case each of adenocarcinoma and carcinoid tumor. A study by Kikkawa et al, showed that a tumor diameter larger than 9.9cm had 86% sensitivity for malignancy in their series and concluded that older age, larger tumor and tumor demonstrating rapid growth should be suspected for malignancy.<sup>16</sup>

## CONCLUSION

MCT is the most common germ cell tumor in patients of the reproductive age group. Complications such as torsion and malignant transformation occur mostly in larger tumors.

## REFERENCES

- Peterson WF, Prevost EC, Edmunds FT, Hundley JM Jr., Morris FK. Benign cystic teratomas of the ovary; a clinicostatistical study of 1,007 cases with a review of the literature. *Am J Obstet Gynecol.* 1955; 70: 368-82.
- Matz MH. Benign cystic teratomas of the ovary. A review. *Obstet Gynecol Surv.* 1961;16: 591-605.
- Templeman CL, Fallat ME, Lam AM, Perlman SE, Hertweck SP, O'Connor DM. Managing mature cystic teratomas of the ovary. *Obstet Gynecol Surv.* 2000;55: 738-45.
- Hursitoglu BS, Demirtas GS, Demirtas O, Akman L, Yilmaz H. A clinico-pathological evaluation of 194 patients with ovarian teratoma: 7-year experience in a single center. *Ginekol Pol.* 2013;84: 108-11.
- Ngwalle KE, Hirakawa T, Tsuneyoshi M, Enjoji M. Osteosarcoma arising in a benign dermoid cyst of the ovary. *Gynecol Oncol.* 1990;37: 143-7.
- Aygun B, Kimpo M, Lee T, Valderrama E, Leonidas J, Karayalcin G. An adolescent with ovarian osteosarcoma arising in a cystic teratoma. *J Pediatr Hematol Oncol.* 2003;25: 410-3.
- Mandal S, Dhingra K, Gupta P, Khurana N. Rare growth of a psammomatous meningioma in a mature ovarian teratoma: a case report. *Pathol Res Pract.* 2010;206: 322-4.
- Lakkis WG, Martin MC, Gelfand MM. Benign cystic teratoma of the ovary: a 6-year review. *Can J Surg.* 1985;28: 444-6.
- Wu RT, Torng PL, Chang DY, Chen CK, Chen RJ, Lin MC et al. Mature cystic teratoma of the ovary: a clinicopathologic study of 283 cases. *Zhonghua yi Xue Za Zhi.* 1996;58: 269-74.
- Benjapibal M, Boriboonhirunsarn D, Suphanit I, Sangkarat S. Benign cystic teratoma of the ovary : a review of 608 patients. *J Med Assoc Thai.* 2000;83: 1016-20.
- Comerci JT Jr., Licciardi F, Bergh PA, Gregori C, Breen JL. Mature cystic teratoma: a clinicopathologic evaluation of 517 cases and review of the literature. *Obstet Gynecol.* 1994;84: 22-8.
- Doss N Jr., Forney JP, Vellios F, Nalick RH. Covert bilaterality of mature ovarian teratomas. *Obstet Gynecol.* 1977;50: 651-3.
- Ayhan A, Aksu T, Develioglu O, Tuncer ZS, Ayhan A. Complications and bilaterality of mature ovarian teratomas (clinicopathological evaluation of 286 cases). *Aust N Z J Obstet Gynaecol.* 1991;31: 83-5.
- Koc S, Tapisiz OL, Turan T, Ocalan R, Ozfuttu A, Boran N et al. Malignant transformation of mature cystic teratoma of the ovary: a case series. *JJ Exp Ther Oncol.* 2015;11: 11-6.
- Kalampokas E, Boutas I, Kairi-Vasiliadou E, Salakos N, Panoulis K, Aravantinos L et al. A rare case report of squamous-cell carcinoma arising from mature cystic teratoma of ovary. *G Chir.* 2014;35: 241-5.
- Kikkawa F, Nawa A, Tamakoshi K, Ishikawa H, Kuzuya K, Saganuma N et al. Diagnosis of squamous cell carcinoma arising from mature cystic teratoma of the ovary. *Cancer.* 1998;82: 2249-55.