


## Role of short term Video EEG monitoring & MRI in refractory Epilepsy



D.V.Madhavi Kumari<sup>1</sup>, Aruna kumari<sup>2</sup>, Sateesh Kumar<sup>3</sup>, Gopi Seepana<sup>4</sup>, G. Butchi Raju<sup>5</sup>

<sup>1</sup> Assistant Professor, Department of Neurology, Government Siddhartha Medical College, Vijayawada.

<sup>2</sup> Associate Professor, Department of Neurology, Guntur Medical College, Guntur.

<sup>3,4,5</sup> Department of Neurology, King George Hospital/Andhra Medical College, Visakhapatnam.

Date of submission: 14<sup>th</sup> August 2023

Date of Acceptance: 17<sup>th</sup> January 2024

Date of publication: 30<sup>th</sup> January 2024

### Abstract

**Introduction:** Inpatient video EEG monitoring is widely used for the diagnosis, seizure classification and pre surgical evaluation of patients with epilepsy. Only few studies have highlighted the role of short term video EEG in the diagnosis of paroxysmal events. The present study was undertaken to identify the role of short term video EEG in refractory epilepsy.

**Materials & Methods:** Forty patients, attending neurology outpatient department in our institution, during the study period, fulfilling the criteria for refractory epilepsy were included. Short term video EEG and MRI Brain were done for all of them. Outcomes measured were 1) Video recording of epileptic seizures with concurrent ictal pattern or psychogenic non epileptic seizure. 2) Identification of new interictal epileptiform discharges, which were not there in the previous routine EEG. 3) Observation of congruency between EEG and MRI Brain.

**Results :** Clinical events were recorded in 12.5% of patients - 7.5% had epileptic seizures and 5% had psychogenic non epileptic seizures recorded. Short term video EEG was abnormal in 70% of the patients, whereas previous routine EEG was abnormal in only 30% and these observations were statistically significant. Short term video EEG was useful in diagnostic classification in 70% of the cases. MRI Brain was abnormal in 35% and among them, 30% had lateralized epileptiform discharges and the congruency between them is not statistically significant.

**Conclusions :** Short term video EEG monitoring could be an initial investigation to sort our more frequent seizure group and proceed to long term VEEG if short term VEEG is inconclusive

**Keywords:** Refractory epilepsy, Pre surgical evaluation, Video EEG, Psychogenic non epileptic seizures, MRI.

### Introduction

It is estimated in various studies that the overall prevalence of epilepsy in India is 5.59–10 per 1000.<sup>1,2,3</sup> and 20-40%.<sup>4</sup> of the patients develop medically intractable epilepsy, defined<sup>5</sup> as “failure of adequate trials of two tolerated and appropriately chosen and used AED schedules (whether as monotherapies or in combination) to achieve sustained seizure freedom” -

International League Against Epilepsy (ILAE) consensus definition, 2009. When a patient does not respond to medical treatment and is defined as having drug resistant epilepsy, he/she should then be investigated for a possibility of epilepsy surgery. It is essential that appropriate diagnosis of patients with drug resistant epilepsy (DRE) is made prior to pre surgical evaluation. Studies have shown that approximately 20% of cases diagnosed as refractory epilepsy are pseudorefractory.<sup>6</sup> Psychogenic Non Epileptic Seizures (PNES), incorrect classification with incorrect treatment, inadequate dosing, poor compliance and inappropriate life style were identified as the major causes.<sup>7</sup> for pseudo refractoriness. Correct classification of seizure type and epileptic syndrome is mandatory for selecting the appropriate AED.<sup>8</sup> Selected generalized forms of epilepsy may be aggravated by some AEDs.

Video-EEG (VEEG) monitoring is an essential tool in this process, aiming to perform a differential diagnosis of paroxysmal events and a correct classification of seizures and epileptic syndromes. Inpatient long-term video-EEG monitoring, classically performed over 5 days to 2 weeks, is well established as a diagnostic tool in the pre surgical evaluation of epilepsy to characterize complex epileptic syndromes, to document seizure frequency as well as to confirm suspected PNES. In between outpatient “routine” EEG and long term video EEG monitoring lies short-term video-EEG monitoring (SVEM), an elective procedure typically lasting less than 24 hours. This is emerging as a less resource and cost intensive procedure compared with

#### Access this article online

Website: <https://www.nepjol.info/index.php/NJN>

DOI: <https://doi.org/10.3126/njn.v20i4.58957>

#### HOW TO CITE

D V MK, U AK, T SK, G BR. Role of short term Video EEG monitoring and MRI in refractory Epilepsy . NJNS. 2023;20(4):44-49



#### Address for correspondence:

Dr. D V Madhavi kumari

Assistant Professor,

Department of Neurology, Government Siddhartha Medical College, Vijayawada.

E-mail: chinmayas4@gmail.com

Copyright © 2023 Nepalese Society of Neurosurgeons (NESON)

ISSN: 1813-1948 (Print), 1813-1956 (Online)



This work is licensed under a Creative Commons Attribution-Non Commercial 4.0 International License.

long term video EEG monitoring. Short duration outpatient video EEG has been used successfully in paediatric practice. The practical value of SVEM in capturing PNESs has been described with proportions ranging from 16.8% to 67%.<sup>9,10</sup> Studies have also shown that diagnostic yield of interictal EEG increases steeply with increasing the duration of the trace.<sup>11,12</sup>

In resource poor settings and in conditions where the cost of long term video EEG monitoring is extensive, short term Video EEG monitoring can be considered as one of the important initial investigation in refractory epilepsy, which can be used to exclude PNES (VEEG is considered a gold standard in the diagnosis of PNES), for confirmation and alteration of diagnosis and thereby make necessary changes in the management and to identify potential surgical candidates, especially those who have focal seizure onset.

Data shows that MRI successfully visualizes morphological changes in 80% of patients with epilepsy and concordance of EEG with MRI increases the possibility of good surgical outcome and is maximum with mesial temporal lobe epilepsy.<sup>13</sup>

Studies regarding the utility of short term video EEG in refractory epilepsy are sparse. Therefore, this study was undertaken to assess the usefulness of short term video EEG in patients with refractory epilepsy and to observe the congruency between short term video EEG and Magnetic Resonance Imaging in these patients.

## Materials & Methods

The study group consisted of all patients who fulfilled the criteria for refractory epilepsy, attending the neurology outpatient department (OPD) of our institution during the study period of two years. It is a hospital based observational study.

Patients those satisfying the inclusion and exclusion criteria were only enrolled in the study. Patients above 10 years fulfilling the criteria for refractory epilepsy: on two drugs (appropriate and adequate) and not seizure free during the last 3 months were included in the study. Patients below 10 years, patients with break through seizures that occur due to seizure provoking external factors such as sleep deprivation, menstruation, intercurrent febrile illness and pregnant patients were excluded from the study. Written informed consent was taken from all subjects enrolled in this study. This study was approved by Institutional Ethical committee.

## Methods

Detailed history regarding the seizure semiology, seizure frequency, family history and drug history was collected from the patient and eye witness for the seizure. Diagnosis of epileptic seizures and syndromes was made based on the ILAE classification. Short term video EEG and MRI Brain were done for all the patients.

### Short term video EEG monitoring:

A standard digitalized 10-20 system - 32 channel EEG, single channel electrocardiogram and simultaneous digital video was recorded using Nicolet system. Average recording duration

was 3 hours. Activation procedures such as sleep deprivation, hyperventilation and photic stimulation were used. If PNES were suspected, simple suggestion techniques were used. If an attack was recorded, it was shown to the eyewitness, to confirm whether typical; if no eyewitness was available at that time, the video was reviewed later. SVEM was considered to be positive : 1. If there were targeted events recorded : (a) epileptic seizure, with a concurrent ictal EEG pattern or post ictal pattern; (b) psychogenic nonepileptic seizure (PNES), defined as episodes of altered behaviour which include motor activity and altered sensation and/or perception which may appear similar to those experienced and seen in epileptic seizures and devoid of concurrent ictal or post-ictal EEG changes and 2. If there were interictal discharges recorded, which were not there in the previous routine EEG recording.

### MRI BRAIN

1.5 Tesla Magnetic Resonance Imaging of Brain including the coronal sections was done for all the patients. The congruency between EEG and MRI Brain was observed.

### Statistical analysis

The data was entered and analysed using Statistical Package for Social Science (SPSS) version 14. The p value was taken as significant when less than 0.05 (Confidence interval of 95% was taken). The chi-square test was used to get the proportions.

## Results

Mean age of the study group was 26 years and maximum patients were in the age group 10-20 years. Mean age of onset of seizures was 13.5 years and maximum number of the patients had onset of seizures at the age of 2-10 years. Most of the cases were in the frequency group 1-4/month and only one patient had daily seizures. Maximum number of patients i.e. 68% had partial seizures and 32% had generalized seizures.

REEG was abnormal in 30% of cases and in SVEM, EEG was abnormal in 70% of cases. Among them 50% had lateralized discharges. Most of the discharges were localized to the temporal region, followed by fronto-temporal, frontal and parietal. It consisted of both epileptiform and other abnormalities. SVEM showed abnormalities in the EEG, more frequently than routine EEG and this observation was statistically significant with a p value < 0.05. Table.1

*Table 1: Interictal discharges – Routine EEG (REEG) vs short term video EEG(SVEM)*

Interictal discharges	SVEM-Normal(n=11)	SVEM-Focal(n=21)	SVEM-	Total
REEG-	11	13	4	28
REEG-Focal(n=7)	0	7	0	7
REEG-	0	1	4	5
TOTAL	11	21	8	40

*P= significant (Chi-square)*

With SVEM, events were recorded in 12.5% of cases, 5% had PNES and 7.5% had epileptic seizures recorded. Among them one had complex partial seizures, and 2 had partial with secondary generalized seizures. Table.2

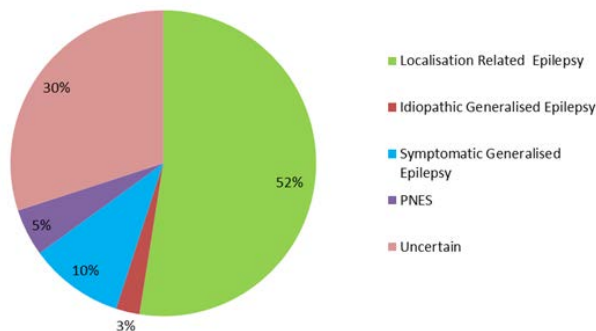
**Table 2: Short term video EEG monitoring-events recorded**

Events recorded	No. of cases (n=10)
PNES	2 (5%)
EPILEPTIC SEIZURES WITH ICTAL CORRELATE	3(7.5%)
TOTAL	5(12.5%)

SVEM was abnormal in all the patients with seizure frequency daily and 1-6/week, where as in patients with seizure frequency 1-4/month, 10 patients had normal EEG. All the patients with daily seizures had lateralised EEG. But this data is not statistically significant with a p value of 0.418. All patients with daily seizures had events recorded when compared to the less frequent seizures and this data is statistically significant with a p value of 0.001. Two patients who were in the 1-4/month frequency group had psychogenic non epileptic seizures. There is no significant association between age group and abnormal EEG and it is also statistically proven with a p value of 0.028. Maximum patients were in the age group 11-20 years, and many of them had lateralized discharges.

SVEM was useful in diagnosing 5% of cases as psychogenic non epileptic seizures and later anti-epileptic drugs were tapered in them. 3 patients had epileptic seizures recorded, along with concurrent ictal pattern. 2 of them were diagnosed as temporal lobe epilepsy and one of them had frontal focus. Interictal EEG was abnormal in 70% of the cases. 50% of them had lateralized epileptiform discharges and were diagnosed as having Localization related epilepsy according to the ILAE classification -1989. 20% of the patients had generalized discharges, but 5% of them had partial seizures and there was a discordance between the seizure semiology and interictal EEG and the diagnosis was undetermined in them. Remaining 15% were diagnosed as having Generalized epilepsy.

On the whole, SVEM was useful in diagnosis and classification in 70% of the cases. 50% of them were diagnosed as localization related epilepsy, 15% were diagnosed as Generalized epilepsy and 5% as Psychogenic non epileptic seizures. Figure.1



**Figure 1: Diagnostic Usefulness Of Short term Video EEG Monitoring**

MRI Brain was abnormal in 35 % of the patients. Table.3

**Table 3: MRI findings**

MRI Brain	No. of Cases (%)
Hippocampal sclerosis	4 (10 %)
Gliosis – Post traumatic	2 (5 %)
Perinatal insult	6 (15 %)
Calcified neurocysticercal lesions	2 (5 %)

Among them, 30% had lateralized epileptiform discharges. Concordance between MRI and STVEM was not statistically significant with a p value of 0.101. Table.4

**Table 4: MRI BRAIN vs EEG**

	MRI Brain	
	MRI – Normal (n=26)	MRI –Abnormal (n=14)
EEG – Normal (n=11)	10	1
EEG – Focal (n=23)	12	9
EEG – Generalised (n=8)	4	4

*P=not significant (Chi-square)*

## DISCUSSION

The value of inpatient video-EEG monitoring in the diagnosis, classification, and presurgical evaluation of epilepsy has been well established (Boon et al.<sup>14</sup>, 1999; Cascino.<sup>15</sup>, 2002; Ghougassian et al.<sup>16</sup>, 2004). But the benefits of inpatient video-EEG monitoring come at a significant cost since the patients require hospitalization and continuous supervision by trained personnel for several days.

The role of short term video EEG in adults and children was explored in several studies. (Srikumar et al.<sup>17</sup>, 2000; Alessandra Freitas et al.<sup>18</sup>, 2003; McGonial et al.<sup>19</sup>, 2004; Benbadis et al., 2004; Pradeep N. Modur et al.<sup>20</sup>, 2007; Mughis Sheerani et al.<sup>21</sup>, 2007; Udaya Seneviratne et al.<sup>22</sup>, 2012). The present study was undertaken to study the role of short term video EEG in refractory epilepsy.

In the present study mean age of onset of seizures was 13.5 years. In the study by Manjari Tripathi et.al.<sup>23</sup>, majority of patients in the intractable group had onset of seizures before the age of 14 years and showed that age at onset was an influential predictor of refractory epilepsy. In the study by Mughis Sheerani et.al, mean age of onset for seizures was 18 years. In the study by E. Viteva et.al.<sup>24</sup>, the mean age at onset of epilepsy was 13.09 ± 1.27 years. The present study population again shows that younger age at onset of epilepsy is probably a predictive factor for RE.<sup>25</sup>

In the present study, 68% had partial seizures and 32% had generalized seizures. According to the study in North India by Manjari T et al., in the intractable group, 83% patients had partial seizures, and 7% had generalized seizures. In a study conducted by J.P. Singhvi<sup>26</sup> et al., in a tertiary referral centre, in the intractable group, 74 % had partial seizures and 26 % had generalised seizures. In the study by Muhammad Akbar Malik et al<sup>27</sup>., in intractable childhood epilepsy, 54% had generalised seizures and 46% had partial seizures. Partial seizure type was

found to be independent predictor of intractability in the study by Manjari et al., and present study is in accordance with that.

In the present study routine EEG was abnormal in 30% cases. In the study done by Singhvi et al., routine EEG was abnormal in 69% cases. In the study done by Andrew CF Hui.<sup>28</sup> et al., routine EEG was abnormal in 13% cases. In the study by Ghougassian et al., routine EEG was abnormal in 12% of cases. In the study done by Pradeep N Modur et al., routine EEG was abnormal in 27% of cases and on extended video EEG monitoring for a period of 4 hours, EEG was abnormal in 50% of cases. Their study population comprised of suspected but unconfirmed epilepsy. The present study is comparable to the study by Padeep N Modur et al. and again establishes that diagnostic yield of interictal EEG increases steeply with increasing the duration of the trace.

A number of factors influence whether patients with epilepsy will show IED in the EEG. The timing of EEG recording may be important: investigation within 24 hours of a seizure revealed IED in 51%, compared with 34% who had later EEG.<sup>29</sup>, which was not observed in the present study. In the study done by M Sundaram et al.<sup>30</sup>, EEGs of patients having > 12 seizures/year were more likely to contain inter ictal spike discharges (IEDs) (68%) than the records of cases with <12 attacks/year (37–41%; P <0.0001). The present study did not show any statistically significant association between the frequency of seizures and occurrence of IEDs.

In the present study, clinical events were recorded in 12.5% patients (n=5); PNES in 5% and epileptic seizures in 7.5% cases. The diagnostic yield in terms of recording of clinical events is slightly less when compared to other studies. This could be because of the differences in the study population and the duration for which the video EEG recording was done. The comparison is summarized in Table.5

**Table 5: Comparison of video EEG monitoring studies regarding the diagnostic yield**

	Duration of recording (mean)	Epileptic seizures (%)	PNES (%)	Population group (Pretest diagnosis)
Present study	3 hrs	7.5	5	Refractory Epilepsy
Seneviratne et al	3.8 hrs	6.9	37.1	EP,PNES
Modur et al	4-4.5 hrs	5	16.8	EP,PNES
Tallawy et al <sup>31</sup>	2 hrs	13.9	30.6	EP,PNES
Kamel et al <sup>32</sup>	6 hrs	5.9	0	EP
Desai et al <sup>33</sup>	47 mins	16.6	70.3	PNES, TRANSIENT UNRESPON-SIVENESS
Nada et al <sup>34</sup>	3 hrs	17.5	8.7	EP,PNES

ES–Epileptic Seizure, PNES–Paroxysmal Non epileptic seizures

In our study, the number of epileptic seizures recorded is comparable to the studies done by Seneviratne et al and Modur et al, but the results are less when compared to the studies done by Nada et al, Desai et al and Tallawy et al. This could be because of the discrepancy in the study population, as all of our patients are known epileptics on adequate medical management. In a multivariate analysis done by E. Gomez-Figueroa et al.<sup>35</sup> suggested that, the yield of epileptic short term video EEG increases in patients with daily seizures and in patients who had an epileptic event in the last month. In our present study, most of the patients were in the frequency group 1-4/month, only one had daily seizures.

In a Long term VEEG study by Andrew CF Hui et al., in refractory epilepsy patients for a mean duration of monitoring for 4.4 days, clinical events were recorded in 62% of cases and EEG was abnormal in 52% of cases. The most common events were complex partial seizures followed by non-epileptic attacks. Though direct comparison cannot be made, it shows the higher yield of long term video EEG.

Study done by Ekaterina Pataraiia et al.<sup>36</sup>, suggested that unilateral hippocampal atrophy on MRI and uni-temporal interictal spikes can predict localization of ictal scalp EEG changes with a high degree of reliability. Study done by Blume W T et al.<sup>37</sup>, suggest that the awake interictal scalp EEG cannot be ignored when assessing laterality of temporal epileptogenesis. These studies suggest the importance of interictal EEG in localization and in the present study 70% of the cases showed abnormal interictal EEG and among the lateralized discharges, 40-60% were localized to the temporal lobe.

In the present study, concordance between MRI and STVEM was not statistically significant with a p value of 0.101. This is because EEG and MRI were not lateralised to the same side among 35 % of patients with abnormal EEG and MRI. This could be explained by false lateralisation of scalp EEG and occurrence of bilateral focal discharges.

## Conclusion

Short term video EEG monitoring could be an initial investigation to sort our more frequent seizure group and proceed to long term VEEG if short term VEEG is inconclusive. Diagnostic usefulness includes increase in the yield of interictal EEG, event recording particularly in patients with high seizure frequency and suspected psychogenic non epileptic seizures.

## Reference

1. Sridharan R, Murthy BN. Prevalence and pattern of epilepsy in India. *Epilepsia*. 1999 May;40(5):631-6. doi: 10.1111/j.1528-1157.1999.tb05566.x. PMID: 10386533.
2. Sridharan R. Epidemiology of epilepsy. *Curr Sci* 2002;82:664-70. <http://www.jstor.org/stable/24106692>.
3. Goel D, Agarwal A, Dhanai JS, Semval VD, Mehrotra V, Saxena V, Maithili B. Comprehensive rural epilepsy surveillance programme in Uttarakhand state of India. *Neurol India*. 2009 May-Jun;57(3):355-6. doi: 10.4103/0028-3886.53274. PMID: 19587489.
4. French JA. Refractory epilepsy: clinical overview. *Epilepsia*.



- 2007;48 Suppl 1:3-7. doi: 10.1111/j.1528-1167.2007.00992.x. PMID: 17316406.
5. Kwan P, Arzimanoglou A, Berg AT, Brodie MJ, Allen Hauser W, Mathern G, Moshé SL, Perucca E, Wiebe S, French J. Definition of drug resistant epilepsy: consensus proposal by the ad hoc Task Force of the ILAE Commission on Therapeutic Strategies. *Epilepsia*. 2010 Jun;51(6):1069-77. doi: 10.1111/j.1528-1167.2009.02397.x. Epub 2009 Nov 3. Erratum in: *Epilepsia*. 2010 Sep;51(9):1922. PMID: 19889013.
  6. Viteva EI, Zahariev ZI. Pseudoresistance in patients with epilepsy--characteristics and determining factors. *Folia Med (Plovdiv)*. 2009 Apr-Jun;51(2):33-9. PMID: 19670538.
  7. Kutlu G, Erdal A, Gomceli YB, Inan LE. Pseudo-refractory epilepsy. *Neurosciences Journal*. 2013;18(3):284-286. <https://nsj.org.sa/content/18/3/284>.
  8. Brodie MJ. Diagnosing and predicting refractory epilepsy. *Acta Neurol Scand Suppl*. 2005;181:36-9. doi: 10.1111/j.1600-0404.2005.00507.x. PMID: 16238707.
  9. Benbadis SR, Siegrist K, Tatum WO, Heriaud L, Anthony K. Short-term outpatient EEG video with induction in the diagnosis of psychogenic seizures. *Neurology*. 2004 Nov 9;63(9):1728-30. doi: 10.1212/01.wnl.0000143273.18099.50. PMID: 15534269.
  10. Seneviratne U, Rahman Z, Diamond A, Brusco M. The yield and clinical utility of outpatient short-term video-electroencephalographic monitoring: a five-year retrospective study. *Epilepsy Behav*. 2012 Nov;25(3):303-6. doi: 10.1016/j.yebeh.2012.08.018. Epub 2012 Oct 24. PMID: 23099231.
  11. Badry R. Latency to the first epileptiform activity in the EEG of epileptic patients. *Int J Neurosci*. 2013 Sep;123(9):646-9. doi: 10.3109/00207454.2013.785543. Epub 2013 Apr 15. PMID: 23510030.
  12. Narayanan JT, Labar DR, Schaul N. Latency to first spike in the EEG of epilepsy patients. *Seizure*. 2008 Jan;17(1):34-41. doi: 10.1016/j.seizure.2007.06.003. Epub 2007 Jul 26. PMID: 17662624.
  13. Gilliam F, Bowling S, Bilir E, Thomas J, Faught E, Morawetz R, Palmer C, Hugg J, Kuzniecky R. Association of combined MRI, interictal EEG, and ictal EEG results with outcome and pathology after temporal lobectomy. *Epilepsia*. 1997 Dec;38(12):1315-20. doi: 10.1111/j.1528-1157.1997.tb00069.x. PMID: 9578527.
  14. Boon P, De Reuck J, Drieghe C, De Bruycker K, Aers I, Pengel J. Long-term video-EEG monitoring revisited. The value of interictal and ictal video-EEG recording, a follow-up study. *Eur Neurol*. 1994;34 Suppl 1:33-9. doi: 10.1159/000119507. PMID: 8001608.
  15. Cascino GD. Video-EEG monitoring in adults. *Epilepsia*. 2002;43 Suppl 3:80-93. doi: 10.1046/j.1528-1157.43.s.3.14.x. PMID: 12060010.
  16. Ghougassian DF, d'Souza W, Cook MJ, O'Brien TJ. Evaluating the utility of inpatient video-EEG monitoring. *Epilepsia*. 2004 Aug;45(8):928-32. doi: 10.1111/j.0013-9580.2004.51003.x. PMID: 15270758.
  17. Srikumar G, Bhatia M, Jain S, Maheshwari MC. Usefulness of short term video-EEG monitoring in children with frequent intractable episodes. *Neurol India*. 2000 Mar;48(1):29-32. PMID: 10751810.
  18. Freitas A, Fiore LA, Gronich G, Valente KD. O vídeo-EEG dia no diagnóstico de eventos paroxísticos na infância [The diagnostic value of short-term video-EEG monitoring childhood epilepsy]. *J Pediatr (Rio J)*. 2003 May-Jun;79(3):259-64. Portuguese. PMID: 14506537.
  19. McGonigal A, Russell AJ, Mallik AK, Oto M, Duncan R. Use of short term video EEG in the diagnosis of attack disorders. *J Neurol Neurosurg Psychiatry*. 2004 May;75(5):771-2. doi: 10.1136/jnnp.2003.024893. PMID: 15090577; PMCID: PMC1763561.
  20. Modur PN, Rigdon B. Diagnostic yield of sequential routine EEG and extended outpatient video-EEG monitoring. *Clin Neurophysiol*. 2008 Jan;119(1):190-6. doi: 10.1016/j.clinph.2007.09.128. Epub 2007 Nov 26. PMID: 18042424.
  21. Mughis Sheerani, Ali Hassan, Ameer Jan, and Royala Zaka : Role of video EEG monitoring in the management of intractable seizures and Non epileptic spells. *Pak J Neurol Sci* 2007; 2(4):207-9.
  22. Seneviratne U, Rahman Z, Diamond A, Brusco M. The yield and clinical utility of outpatient short-term video-electroencephalographic monitoring: a five-year retrospective study. *Epilepsy Behav*. 2012 Nov;25(3):303-6. doi: 10.1016/j.yebeh.2012.08.018. Epub 2012 Oct 24. PMID: 23099231.
  23. Tripathi M, Padhy UP, Vibha D, Bhatia R, Padma Srivastava MV, Singh MB, Prasad K, Chandra SP. Predictors of refractory epilepsy in north India: a case-control study. *Seizure*. 2011 Dec;20(10):779-83. doi: 10.1016/j.seizure.2011.07.010. Epub 2011 Aug 6. PMID: 21821437.
  24. E. Viteva : Predictors and Typical Clinical Findings of Refractory Epilepsy. *American Journal of Clinical Medicine Research*, 2014, Vol. 2, No. 1, 26-31.
  25. Ko TS, Holmes GL. EEG and clinical predictors of medically intractable childhood epilepsy. *Clin Neurophysiol*. 1999 Jul;110(7):1245-51. doi: 10.1016/s1388-2457(99)00068-1. PMID: 10423189.
  26. Singhvi JP, Sawhney IM, Lal V, Pathak A, Prabhakar S. Profile of intractable epilepsy in a tertiary referral center. *Neurol India*. 2000 Dec;48(4):351-6. PMID: 11146600.
  27. Malik MA, Hamid MH, Ahmed TM, Ali Q. Predictors of intractable childhood epilepsy. *J Coll Physicians Surg Pak*. 2008 Mar;18(3):158-62. PMID: 18460244.
  28. Hui AC, Kwan P, Leung TW, Soo Y, Mok VC, Wong LK. Diagnostic value and safety of long-term video-EEG monitoring. *Hong Kong Med J*. 2007 Jun;13(3):228-30. PMID: 17548912.
  29. King MA, Newton MR, Jackson GD, Fitt GJ, Mitchell LA, Silvapulle MJ, Berkovic SF. Epileptology of the first-seizure presentation: a clinical, electroencephalographic, and magnetic resonance imaging study of 300 consecutive patients. *Lancet*. 1998 Sep 26;352(9133):1007-11. doi: 10.1016/S0140-6736(98)03543-0. PMID: 9759742.

30. Sundaram M, Hogan T, Hiscock M, Pillay N. Factors affecting interictal spike discharges in adults with epilepsy. *Electroencephalogr Clin Neurophysiol.* 1990 Apr;75(4):358-60. doi: 10.1016/0013-4694(90)90114-y. PMID: 1691085.
31. H. N. E. Tallawy, H. Fukuyama, A. A. A. Kader, N. F. Kamel, and R. Badry, "Role of short-term outpatient videoelectroencephalography in diagnosis of paroxysmal disorders," *Epilepsy Research*, vol. 88, no. 2-3, pp. 179–182, 2010.
32. Kamel JT, Christensen B, Odell MS, D'Souza WJ, Cook MJ. Evaluating the use of prolonged video-EEG monitoring to assess future seizure risk and fitness to drive. *Epilepsy Behav.* 2010;19(4):608–11.
33. Desai SD, Desai D, Jani T. Role of short term video encephalography with induction by verbal suggestion in diagnosis of suspected paroxysmal nonepileptic seizure-like symptoms. *Epilepsy Res Treat.* 2016;2016:1–6.
34. Nada, M.M.A.M., Raafat, H., Al Menabbawy, M.K. et al. Role of short-term video electroencephalogram in monitoring seizure diagnosis. *Egypt J Neurol Psychiatry Neurosurg* 55, 78 (2019). doi:10.1186/s41983-019-0119-2.
35. Gomez-Figueroa E, Vargas-Sanchez Á, Alvarado-Bolaños A, Paredes-Aragón E, Alatrister-Booth V, Moreno-Avellan Á, Fernández M. The role of short-term video electroencephalogram monitoring for epilepsy and psychogenic seizures: Experience from a Latin American referral center. *J Clin Neurosci.* 2020 Dec;82(Pt A):105-110
36. Patariaia E, Lurger S, Serles W, Lindinger G, Aull S, Leutmezer F, Bacher J, Olbrich A, Czech T, Novak K, Deecke L, Baumgartner C. Ictal scalp EEG in unilateral mesial temporal lobe epilepsy. *Epilepsia.* 1998 Jun;39(6):608-14. doi: 10.1111/j.1528-1157.1998.tb01429.x. Erratum in: *Epilepsia* 1998 Sep;39(9):1022-3. PMID: 9637603.
37. Blume WT, Borghesi JL, Lemieux JF. Interictal indices of temporal seizure origin. *Ann Neurol.* 1993 Nov;34(5):703-9. doi: 10.1002/ana.410340513. PMID: 8239564