

LGI 1 Antibody Encephalitis- Clinical Characteristics and Short Term Outcome Along with Review of Literature

Praveen Panicker¹, Dileep Ramachandran², Raj Satheesh Chandran³, Thomas Iype⁴


^{1,2,4}Department Of Neurology, Government Medical College Thiruvananthapuram

³Department Of Neurosurgery, Government Medical College Thiruvananthapuram

Date of submission: 11th June 2023

Date of Acceptance: 7th February 2024

Date of publication: 15th May 2024



Abstract

LGI1 (Leucine-rich glioma inactivated protein-1) antibody disease is one of the major causes of limbic encephalitis encountered in clinical practice manifesting with clinical seizures, behavioural disturbances and movement disorders. Here we discuss the varied presentations of this disease through three cases encountered at our center emphasizing the cardinal clinical, imaging and laboratory diagnostic features. Recognition of these characteristics would lead to early diagnosis and prompt management of this eminently treatable condition.

Introduction

Limbic encephalitis is characterised by the clinical syndrome of memory, behavioural disturbances, seizures or movement disorders with imaging evidence of medial temporal lobe involvement. It can be seen in association with underlying tumors such as small cell carcinoma lung, thymoma and various other malignancies as a paraneoplastic syndrome or as a non-paraneoplastic syndrome.

Common antibodies associated with this presentation include AMPA-R, GABA-B (amino-3-hydroxy-5-methyl-4-isoxazolepropionic acid receptor, gamma-aminobutyric acid-B receptor) and LGI1 antibody. LGI1 protein is predominantly expressed in the hippocampus and temporal cortex. It is secreted into the synapse and interacts with 2 synaptic proteins (presynaptic ADAM23 and postsynaptic ADAM22), organizing a protein complex that includes the presynaptic Kv1.1/Kv1.2 potassium channels and postsynaptic AMPA-receptor scaffolds. This complex is predominantly inhibitory in function.

Lai et al.¹ proposed that in patients with LGI1 antibodies, an immune-mediated disruption of LGI1 function causes increased

excitability, resulting in seizures and limbic encephalopathy. Some patients present with a rapidly progressive dementia with focal seizures, myoclonus that mimics Creutzfeldt-Jakob disease².

Median age of presentation is 60 years and 65 percentage of cases are seen in males. Tumor association has been described in less than 20 percent cases³

CASE1- "THE LADY WITH GOOSEBUMPS"

48 year old previously healthy lady presented with history of decreased personal care, decreased interest in household activities followed by abnormal behaviour and irrelevant talk of 8 months duration. In view of these symptoms, she initially presented to the psychiatry out patient facility at our institution from where she was referred to us.

Along with these behavioural symptoms, the relatives also reported recurrent involuntary movements characterised by abnormal flexion of the right elbow followed by staring and subsequent irrelevant talk lasting seconds to few minutes. There would be almost 4-5 similar episodes every day. There was no associated bowel or bladder incontinence or secondary generalised tonic-clonic posturing.

The prominent clinical finding observed during all these stereotyped episodes was that these were accompanied by piloerection in the right upper limb which would subside once the episode was over.

On examination, her Mini mental status examination (MMSE) score was 21, there were no lateralising neurological deficits elicited on examination. Signs of meningeal irritation were absent.

Blood investigations showed mild hyponatremia- Serum sodium value was 134 MEq/dL (Milliequivalent/dwcciliter). Electroencephalogram showed bilateral temporal slowing which was prominent in the left hemisphere.

Magnetic resonance imaging showed bilaterally symmetrical T2 and FLAIR hyperintensities in the medial temporal lobes especially in the region of hippocampus.

Her Serum and CSF LGI1 antibody testing turned out to be positive. Autoimmune workup also showed weakly reactive antinuclear antibody (ANA) and dsDNA antibody positivity. She was treated with immunotherapy- A 5 day course of intravenous

Access this article online

Website: <https://www.nepjol.info/index.php/NJN>

DOI: <https://doi.org/10.3126/njn.v21i1.55654>

HOW TO CITE

Panicker P, Dileep R, Chandran R.S, Iype T. LGI 1 Antibody Encephalitis: Clinical characteristics and short term outcome along with review of literature. *NJNS. NJNS. 2024;21(1):47-51*



Address for correspondence:

Praveen Panicker MD DM (Neuro), DNB (Neuro)
Assistant Professor, Department Of Neurology
Government Medical College, Thiruvananthapuram
Email: panicker85@gmail.com

Copyright © 2023 Nepalese Society of Neurosurgeons (NESON)

ISSN: 1813-1948 (Print), 1813-1956 (Online)



This work is licensed under a Creative Commons Attribution-Non Commercial 4.0 International License.

methylprednisolone along with antiepileptic carbamazepine for the seizures. Subsequently she was put on oral prednisolone in 1mg/kg dosage.

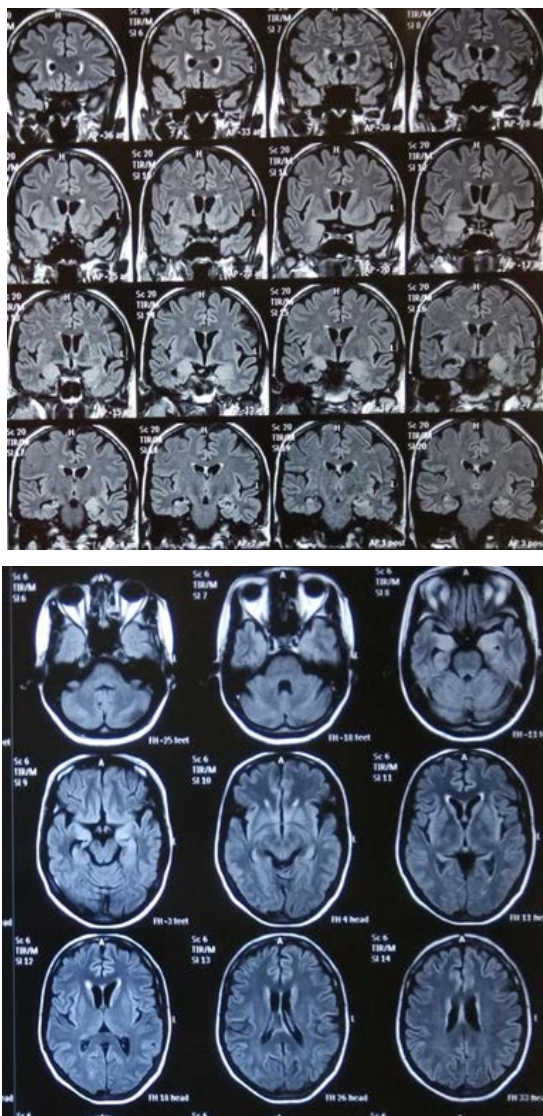
She responded well to treatment, seizures getting controlled completely within 1 week and her cognitive and behavioural symptoms also got better on follow up. Follow up MMSE recorded was 29 at 1 month.

This case highlights the unique finding of piloerection during the stereotyped seizure like events in LGII antibody encephalitis which turned out to be the single most important diagnostic clue in clinching the diagnosis.

Piloerection and pilomotor seizures in LGII antibody encephalitis have previously been reported in literature by many authors. However, the frequency of patients with such events is considerably low as compared to the classical faciobrachial dystonic seizures or tonic seizures.^{4,5,6}

Also, this case is a reminder of the fact that behavioural disturbances secondary to autoimmune encephalitis can very frequently be labelled as a psychiatric illness unless the index of suspicion is very high.

MRI IMAGE OF CASE1- MRI FLAIR sequence showing bilateral symmetrical medial temporal and hippocampal hyperintensities



CASE 2-"THE GENTLEMAN WHO KEPT ON NODDING"

50 year old farmer presented with history of abrupt onset movements of the head resembling nodding which were followed by deviation of the head towards left side with absent staring look, subsequently there would be vocalisation in the form of illegible utterances lasting few seconds. Such episodes would be repeated 2-3 times each day. For these symptoms, on consulting a nearby hospital facility, he was started on the antiepileptic levitiracetam given orally in the dosage of 500mg twice daily.

1 week into the illness, he developed forgetfulness, irrelevant talk and it was at this juncture that he presented to our center.

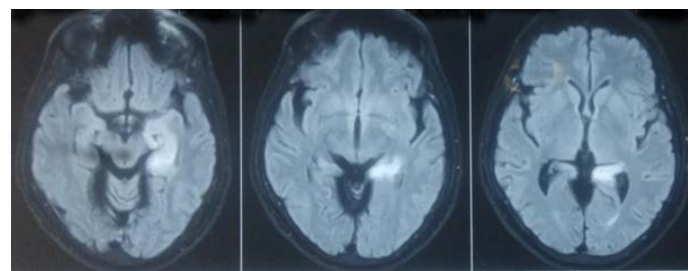
On examination - there were no lateralising deficits elicited, also there were no signs of meningeal irritation. Detailed cognitive assessment was not possible at presentation as he was in frank delirium.

Complete blood count and ESR were unremarkable. The conspicuous finding in this case was persistent severe hyponatremia. Initial sodium value at presentation was 113 MEq (Milliequivalents) which improved to 124 MEq on correction with hypertonic saline administration. However normalisation of the values to 136MEq took more than 1 week despite intravenous correction.

MR imaging showed asymmetric T2 and FLAIR hyperintensity of the left hippocampus with partial diffusion restriction. Electroencephalogram showed non specific diffuse slowing and no interictal epileptiform discharges (IEDs) were visualised.

CSF examination showed occasional lymphocytes and biochemical studies were normal. CSF LGII antibody was found to be positive, serum antibody was negative.

He was treated with pulse intravenous methylprednisolone followed by oral steroids. On initiation of immunotherapy and correction of hyponatremia, his delirium gradually improved. Levitiracetam was switched to intravenous preparation and the dose was hiked to 500mg 3 times daily which led to control of the seizures. At discharge his MMSE was 24/30.



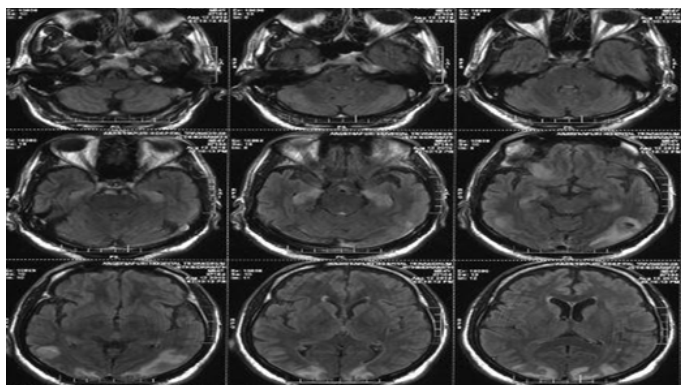
CASE2 MRI-brain axial FLAIR sequence showing left hippocampal hyperintensity

CASE 3-"THE GENTLEMAN WITH FOCAL TWITCHING"

64 yr old male presented with history of involuntary jerky movement involving right upper limb and right side of face with head turn to right. Awareness was preserved during each of these episodes. These episodes were brief and frequent, lasting few seconds.

There was no history of fever, headache or preceding

trauma. He reported past history of diabetes mellitus , systemic hypertension and coronary artery disease.He was started on antiepileptic medication for the seizures.However his sensorium worsened subsequently and he went on to develop generalised tonic -clonic seizures.Initial neurological examination was unremarkable except for the recurrent right facio-brachial dystonic seizures.There was no lateralising neurological deficit,no signs of meningeal irritation were elicited. Routine blood investigations were within normal limits.The initial MRI done from another hospital facility did not show any abnormality.However the electroencephalogram showed



MRI FLAIR SEQUENCE-CASE3-Bilateral medial temporal along with parieto-occipital FLAIR hyperintense lesions
TABLE1-SUMMARY OF CLINICAL DETAILS AND INVESTIGATIONS

Patient	Clinical presentation	Mri findings	Eeg findings	Other investigations
1.female,48yrs	Memory disturbance,apathy, Focal seizure with impaired awareness and piloerection	Bilateral medial temporal lobe ,insular T2,FLAIR hyperintense lesions	B i t e m p o r a l slowing	Serum,csf lgi1 antibody positive Ana ,dsdna positive
2.male,50 yrs	Focal seizures involving head region followed by delirium	Unilateral left medial temporal lobe t2,flair hyperintense lesions	Delta grade slowing	Csf lgi1 antibody positive Serum lgi1 negative Severe hyponatremia
3.male,64 yrs	Right faciobrachial dystonic seizures followed by delirium	Bilateral medial temporal lobe and parieto-occipital t2,flair hyperintensities	Bilateral temporal sharp waves	Serum lgi1 antibody positive Csf testing-not done

Discussion

After the initial description in 2010¹,LGI1 antibody encephalitis syndrome has now been well characterised and the disease course and long term prognosis has been reported in literature³.The condition should always be considered in any middle age or elderly individual presenting with insidious onset memory or behavioural disturbances .The index of suspicion should be very high in cases who have a rapid evolution of cognitive abnormalities and when preliminary workup for infective,metabolic and endocrine causes turns out to be negative.

COGNITIVE ABNORMALITIES

The first case of the middle aged lady with insidious onset behavioural abnormalities remaining undiagnosed for 8 months is a reminder of the fact that LGI1 antibody encephalitis presenting as behavioural disturbance can very well be mistaken for a primary psychiatric illness especially if co-existing seizures or involuntary movements are not prominent in the initial phase

bilateral temporal interictal epileptiform discharges(IEDs).The serum LGI1 antibody was strongly positive,CSF antibody testing was not done. MR imaging was again repeated after 1 week in view of persistent encephalopathy which showed bilateral medial temporal lobe T2 and FLAIR hyperintensities along with posterior parieto-occipital hyperintensities with evidence of blooming artefact on susceptibility weighted sequences.

The lesions did not show diffusion restriction and there was no significant enhancement of the lesions on contrast imaging.Possibility of vasogenic edema secondary to posterior reversible encephalopathy syndrome (PRES) was considered to account for these posterior cortical lesions as subsequent imaging showed resolution of these .

Immunotherapy was initiated- initially intravenous methylprednisone for 5 days followed by intravenous immunoglobulin in the dose of 0.4 mg/kg was administered. He made a gradual recovery with improvement in mental status,however persistent right upper limb focal seizures prompted hiking up of antiepileptic medications with sodium valproate and lacosamide being added along with leviteracetam. MMSE was 28/30 at discharge with complete remission of the seizures.

of the illness. Cognitive abnormalities including memory,behavioural disturbances or seizures are the presenting manifestation in majority of cases.Patients may be apathetic,display dishinhibited or socially inappropriate behaviour .Very often,visuospatial disorientation can lead to patients getting lost in familiar surroundings.Deficits in various cognitive domains including verbal memory,visual memory,executive function and attention have been reported on long term follow up.Patients may report persistent amnesia for the period of the disease as dysfunction of the LGI1 receptor complex may interfere with long term potentiation and long term depression.³

SEIZURE TYPES

Various types of seizures have been described in association with LGI1 antibody encephalitis .Faciobrachial dystonic seizures(FBDS) have classically been associated with this illness.FBDS are involuntary contractions of 1–2 seconds,affecting the unilateral arm (or leg) and face,occurring up to 100 times a day, but often unrecognized by patients and

physicians. . Faciobrachial dystonic seizures (FBDS) are very specific for anti-LGI1 encephalitis, although only present in a minority of the patients. Irani et al⁷ coined the term faciobrachial dystonic seizure as these events often lack an EEG correlate and could very well have a subcortical origin. Whether these events should be classified as seizures or movement disorder is still a matter of contention. These events respond better to immunotherapy rather than antiepileptic treatment as was the case in our third patient whose seizures were controlled completely only after immunotherapy was stepped up after initial treatment with intravenous corticosteroid on initiation of intravenous immunoglobulin.

FBDS was the predominant seizure type in the third case described and its early recognition in the disease course lead to appropriate diagnostic antibody workup and initiation of immunotherapy.

Other seizure types reported include focal tonic seizures, tonic-clonic seizures with secondarily generalisation, focal seizures with dyscognitive features, pilomotor seizures, autonomic seizures, gelastic seizures etc.

The unique finding of pilomotor seizures occurring in LGI1 antibody disease has been increasingly realised. Piloerection during the stereotyped upper limb movements in the first case described were the single most important diagnostic clue leading to diagnosis as no specific EEG correlate could not be obtained despite repeated video-EEG recordings. These events could very well have been mistaken as psychogenic non epileptic events given the background history of behaviour symptoms.

Our second case was characterised by focal seizures involving the head region evolving to secondary generalised tonic clonic movements and progressive alteration in sensorium. This case was characterised by persistent and severe hyponatremia. This metabolic abnormality has been reported to occur in around 65 percentage of cases and could be due to expression of the LGI1 receptor in hypothalamus and kidney, antibody binding to the receptor leading to syndrome of inappropriate antidiuretic hormone secretion (SIADH). Certain authors feel that to some extent, the degree of hyponatremia correlates with the severity of disease and improvement in hyponatremia also occurs in close conjunction with clinical improvement.

SEROLOGY

Coexisting antibodies along with LGI1 can be seen in upto 10 percentage of cases and these include antinuclear antibody (ANA), thyroid peroxidase antibody (TPO), GAD65 (glutamic acid decarboxylase 65). Case 1 demonstrated positivity of ANA by immunofluorescence method along with double stranded DNA antibody. These may reflect expansion of the autoimmune disease process and whether these have a role in the disease pathogenesis is a matter of speculation.

Even though LGI1 antibody disease is classically non-paraneoplastic, screening for coexisting tumors is also of paramount importance as upto 20% cases may harbour malignancies of the lung, thymus, neuroendocrine tumors etc. CT-Thorax and abdomen along with tumor markers may serve the purpose for initial screening, however occult lesions may only be picked up on FDG-PET imaging.

NEUROIMAGING

Magnetic resonance imaging showed medial temporal lobe involvement in all our three cases-bilateral in cases 1 and 3 and unilateral in Case 2. This is consistent with the classical imaging described in literature

However, the third case differed with more extensive involvement beyond the medial temporal lobes with involvement of the bilateral parietoccipital regions. These lesions also showed partial diffusion restriction with blooming artefact on susceptibility weighted sequence

The multifocal cortical, subcortical lesions could possibly have been due to vasogenic edema secondary to inflammatory cytokines such as Interleukin-6-8 which are increased in patients with autoimmune encephalitis, which could induce oxidative stress and endothelial dysfunction. Previously, Jaeho Kim et al⁹ has described PRES-like lesions in association with LGI1-antibody associated autoimmune encephalitis.

Conclusion

LGI1 antibody encephalitis should be considered in differential diagnosis of middle age to elderly patients presenting with seizures, behavioural abnormalities and imaging evidence of temporal lobe involvement. Prompt recognition and treatment with immunotherapy leads to improved outcome.

Reference

1. Lai M, Huijbers MG, Lancaster E, Graus F, Bataller L, Balice-Gordon R, Cowell JK, Dalmau J. Investigation of LGI1 as the antigen in limbic encephalitis previously attributed to potassium channels: a case series. *Lancet Neurol.* 2010 Aug;9(8):776-85. doi: 10.1016/S1474-4422(10)70137-X.
2. Geschwind MD, Tan KM, Lennon VA, Barajas RF Jr, Haman A, Klein CJ, Josephson SA, Pittock SJ. Voltage-gated potassium channel autoimmunity mimicking creutzfeldt-jakob disease. *Arch Neurol.* 2008 Oct;65(10):1341-6. doi: 10.1001/archneur.65.10.1341. PMID: 18852349
3. van Sonderen A, Thijs RD, Coenders EC, Jiskoot LC, Sanchez E, de Bruijn MA, van Coevorden-Hameete MH, Wirtz PW, Schreurs MW, Sillevs Smitt PA, Titulaer MJ. Anti-LGI1 encephalitis: Clinical syndrome and long-term follow-up. *Neurology.* 2016 Oct 4;87(14):1449-1456. doi: 10.1212/WNL.0000000000003173.
4. Wieser S, Kelemen A, Barsi P, Vincent A, Borbely C, Rasonyi G, Mueller S, Hess K, Wieser HG, Halasz P. Pilomotor seizures and status in non-paraneoplastic limbic encephalitis. *Epileptic Disord.* 2005 Sep;7(3):205-11. PMID: 16162429.
5. Rocamora R, Becerra JL, Fossas P, Gomez M, Vivanco-Hidalgo RM, Mauri JA, Molins A. Pilomotor seizures: an autonomic semiology of limbic encephalitis? *Seizure.* 2014 Sep;23(8):670-3. doi: 10.1016/j.seizure.2014.04.013.
6. Aurangzeb S, Symmonds M, Knight RK, Kennett R, Wehner T, Irani SR. LGI1-antibody encephalitis is characterised by frequent, multifocal clinical and subclinical seizures. *Seizure.* 2017 Aug;50:14-17. doi: 10.1016/j.seizure.2017.05.017.
7. Irani SR, Michell AW, Lang B, Pettingill P, Waters P, Johnson MR, Schott JM, Armstrong RJ, S Zagami A, Bleasel A,

8. Wassmann S, Stumpf M, Strehlow K, Schmid A, Schieffer B, Böhm M, Nickenig G. Interleukin-6 induces oxidative stress and endothelial dysfunction by overexpression of the angiotensin II type 1 receptor. *Circ Res.* 2004 Mar 5;94(4):534-41. doi: 10.1161/01.RES.0000115557.25127.8D.
9. Kim J, Lee ST, Park S, Joo EY, Chung CS, Lee MJ. Posterior reversible encephalopathy syndrome as initial manifestation of autoimmune encephalitis. *Neurol Clin Pract.* 2019 Oct;9(5):e42-e44. doi: 10.1212/CPJ.0000000000000609.