


# An eminent rendezvous with a series of cranial vault remodeling for Craniosynostosis



Bishal Shrestha<sup>1</sup> , Pritam Gurung<sup>2</sup> , Jessica Kayastha<sup>3</sup> , Aditi Agrawal<sup>4</sup> , Resha Shrestha<sup>5</sup> ,  
Sudan Dhakal<sup>6</sup> , Pravesh Rajbhandari<sup>7</sup> , Samir Acharya<sup>8</sup> , Pranaya Shrestha<sup>9</sup> , Basant Pant<sup>10</sup> 

<sup>1,2,3,4,5,6,7,8,9,10</sup>Department of Neurosurgery, Annapurna Neurological Institute and allied Sciences, Kathmandu, Nepal

Date of submission: 1<sup>st</sup> March 2022

Date of acceptance: 6<sup>th</sup> June 2022

Date of publication: 25<sup>th</sup> June 2022

## Abstract

In defiance with the meager tally of craniosynostosis, the surgical treatment of non syndromic craniosynostosis is one of the most common maneuvers encountered by craniofacial surgeon. Owing to anomalous anatomy secondary to the imperfection in embryogenesis, a long haul of drill is required to obtain perfection in surgical sequel.<sup>1</sup>

With the advancement in neurosurgical gadgetry and improvement in agility of neurosurgical authority, a multitude of strategy has evolved over time with the eminent intent to bring forth the supreme aftermath.

Browsing through the archives of craniofacial reconstruction discloses vault remodeling techniques evolving over time with disparate modification tactics to the inception of state-of-the-art strategies like endoscopic suturectomy, spring treatment and cranial vault distraction osteogenesis.<sup>2</sup>

Regardless of all these alternatives, we still resort to the standard cranial vault remodeling with a fairly approving outcome. We herein attempt to disclose our result of vault remodeling in a series of patients with craniosynostosis.

**Key words:** Craniosynostosis, Vault remodeling, Craniofacial surgery

## Introduction

Designated as a developmental craniofacial anomaly, craniosynostosis occurs as a repercussion due to premature closure of one or more cranial sutures embarking into an abnormally shaped skull with impaired brain development.<sup>5</sup> An anticipated pattern of craniofacial growth occurs delimited by the untimely fusion of these sutures. It can present as an isolated condition or may also

be a part of complex syndromes.<sup>6</sup> The surgical remedy for non syndromic craniosynostosis is obligatory owing to the fact that if untreated, it can lead to developmental delay, facial abnormality, sensory, respiratory and neurological dysfunction, anomalies affecting the eye, and psychological disturbances.

A diverse array of conjectures have been postulated by different authorities, however, it was Sir Rudolf Virchow, in 1859, who codified general rules to explain cranial deformities. He dictated that the growth of skull typically is restricted perpendicular to the pathological suture with compensatory growth along non fused sutures in a direction parallel to the affected suture.<sup>7</sup>

With the refinement in razor sharp surgical artistry, the standard vault remodeling with fronto orbital advancement, despite being a primordial technique, the consequence is comparable with the noble minimally invasive procedures, even more so with a cut above the rest.

## Methods

A retrospective series study was conducted at Annapurna Neurological Institute and Allied Sciences in the last 3 years. A total of 3 patients who underwent surgery for non syndromic craniosynostosis were enrolled. Standard fronto orbital advancement with vault remodeling was elected in all the cases.

### Access this article online

Website: <https://www.nepjol.info/index.php/NJN>

DOI: <https://doi.org/10.3126/njn.v19i2.42999>

### HOW TO CITE

Shrestha B, Gurung P, Kayastha J, Agarwal A, Shrestha R, Dhakal S, Rajbhandari P, Acharya S, Shrestha P, Pant B. An eminent rendezvous with a series of cranial vault remodeling for Craniosynostosis. NJNS. 2022;19(2):55-61.



### Address for correspondence:

Bishal Shrestha

Annapurna Neurological Institute and allied Sciences

Kathmandu, Nepal

E-mail: cantona7best@gmail.com

Copyright © 2022 Nepalese Society of Neurosurgeons (NESON)

ISSN: 1813-1948 (Print), 1813-1956 (Online)



This work is licensed under a Creative Commons Attribution-Non Commercial 4.0 International License.

**Preoperative Evaluation**

Foregoing surgery, all patients underwent a set pattern of thorough neuropsychological, ophthalmological, and radiological assessment to avoid overlooking the clues.<sup>3</sup> General examinations involving the face for dysmorphic features to determine craniosynostosis and features of an associated anomaly including examination of hand and feet is attained. The size, shape and tension in the fontanelles are assessed. An utmost scrutiny to decide whether or not the patient is a candidate with features of raised intra cranial pressure for emergent surgical intervention is accomplished.<sup>4</sup> CT scan of the head and three dimensional reconstruction using both bone and soft tissue windows is the investigation of choice. An auxiliary CT venogram can be done if a suspicion of abnormal venous drainage is speculated.<sup>5</sup>

**Results**

The age of presentation among our study group ranged from 15 months to 2 years. The most frequent mode of

presentation was an abnormally shaped skull with delayed developmental milestones. One of the cases had difficulty supporting his head with multiple episodes of vomiting. No significant intra operative blood loss was noted. Post operatively, the new construct was cosmetically acceptable.

**Illustrative Cases:**

**Case 1**

An 18-months-old boy was brought to our out-patient department with the chief complaints of pointed contour of his forehead since birth which is exacerbating overtime. It was associated with developmental milestone. His parents also stated multiple episodes of vomiting for 1 week.

His birth history was unremarkable and was being immunized as per EPI schedule.

CT scan of head with 3D reconstruction including bony window was performed which revealed Non visualization of the metopic suture and anterior fontanelle with triangular appearance of the frontal skull.

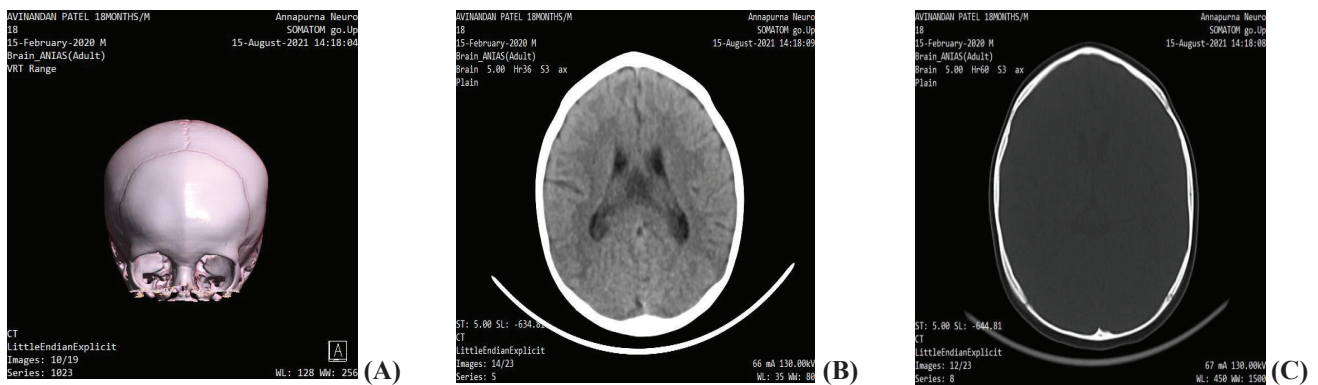
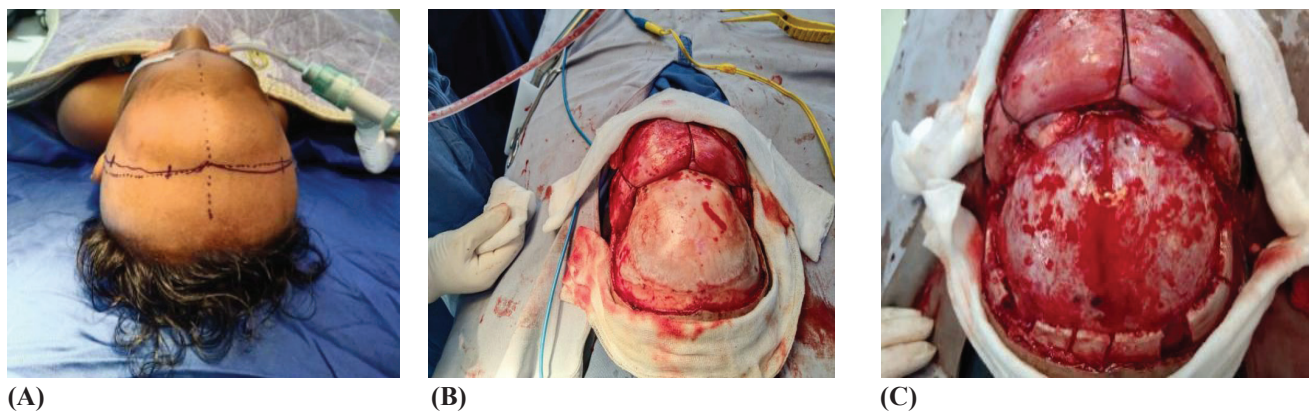
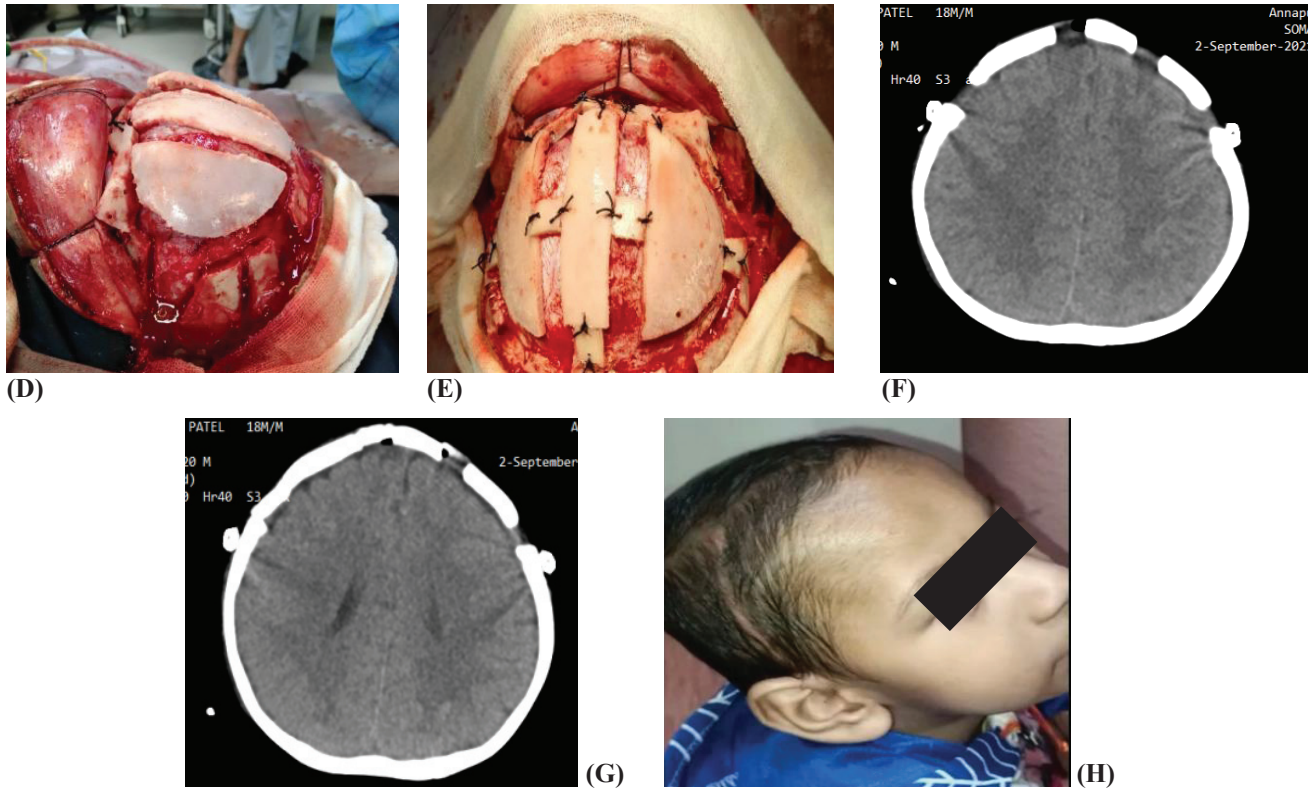


Figure (A) 3D reconstruction, Figure (B) CT scan of brain and Figure (C) showing non visualization of metopic suture and anterior fontanelle with triangular appearance of the frontal skull and normal brain parenchyma suggestive of trigonocephaly.

**Operative Procedure**

Fronto orbital advancement with cranial vault remodeling



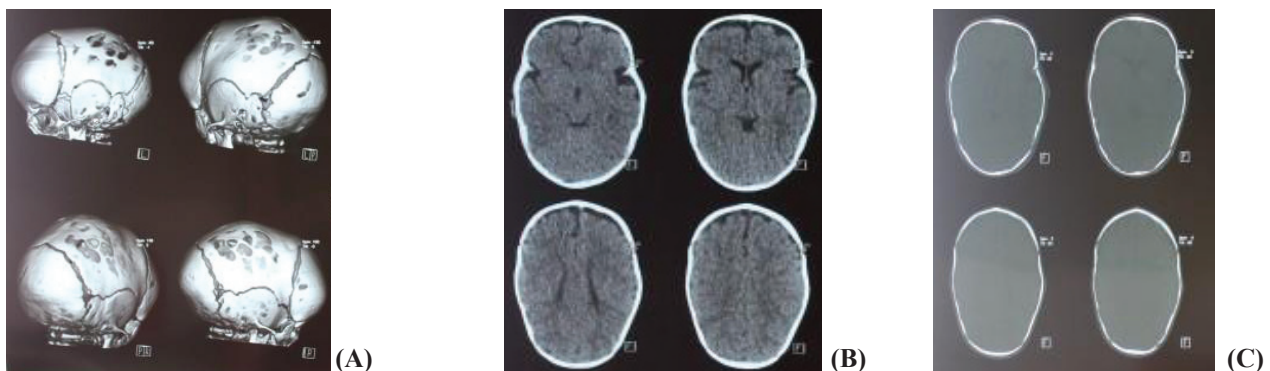


*Figure (A) Supine position with Bicoronal incision mark, Figure (B) Reflecting the frontalis muscle up to supra orbital ridge, Figure (C) Multiple strip craniectomies at the calvarial part of frontal bone, Figure (D) Correction at the level of frontal bandeau with advancement of supra orbital bar with green stick fractures made at lateral orbital walls to correct the bi temporal constriction and normalize contour, Figure (E) Use of suture for calvarial reconstruction instead of mini plates and screws to bring down the cost of surgery, Figure (F) and (G), Post-operative CT scan of head revealing a well decompressed cranium, Figure (H) Post-operative correction of trigonocephaly*

**Case 2**

A 15-months-old boy was brought to our out-patient department with the chief complaints of bulging in the frontal region. Birth history revealed caesarean section performed with the diagnosis of cord around the neck. His developmental milestone is normal and is being immunized as per EPI schedule.

CT scan of head with 3D reconstruction and bone window revealed premature fusion of sagittal suture suggestive of a dolichocephalic skull with rounded to oval pits in biparietal region suggestive of dysplasia of membranous skull vault.

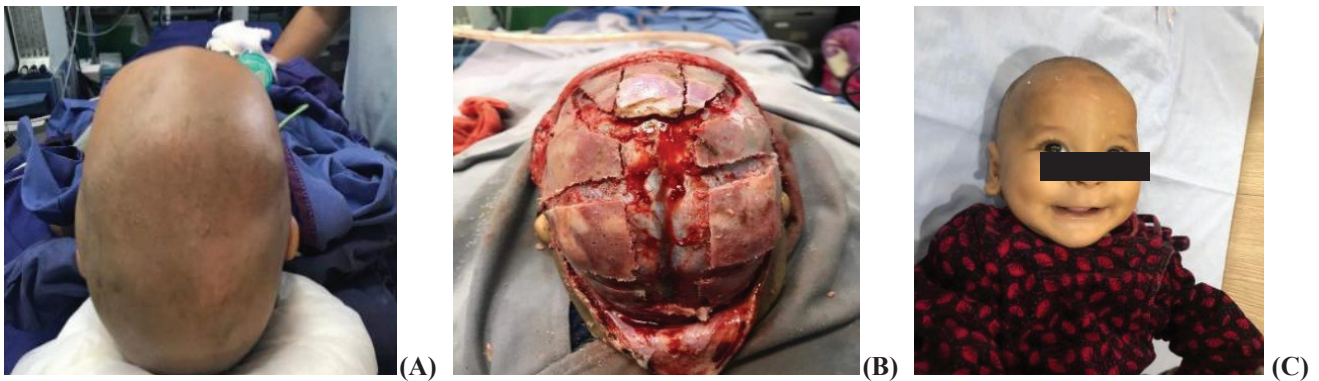

*Fig (A) CT 3D reconstruction of skull showing premature fusion of sagittal suture suggestive of dolichocephalic skull with multiple oval pits in parietal region suggestive of dysplastic changes, Fig (B) and Fig (C) CT scan of brain and bony window revealing normal brain parenchyma with a boat shaped skull*



**Operative Procedure**

Cranial Vault remodeling



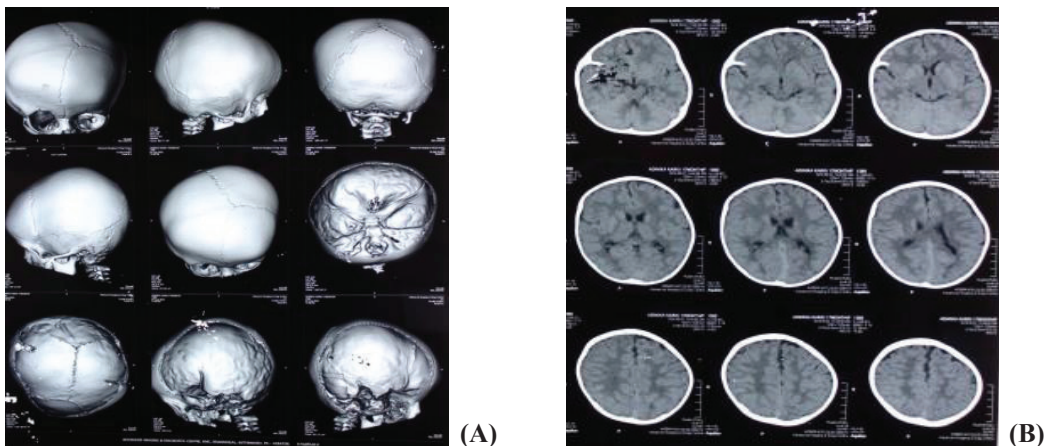
*Figure (A) Positioning of the patient and dolichocephalic appearance of the skull, Figure (B) Multiple strip craniectomies performed to decompress the cranial vault, Figure (C) Post operative well contoured and rounded appearance of the skull*

**Case 3**

A 2-years-female girl was presented to our institution with the complaints of flattened right frontal region and an expanded left frontal region with protrusion of right eye ball since birth with progressive worsening of the deformity. Birth history revealed history of caesarean

section done for oligohydraminos. Her developmental milestone is normal. She is being immunized as per EPI schedule.

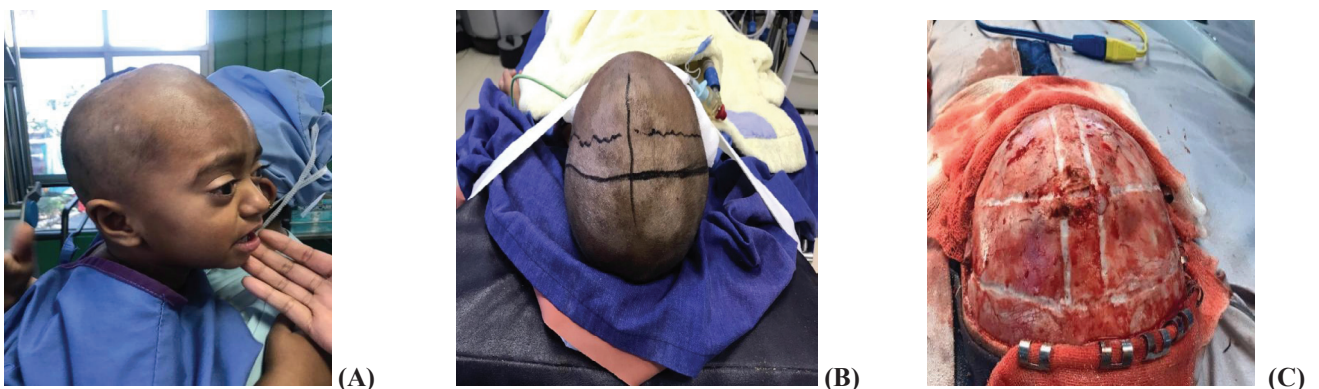
CT scan of head with 3D reconstruction and bone window revealed premature fusion of the right coronal suture with a normal brain parenchyma.

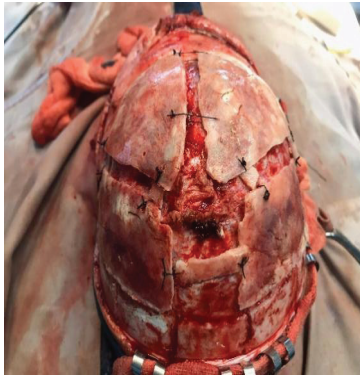

*Figure (A) CT 3D reconstruction revealed premature fusion of right coronal suture with backward displacement of left orbit and forward protrusion of right orbit, Figure (B) CT head revealing a normal brain parenchyma.*

**Operative Procedure**

Cranial vault remodeling





(D)



(E)

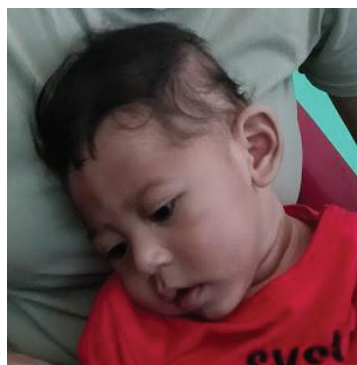Figure (A) Preoperative deformity, Figure (B) Positioning and incisional marking, Figure (C) Planning of strip craniectomies, Figure (D) Multiple strip craniectomies with well decompressed vault with reconstruction using sutures, Figure (E) During follow up

**Exclusive Case**

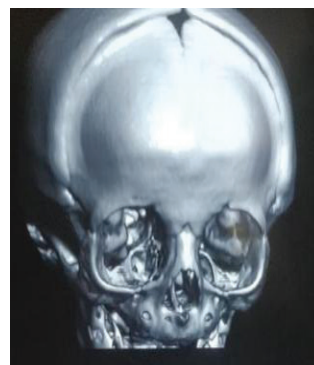
A 9-months-old baby boy was brought to our institution with an uneventful birth history but with the complaints of poor developmental milestone and a deformed shape of the skull. Compared to his peer groups, he was unable to support his head nor could he crawl or stand up. They also

added that he could not verbalize and was difficult to feed him. He is being immunized as per EPI schedule.

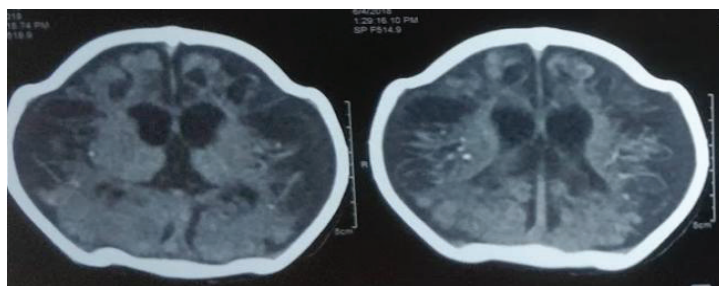
CT scan of head with 3D reconstruction revealed premature fusion of the metopic suture and the brain parenchyma was grossly flawed.



(A)



(B)



(C)

Figure (A): A pitiful infant with an impoverished outlook, Figure (B): CT 3D reconstruction showing fused metopic suture with abnormal skull architecture, Figure (C) CT scan of head revealing globally debilitated brain parenchyma



### Agreement In Exclusive Case

The proposition to undergo vault remodeling in this case was withheld unequivocal considering the utterly defunct shape of his brain as we thought it was futile to bestow an immaculate skull contour while the brain inside is irrevocably flawed.

### Conclusion

The standard cranial vault technique is a safe procedure to operate on a child and can yield excellent correction of synostosis with an acceptable cosmesis. The use of suture materials as a substitute for mini plates and screw can chop down the cash drain considering bearing in mind the indigent repute of our community. A judicious scrutiny is inescapable prior to decide to put on a scar to furnish a cosmetically decent skull contour as it would not be sublime at all with a kaput brain inside.

### Discussion

In the 18<sup>th</sup> century, Sir Rudolf Virchow, first conceived the term Craniosynostosis, to narrate an abnormally shaped skull emanating from premature fusion of one or more of the cranial sutures. It was the personage himself who mandated the fundamental principle of cranial deformities with the dictum that the growth of skull is restricted perpendicular to the pathological suture along with compensatory growth along non fused sutures. This postulate has remained authentic over 150 years now.<sup>8</sup> Grounded by the number of sutures involved it can be categorized into simple or complex sutures. On the other hand, it can be stratified into Syndromic or Non syndromic established by the association with syndromes. Apert syndrome, Crouzon syndrome, Pfeiffer syndrome, Carpenter syndrome and Muenke syndrome are to name a few of the syndromes kindred with the malformation.<sup>9</sup> Consequently, a conscientious evaluation should be attained to steer clear disregard the clues.

Surgical correction of deformity should act in accordance with the foundational principle to decompress the cranial vault to release the increased intracranial pressure with long term cosmetic result at nominal liability.<sup>10</sup>

Historically, coronal incision introduced in 19<sup>th</sup> century to expose the brain marked the milestone in the chronicles of craniofacial surgery.<sup>1</sup> Matson commenced strip craniectomies but it buckled into inconsistent results. Tessier popularized the approach with favorable treatment in Apert and Crouzon syndrome associated synostosis. Further breakthrough refinement unfolded over the years when the concept of cranial vault remodeling augmented by lateral canthal advancement or mobilization of semicircular frontal bandeau materialized with admissible

outcome.<sup>1</sup> Technical alterations and refashioning is incessant with noble approaches proclaimed with encouraging sequel. In recent times, with the advent of newer technology, endoscopic assisted suturectomy, spring assisted craniectomy and vault remodeling based on the principle of distraction osteogenesis has emerged into light.<sup>11</sup>

Once the ideal candidate is confirmed after studious workup, vault reconstruction is planned. With patient in supine position head rest, under general anesthesia, infiltration of local anesthesia with a vasoconstrictor along the planned skin incision is done. Bicoronal incision behind coronal suture followed by sub galeal dissection is extended up to the orbits. Then a periosteal flap is raised with incision behind coronal sutures and exposing the underlying calvarium. Supraorbital nerves are identified and protected. The contents of the walls of orbit are freed with sub periosteal dissection. On the lateral aspect, the temporalis fascia is incised and muscle is gently elevated in sub periosteal fashion to expose the temporal fossa and squamosal sutures. Medially, the nasofrontal suture junction is unveiled. The orbital bandeau is identified and marked 1 cm above the orbital rims, and the margin for en bloc craniotomy of frontal bone is planned.

Foregoing burrs are created in keyhole and bifrontal craniotomy is accomplished along with entire forehead en bloc such that all the involved sutures are released. Osteotomies of zygomatico frontal sutures including the walls (medial and lateral) and roof of the orbit is attained. Osteotomy of the nasofrontal suture creates a bandeau that allows correction of the deformity due to synostosis by the formation of a supraorbital bar. Multiple finger like osteotomies of the frontal bone is carried out and refashioned as required bilaterally contemplating to procure a cosmetically admirable superiority. Small bone bars are refashioned along the nasofrontal suture or the calvarium if further expansion is indispensable. The reconstruction of the vault is concluded by connecting all the fragments in desired locale using sutures instead of mini plates and screws to downturn the cost of the procedure. After proper hemostasis, temporalis muscle flap is mobilized and mobilized superiorly followed by redraping of the pericranial scalp flap into suitable anatomic orientation. A sub galeal drain is kept to be removed on second post-operative day. Scalp is closed in layers

Meticulous soft tissue dissection with congenial exposure and an outright hemostasis was outlined en route the procedure to fight shy of redundant tissue injury and curtail copious blood loss. An endeavor to cut short the operative time to minimize anesthetic hazard was emphasized over and above that. A reasonable silhouette of the skull is validated immediately at the end of surgery.

In lieu of extensive dissection, peri orbital edema and ecchymosis is anticipated. A considerate and cautious

surgical approach bit-by-bit not only reduce the operative time frame but also attenuate the volume of blood loss and minimize the need for blood transfusion.

The cranial vault remodeling with frontal advancement was inaugurated a couple of decades ago. Technical discrepancy has been acquainted by different executives to contend with the sphere of craniosynostosis. Having said that, the primeval standard cranial vault remodeling still portray the foremost approach for infants with craniosynostosis. Affixing to this approach, we set our sight to narrow the surgical time frame, with an evident reduction in volume of blood loss and need for blood transfusion. When availing to this technique, we had a low complication rate and excellent correction of the blemish.

**Conflict of Interest:** None of the authors have potential conflicts of interest to be disclosed.

### References

1. Staffenberg DA, Hon D, Diaz-siso JR, Flores RL. Fronto-Orbital Advancement : Description of Surgical Technique to Complement the Procedural Cognition Simulation in the Craniofacial Interactive Virtual Assistant- Professional Edition. 2019;30(2):473-477.
2. Barone CM, Jimenez DF. Endoscopic craniectomy for early correction of craniosynostosis. *Plast Reconstr Surg.* 1999;104(7):1965. <https://doi.org/10.1097/00006534-199912000-00003>
3. Whitsell N, Meyer L. Craniosynostosis - A Review for Providers. *S D Med.* 2021;74(2):83-88.
4. Hughes CD, Langa O, Nuzzi L, et al. Evaluating Surgical Decision-making in Nonsyndromic Sagittal Craniosynostosis Using a Digital 3D Model. *Plast Reconstr surgery Glob open.* 2021;9(5):e3493. <https://doi.org/10.1097/GOX.0000000000003493>
5. Johnson D, Wilkie AOM. Craniosynostosis. *Eur J Hum Genet.* 2011;19(4):369-376. <https://doi.org/10.1038/ejhg.2010.235>
6. Kajdic N, Spazzapan P, Velnar T. Craniosynostosis - Recognition, clinical characteristics, and treatment. *Bosn J basic Med Sci.* 2018;18(2):110-116. <https://doi.org/10.17305/bjbms.2017.2083>
7. Paniagua B, Emodi O, Hill J, et al. 3D of Brain Shape and Volume After Cranial Vault Remodeling Surgery for Craniosynostosis Correction in Infants. *Proc SPIE--the Int Soc Opt Eng.* 2013;8672:86720V. <https://doi.org/10.1117/12.2006524>
8. Flaherty K, Singh N, Richtsmeier JT. Understanding craniosynostosis as a growth disorder. *Wiley Interdiscip Rev Dev Biol.* 2016;5(4):429-459. <https://doi.org/10.1002/wdev.227>
9. Sawh-Martinez R, Steinbacher DM. Syndromic Craniosynostosis. *Clin Plast Surg.* 2019;46(2):141-155. <https://doi.org/10.1016/j.cps.2018.11.009>
10. Kyutoku S, Inagaki T. Review of Past Reports and Current Concepts of Surgical Management for Craniosynostosis. *Neurol Med Chir (Tokyo).* 2017;57(5):217-224. <https://doi.org/10.2176/nmc.ra.2017-0006>
11. Jones VM, Thomas SG, Siska R, et al. Spring-Assisted Surgery for Treatment of Sagittal Craniosynostosis. *J Craniofac Surg.* 2021;32(1):164-167. <https://doi.org/10.1097/SCS.0000000000007096>