


Textiloma Misdiagnosed as Paraspinal Abscess During the Period of COVID-19 Pandemic: Case Report



Murat Ö. Yay¹ , Sinan Sağıroğlu¹ , Mehmet Turgut^{1,2} 

¹Department of Neurosurgery, Aydın Adnan Menderes University Faculty of Medicine, Efeler, Aydın, Turkey

²Department of Histology and Embryology, Aydın Adnan Menderes University Health Sciences Institute, Efeler, Aydın, Turkey

Date of submission: 17th January

Date of acceptance: 22nd February

Date of publication: 15th March 2022

Abstract

Retained surgical sponge and consequent foreign body reaction is a well-documented complication. In the current literature, the phenomenon has many names such as textiloma, gossypiboma, gauzoma, and muslinoma. While it is one of the widely reported topics, only a few cases are reported by neurosurgeons. Herewith we present a case of textiloma in Turkey who had repeated surgical interventions at various hospitals during the COVID-19 pandemic, possibly due to breakdown of preventive measures against retention of surgical sponge.

Key words: Gauzoma, Gossypiboma, Muslinoma, Retained surgical sponge, Textiloma

Introduction

The textiloma is the reaction to the retained surgical sponge, one of the non-absorbable hemostatic materials types. Other synonyms for textiloma are gossypiboma, gauzoma, muslinoma.¹ The incident was reported to 0.7/10000 patients but the actual incidence was probably underestimated.² This condition may result in the abscess formation in the paravertebral region.³ It is believed that textiloma has acute and chronic types.⁴ In some cases, diagnosis of textiloma may be difficult due to its nonspecific nature and the treatment of this complication is vital.^{1,3}

We herewith present a case of spinal textiloma with a history of operations five times with the diagnosis of paraspinal abscess following lumbar discectomy at the L4-5 level at other institutions during the period of COVID-19 pandemic.

Case Report

A-49 year-old woman who is a teacher was admitted to our hospital with complaints of low back pain and non-healing surgical area infection. She had undergone right hemilaminectomy and discectomy for L4-5 intervertebral disc herniation at another hospital in 2019. After this operation, she had severe low back pain and the unhealing surgical area. Afterward, four more interventions were performed in various centers with the diagnosis of the postoperative paraspinal abscess in 2020. First, she was performed surgical debridement with local anesthesia. Due to persisting purulent discharge, she has undergone another surgery at this center. The latter two operations were under general anesthesia at a different center. The patient received intravenous antibiotics during follow-up and was discharged with ciprofloxacin. Two weeks before admission to our hospital, a percutaneous aspiration was performed with the help of ultrasonography (USG), under oral antibiotic therapy, but there was no reproduction in the culture. She was admitted to the infectious diseases department and was consulted with our department for surgical intervention. The patient was under intravenous ciprofloxacin and clindamycin treatment.

Physical examination indicated low back pain and there was a focal swelling over the unhealed incision scar area. Neurological examination revealed that the Laseque sign was positive 45 degrees on both legs, but there was no weakness or sensory loss. Routine blood analysis revealed a white blood cell count of 6.780 per cubic millimeter, a C-reactive protein level of 144, and an erythrocyte sedimentation rate of 79 mm/h. Magnetic resonance imaging (MRI) demonstrated a mass lesion related to the previous surgical area in the posterior paravertebral region at S1 and S2 segments. Following

Access this article online

Website: <https://www.nepjol.info/index.php/NJN>

DOI: <https://doi.org/10.3126/njn.v19i1.42462>

HOW TO CITE

Turgut M, Yay M Özcan, Sağıroğlu S. Textiloma Misdiagnosed as Paraspinal Abscess During the Period of COVID-19 Pandemic: Case Report. *NJNS*. 2022;19(1):71-4.



Address for correspondence:

Mehmet Turgut, M.D., Ph.D.

Department of Neurosurgery, Aydın Adnan Menderes University Faculty of Medicine, 09010 Efeler, Aydın, Turkey.

E-mail: drmturgut@yahoo.com

Copyright © 2022 Nepalese Society of Neurosurgeons (NESON)

ISSN: 1813-1948 (Print), 1813-1956 (Online)



This work is licensed under a Creative Commons Attribution-Non Commercial 4.0 International License.

contrast material administration, T1-weighted MRI demonstrated an enhanced hyperintense rim around the hypointense center, corresponding a diagnosis of abscess formation (Figure 1).

During the surgical intervention, a retained sponge material was found within the paraspinal mass cavity, above the sacrum, and it was removed completely (Figures 2A and B). The cavity and surgical area were irrigated and the layers were closed anatomically. A specimen was sent for the pathological examination which revealed the presence of multinucleated giant cells and multiple foreign body

particles (Figure 2C). The culture of the material failed to produce bacterial growth. The patient was diagnosed with “textiloma”. The postoperative course was uneventful. Prophylactic antibiotic therapy with vancomycin and meropenem continued until the postoperative two months.

The patient made an excellent recovery and was able to resume her normal activity. A follow-up examination at two months after the last surgical intervention with a control MRI study confirmed typical post-op findings of posterior lumbar surgery (Figure 3).

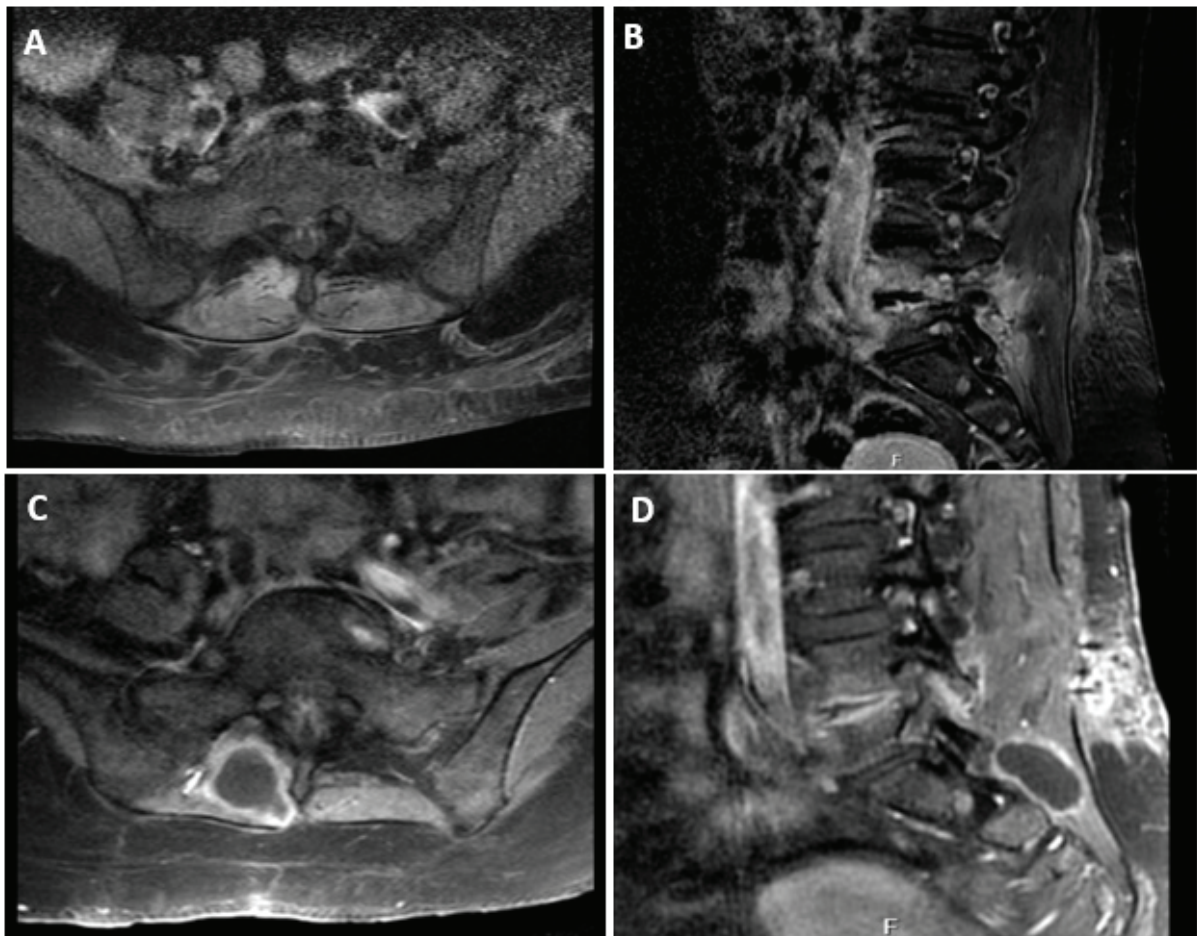


Figure 1 (A, B, C, D): Axial and sagittal T1-weighted with contrast sections of magnetic resonance imaging (MRI) are the after fifth operative early view. The axial and sagittal T1-weighted images with contrast enhancement showed a posterior paravertebral mass with a peripheral rim in the last MRI.

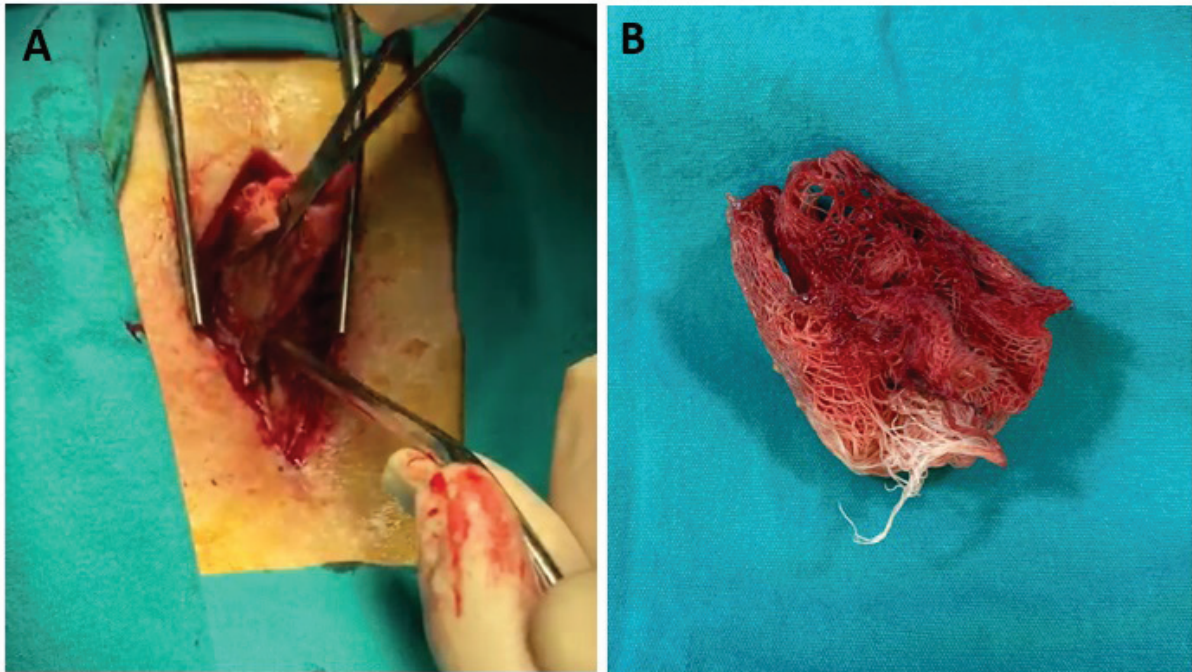


Figure 2 (A, B, C): Intraoperative view of the foreign body removed. A mass composed of retained surgical and inflammatory tissue. Pathological examination confirmed textiloma with the presence of fibrous tissue consisting multinuclear giant cells and histiocyte clusters covering the gauze.

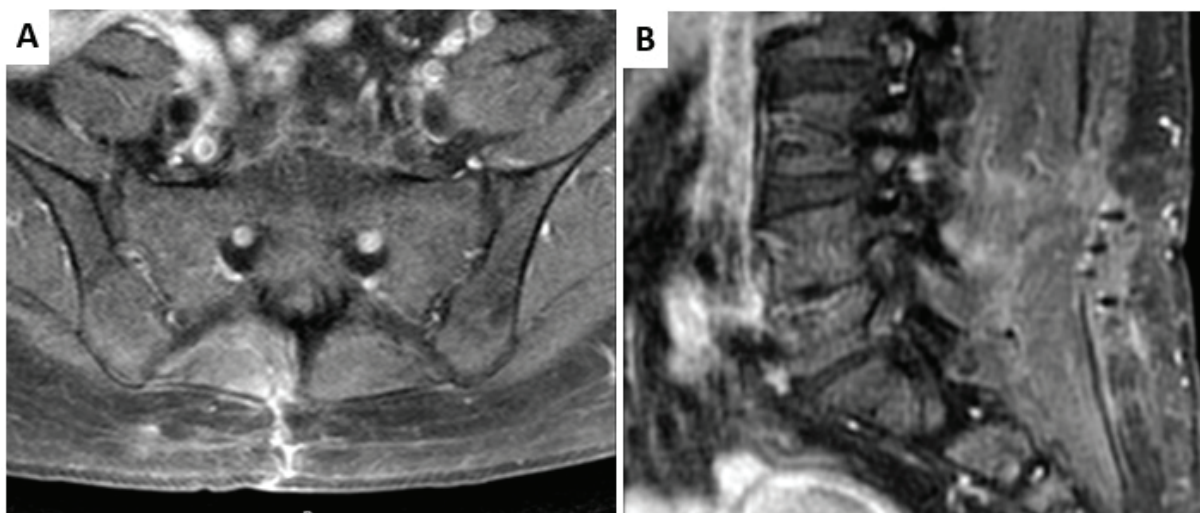


Figure 3 (A, B): Axial and sagittal T1-weighted MRI sections show that the postoperative lesion area.

Discussion

In spinal surgery, the incidence of retained foreign bodies following surgical intervention varies from 0.01% to 0.001% and textiloma is an uncommon complication.^{3,5,6,8} Some kinds of surgery which are abdominal, urological, gynecological, vascular, orthopedic, and spinal have been presented complications about textiloma.⁶ In the literature review, there are a small number of cases were reported by

neurosurgeons and radiologists.^{1,4,7} Gifford et al. reported the first case in 1973⁹ and Stoll reported that retained surgical sponge 40 years after laminectomy.¹⁰

There are many risk factors based on literature which are duration and complexity of the surgery, major blood loss in trauma patients, surgical urgency duration, a sudden change in the surgical intervention schedule, a change in management during surgery, presence of fatigue in the surgical personnel due to long duration

of the surgical procedure, inaccuracies in the count of the surgical sponges and instruments and existency of obese patient.¹¹⁻¹³ In this case, COVID-19 pandemic and preventive measures and procedures may be the cause of textiloma and repeated failed attempts.

The clinical picture of cases of variable and clinical symptoms can be nonspecific.¹ Common symptoms which may develop in the early postoperative period or following week, months, or years are back pain, weakness, and sensory deficits.¹⁴ The radiological diagnosis can be made by using USG, myelography, computed tomography, MRI, and positron emission tomography scans.¹ If the surgical sponge has a radiopaque, diagnosis can be by using only X-ray,¹⁵ but Luo et al. suggested that X-ray examination did not reveal small surgical sponges during surgery.¹⁶ Management of textiloma is very important and treatment is the surgical elimination of the foreign body, as did in the presented case.⁴

Conclusion

Textiloma as a complication occurs due to sub-optimal surgical conditions and greatly reduces the quality of life of the patient. COVID-19 measures in surgery rooms should not hinder standard surgical routine and sponge count.

Conflict of Interest: None

Source(s) of support: None

References

1. Turgut M, Akhaddar A, Turgut AT. Retention of nonabsorbable hemostatic materials (retained surgical sponge, gossypiboma, textiloma, gauzoma, muslinoma) after spinal surgery: a systematic review of cases reported during the last half-century. *World Neurosurg* 2018;116:255-67.
2. Ramire LF, Thisted R. Complications and demographic characteristics of patients undergoing lumbar discectomy in community hospitals. *Neurosurgery* 1989;25:226-31.
3. Turgut M, Akyüz O, Özsunar Y, Kacar F. Sponge-induced granuloma ("gauzoma") as a complication of posterior lumbar surgery – case report. *Neurol Med Chir (Tokyo)* 2005;45:213-5.
4. Lotfinia I, Mahdkhah A. Spinal textiloma after discectomy, a case report and review of literature. *World Neurosurg* 2019;8:227.
5. Naama O, Quamous O, Elasri CA, Boulahroud O, Belfkik H, Akhaddar A, *et al.* Textiloma: an uncommon complication of posterior lumbar surgery. *J Neuroradiol* 2010;37:131-4.
6. Kim HS, Chung TS, Suh SH, Kim SY. MR imaging finding of paravertebral gossypiboma. *AJNR Am J Neuroradiol* 2007;28:709-13.
7. Atabey C, Turgut M, Ilica AT. Retained surgical sponge in differential diagnosis of paraspinal soft-tissue mass after posterior spinal surgery: Report of eight cases. *Neurol India* 2009;57:320-3.
8. Nassar I, Mahi M, Semlali S, El Quessar A, Chakir N, El Hassani R, *et al.* Intracranial textiloma. A case report. *J Neuroradiol* 2004;31:148-9.
9. Gifford RR, Plaut MR, McLeary RD. Retained surgical sponge following laminectomy. *JAMA*. 1973;223:1040.
10. Stoll A. Retained surgical sponge 40 years after laminectomy. Case report. *Surg Neurol*. 1988;30:235-6.
11. Akhaddar A, Boulahroud O, Naama O, Al-bouzidi A, Boucetta M. Paraspinal textiloma after posterior lumbar surgery: a wolf in sheep's clothing. *World Neurosurg* 2012;77:375-80.
12. Akhaddar A, Oukabli M, Elmostarchid B, Albouzidi A, Boucetta M. Recurrent lumbosciatica because of cotton granuloma after surgery for lumbar disc herniation. *Spine J* 2011;11:363-4.
13. Gawande AA, Studdert DM, Orav EJ, Brennan TA, Zinner MJ. Risk factors for retained instruments and sponges after surgery. *N Engl J Med* 2003;348:229-35.
14. Kucukyuruk B, Biceroglu H, Abuzayed B, Ulu MO, Kafadar AM. Paraspinal gossypiboma: a case report and review of the literature. *J Neurosci Rural Pract* 2010;1:102-4.
15. Kobayashi T, Miyakoshi N, Abe E, Abe T, Suzuki T, Takahashi M, *et al.* Gossypiboma 19 years after laminectomy mimicking a malignant spinal tumour: a case report. *J Med Case Rep* 2014;8:311.
16. Luo WT, Almack R, Mawson JB, Cochrane DD. Radiographic detectability of retained neuropatties in a cadaver model. *World Neurosurg* 2015;84:405-11.