


# Ex-vivo Preservation Technique of Autologous Bone Flap in Resource Limited Settings: Retrospective Analysis of Outcome Based on Single Institute of Nepal



Sumit Joshi<sup>1</sup> , Prakash Paudel<sup>2</sup> , Damber Bikram Shah<sup>3</sup> , Prasanna Karki<sup>4</sup> , Gopal Raman Sharma<sup>5</sup> 

<sup>1,2,3,4,5</sup>Department of Neurosciences, Nepal Medicit Hospital, Sainbu, Lalitpur, Nepal

Date of submission: 5<sup>th</sup> November 2021

Date of acceptance: 10<sup>th</sup> February 2022

Date of publication: 15<sup>th</sup> March 2022

## Abstract

**Objective:** Ex-vivo preservation of autologous bone flap for Cranioplasty involves various techniques but there are no fixed guidelines as preservation time, temperature, technique differs. It was preserved submerging in the mixture of 10% betadine and 90 % ethyl alcohol solution in an airtight container in refrigerator at constant temperature of 0 ° C and was autoclaved 1 hour before reimplantation. The Primary objective of the study is to analyze surgical site infection, secondary its association with dependent variables age, sex, mode of injury, number of procedure performed.

**Materials and methods:** This is a retrospective study conducted in Nepal Medicit hospital from September 2017 to November 2019. Data of all patients who underwent Cranioplasty was reviewed from medical record, U/L autologous bone Cranioplasty preserved with this technique were only included in the study. The primary outcome SSI was classified according to guidelines of the centers of disease control and established with organism isolated in the culture.

**Results:** Only 66 out of 78 Cranioplasty was included in this study. The majority was male 83.3%. The mean age was 37.16 (standard deviation [SD]±14.58). The SSI was 7.5% and was associated with number of procedures performed (p=0.02). RTA was major cause of Cranioplasty in 60.61%.

**Conclusion:** Ex-vivo preservation of autologous bone flap for Cranioplasty with this technique is safe to be applied in resource limited settings as it can produce similar results as other techniques.

**Key words:** Cranioplasty, Surgical site infection, autologous bone flap, Preservation

## Introduction

Decompressive Craniectomy (DC) is a potentially life-saving neurosurgical procedure that can be

performed in minimal neurosurgical facility settings and remains the treatment of choice for medically refractory intracranial hypertension, most commonly in the severe traumatic brain injury, large vessel infarction and less frequently in cases of intra-operative brain swelling, aneurysmal subarachnoid hemorrhage and encephalitis.<sup>1</sup> The autologous bone flap (ABF) following DC can be preserved in vivo in subcutaneous pocket or Ex-vivo by maintaining complete asepsis by cryopreservation at very low temperature. Cranioplasty commonly is required to protect the brain, restore aesthetics and relieve neurologic symptoms, as well as for psychosocial reason.<sup>2</sup> Autologous bone is widely used for Cranioplasty as it is relatively inexpensive, easy to obtain, exhibits good fit and contour, presents no risk of disease transmission and is viable.<sup>3</sup> To date, studies comparing the outcomes of Cranioplasty with cryopreserved and subcutaneously stored bone flaps have produced variable results; a significant deficiency in those studies is the lack of standardization among the described techniques.<sup>4</sup> Surgical site infection (SSI) is the major Complication causing graft removal and may be associated with preservation technique also. Cheng-Hsin Cheng et al, study over 10 years showed the SSIs rate 18.2% in the subcutaneous pocket (SP) group and 11.1% in the Cryopreservation (CP) group.<sup>5</sup> Other study Inamasu

### Access this article online

Website: <https://www.nepjol.info/index.php/NJN>

DOI: <https://doi.org/10.3126/njn.v19i1.40675>

### HOW TO CITE

Joshi S, Paudel P, Shah DB, Karki P, Sharma GR. Ex-vivo Preservation Technique of Autologous Bone Flap in Resource Limited Settings: Retrospective Analysis of Outcome Based on Single Institute of Nepal. NJNS. 2022;19(1):45-51.



### Address for correspondence:

Dr. Sumit Joshi,  
Nepal Medicit Hospital  
Email: drjoshisumit@gmail.com

Copyright © 2022 Nepalese Society of Neurosurgeons (NESON)

ISSN: 1813-1948 (Print), 1813-1956 (Online)



This work is licensed under a Creative Commons Attribution-Non Commercial 4.0 International License.

et al, over 9 years period showed 5.1% in the SP group and 16.1% in the CP group.<sup>6</sup> Overall complication may range from 10.5% to 50%.<sup>7</sup> One similar study from Nepal has shown overall complication rate of 9%.<sup>8</sup> After removal in DC, the cranial bone flap is most often preserved sterilely in a freezer.<sup>9</sup> Preservation times and temperatures vary greatly and no standard regarding either has been established.<sup>10</sup> Some advocate submerging the bone flap in antiseptics prior to preservation.<sup>11</sup> In our study after DC, the autologous bone flap is preserved submerging in the mixture of 10% betadine and 90% ethyl alcohol solution in an airtight container in refrigerator at constant temperature of 0 ° C and autoclaved 1 hour before reimplantation. The primary outcome SSI, secondary outcome its association with dependent variables age, sex, mode of injury, number of procedure will be analyzed.

## Materials and methods

### Study design and patient population

A retrospective study was designed after approval from the hospital to collect data, ethical approval was taken from the Institutional review committee of Nepal health research council (394/2020P). All patients who underwent U/L cranioplasty at Nepal Medcity hospital, Kathmandu from September 2017 to November 2019 with ABF with this technique were included in this study. Cranioplasty performed with other technique were excluded from the study.

- **The primary outcome**

SSI will be classified according to the guideline of the centers of disease control (CDC) and also will be established by the culture.

### Definition of surgical site infection<sup>12-13</sup>

#### A. Superficial incisional infection

This is defined as a surgical site infection that occurs within 30 days of surgery, involves only the skin or subcutaneous tissue of the incision and meets at least one of the following criteria:

1. The superficial incision causes purulent drainage.
2. The superficial incision yields organisms from the culture of aseptically aspirated fluid or tissue or from a swab, and pus cells are present.
3. At least two of the following symptoms and signs are present: pain or tenderness, localized swelling, redness or heat.

The superficial incision is deliberately opened by a surgeon to manage the infection unless the incision is culture-negative, or the clinician diagnoses a superficial incisional infection. Stitch abscesses are defined as

minimal inflammation and discharge confined to the points of suture penetration and localized infection around a stab wound. They are not classified as surgical site infections.

#### B. Deep incisional infection

This is defined as a surgical site infection involving the deep tissues (i.e., fascial and muscle layers) that occurs within 30 days of surgery if no implant is in place or within a year if an implant is in place. The infection appears to be related to the surgical procedure and meets at least one of the following criteria:

1. There is purulent drainage from the deep incision but not from the organ/space component of the surgical site.
2. The deep incision yields organisms from the culture of aseptically aspirated fluid or tissue or from a swab, and pus cells are present.
3. The deep incision spontaneously dehisces or is deliberately opened by a surgeon when the patient has at least one of the following symptoms or signs (unless the incision is culture-negative): fever (>38 degree Celsius); localized pain or tenderness
4. An abscess or other evidence of infection involving the deep incision is found by direct examination during re-operation or by histopathological or radiological examination.
5. An attending clinician diagnoses a deep incisional surgical site infection.

Note: An infection involving both superficial and deep incision is classified as “deep incisional SSI” unless different organisms are present at each site.

#### C. Organ/Space SSI

This must meet the following criteria

1. Infection occurs within 30 to 90 days after the operative procedure (where day 1 = the procedure date) and involves any part of the body excluding the skin incision, fascia, or muscle layers, that is opened or manipulated during the operative procedure.

- **The secondary outcome**

The association of SSI (Dependent Variable) with independent variables age, sex, mode of injury, number of procedure.

#### Preservation of autologous bone flap after DC

The free Fronto-Tempo-Parietal bone flap after DC with size (L=12-13cm, B=8-9 cm) is cleared off of soft tissues, thoroughly irrigated with Normal saline, betadine solution and dried up using gauge piece. It was

## Ex-vivo Preservation Technique of Autologous Bone Flap in Resource Limited Settings

submerged completely in the povidone-iodine solution IP 10% and ethyl alcohol B.P 90 % in equal amount in an airtight sterile container. It was stored in refrigerator in our hospital's operation theatre at constant temperature of 0° C. The commonly used refrigerator temperature can be set from 33°F to 45°F (0°C to 7°C), has adequate space and shelves for storage of container. The autologous bone flap was autoclaved 1 hours before surgery and re-implanted during Cranioplasty. The preservation technique is represented in Fig 1(1A, 1B, 1C).

### Surgical Technique

There were total 66 patients who underwent autologous Cranioplasty in 3 to 6 weeks (mean 3.5 weeks) following DC. Repeat CT-scan brain with bony window was performed in all cases planned for Cranioplasty. The prophylactic antibiotics used was flucloxacillin and ceftriaxone which was continued for 7-10 days. The skin incision was through previous skin incision, dura was meticulously dissected from the skin flap. Temporalis muscle was dissected from the dura and elevated. Bony margins were secured, hemostasis was achieved. Autoclaved autologous bone flap was reimplanted, dural tenting was done and bone was fixed with titanium screw and plates. Thereafter, temporalis muscle was replaced, hemostasis maintained, wound was closed in the anatomical layers after establishing vacuum drain, stitches were removed in the 10th post-operative day.

### Study measures /statistics

In the study SSI will be the primary outcome dependent variables classified according to the guideline of the centers of disease control (CDC) and also will be established by the culture. The association of dependent variable with independent variables age, sex, mode of injury and number of surgical procedures performed will be analyzed using chi-squared test with statistical significance at  $p < 0.05$ . The analysis will be performed by IBM SPSS Statistics version 23.

### Results

66 out of 78 patient was included in the study with 83.3% male. The mean age was 37.16 (Standard deviation [SD]  $\pm 14.58$ ). RTA was the major cause in 60.61% where cranioplasty was performed (pie chart.1). SSI was present in 5 (7.5%), Superficial incisional infection in 3 (4.5%) with superficial flap necrosis and wound gaping where MRSA, S. aureus was isolated in culture Organ/Space SSI in 2 (3%) with bone flap infection where Propionibacterium and Enterobacter was isolated in culture. (Table.1 Surgical Site Infection (SSI) classified according to the guideline of the centers of disease control (CDC) with causative organisms). SSI was associated significantly with the number of surgery performed following cranioplasty ( $p=0.02$ ). Table 2. Association of SSI (dependent variable) with independent variables. Some complication are presented in Fig. 2

		Numbers	Percentage	Findings	Isolated organism
1	Superficial incisional infection	3	4.5%	Superficial flap necrosis Wound gap	MRSA S. aureus
2	Deep incisional infection	-		-	
3	Organ/Space SSI	2	3%	Bone flap infection	Gram positive (Propionibacterium) Gram negative (Enterobacter)
	SSI	5	7.5%	-	
	No SSI	63	92.5%	Normal	-
	<b>Total</b>	<b>66</b>	<b>100%</b>	-	

*Table 1: Surgical Site Infection (SSI) classified according to the guideline of the centers of disease control (CDC) with causative organisms*

Independent variables		Dependent Variables (SSI)		Total	P value (Fischer's exact test)
		No	Yes		
Age	<40	32	2	34	1.00
	>40	31	1	32	
<b>Total</b>		<b>63</b>	<b>3</b>	<b>66</b>	
Sex	Male	52	3	55	1.00
	Female	11	0	11	
<b>Total</b>		<b>63</b>	<b>3</b>	<b>66</b>	
Mode of injury	RTA	38	2	40	1.00
	Non-RTA	25	1	26	
<b>Total</b>		<b>63</b>	<b>3</b>	<b>66</b>	
Number of procedure	1	61	1	62	0.02
	>1	2	2	4	
<b>Total</b>		<b>63</b>	<b>3</b>	<b>66</b>	

Table 2: Association of SSI (dependent variable) with independent variables



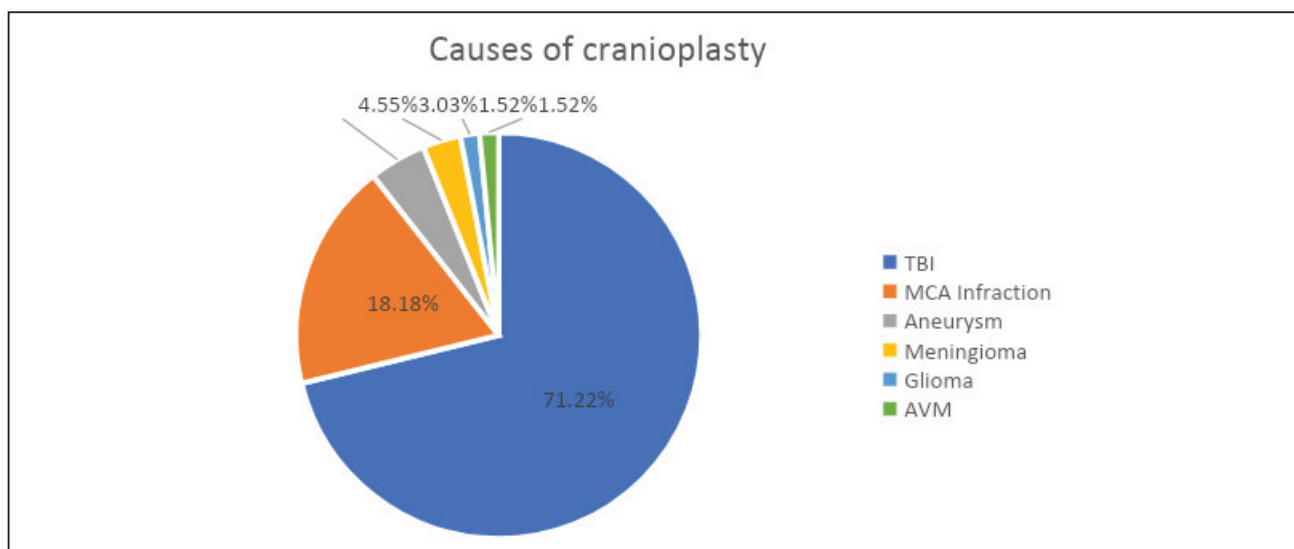
Figure 1: Preservation technique

Figure 1A: (bone flap measuring L=12-13cm, B=8-9 cm), Figure 1B: (povidone-iodine solution IP 10% and ethyl alcohol B.P 90 % in a sterile container with bone flap submerged), Figure 1C: (preservation in refrigerator with patient's particulars).

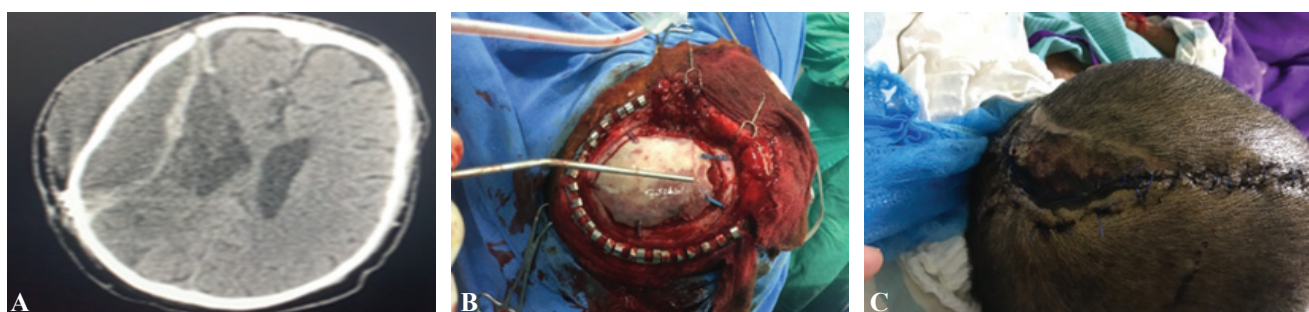

Figure 2: Complications

Figure 2A: Extradural collection post Cranioplasty, Figure 2B: Bone flap infection, Figure 2C: Superficial flap necrosis



Pie chart 1: Showing common causes of Cranioplasty

## Discussion

The decompressive Craniectomy (DC) is lifesaving neurosurgical procedure that can be performed even in settings of minimal neurosurgical facility and needs future cranioplasty which has higher rate of complications. Majority of the patients undergoing DC results from traumatic brain injury which affects all ages; however majority of road traffic injuries (RTI) occurs in young adult of productive age group. As per report by the ministry of road transport, Government of India (2007) 1.4 lakhs road accidents happened in 2007 with 40,612n people killed and 1.5 lakhs people injured.<sup>14</sup> The majority (60%) cases are due to road traffic injuries (RTI), followed by falls (20-25%) and violence (10%).<sup>15</sup> The majority of the patient 60.61% out of 71.22% with TBI in our series underwent CP due to RTA, followed by MCA infraction (18.18%), fall injury (9.09%), aneurysm surgery (4.55%), meningioma surgery (3.03%), AVM surgery (1.52%), glioma surgery (1.52%) and physical assault (1.52%).

Optimal bone flap size during DC taking into consideration of the head size is mandatory to effectively control ICP and prevent postoperative complications of DC.<sup>16</sup> In our series the autologous bone flap size L=12-13cm, B=8-9 cm approximately was taken during DC in most of the case. The autologous bone flap (ABF) is the gold standard for CP, therefore preservation technique for future cranioplasty is important due to its known complications. The ABF can be preserved following DC in vivo by creating subcutaneous pockets (SP) mostly in abdomen and ex-vivo which incorporates various techniques. In vivo preservation in SP fat pocket may increase the risk of complication as needs additional incision, produces scar, risk of surgical site infection (SSI)

and sometimes difficult in case of children as they have less subcutaneous fat. Ex-vivo preservation techniques mostly adopted are cryopreservation where autologous bone flap are preserved at very low temperature ranging from  $-4$  to  $-85^{\circ}\text{C}$ , which may be not be feasible in resource limited settings.

The major complication following CP is the risk for development of SSI and it can be sometimes associated with the preservation techniques of the autologous bone flap. Soft tissues were cleared from the bone flap, irrigated with normal saline, dried with gauze and was preserved in commonly used antiseptics povidone-iodine solution IP 10% and ethyl alcohol B.P 90 % in a sterile air tight container in equal amount. The various antiseptics are used in different centers and these are most commonly used antiseptic with proven efficacy and easily available in any settings.

It is very important to keep the autologous bone flap in aseptic condition during storage in refrigerator and also to maintain its viability. At too low temperature there is risk of osteocytes loss and protein degeneration but less risk of infection but with higher temperature osteocytes are viable and chances of infection increases. Maintaining lower temperature by newer techniques such as cryopreservation may not be available in resource limited settings but refrigerator are easily available with minimal surgical settings. Therefore we used  $0^{\circ}\text{C}$  and minimized the risk of infection by using antiseptics for preservation.

All patient in our study underwent early cranioplasty within 3-6 weeks (<3 months). Although, several studies have reported that early CP produced a significantly higher complication rate compared with late CP, other studies have shown that early CP produced more favorable results than late CP.<sup>17</sup> The studies comparing the outcomes

of Cranioplasty with cryopreserved and subcutaneously stored bone flaps have produced variable results and significant deficiency in those studies is the lack of standardization among the described techniques.<sup>18</sup> One meta-analysis comprising of total of 48 studies including 5346 patients where 4096 underwent cranioplasty with an autologous bone flap showed no statistically significant differences in Cryopreserved vs subcutaneous storage of bone flaps with respect to percentage of patients developing infection (7.3% vs. 7.1%).<sup>19</sup> The Centers for Disease Control and Prevention (CDC) has defined SSI, which was used in our series to assess the SSI and established by culture. There was 3 superficial incisional infection (4.5%), 2 (3%) organ/space SSI involving ABF in our series. MRSA, S.aureus from superficial incisional infection and Propionibacterium/ enterobacter form organ/space SSI were isolated in the culture. There were total 5 (7.5%) SSI in our series which was comparable with the other studies.

CSF leak, pseudomeningocele, flap necrosis, poor cosmesis, infections, seizures, intracranial hematoma, rarely mortality are the complications often encountered following the cranioplasty. Excessive stretching of the edges of the wound due to low skin elasticity or scar deformity due to previous incision, compression of the edges of the wound with the application of a large number of sub cutaneous sutures, the initial direction of the incision, excessive tension on the tissue can disturb microcirculation resulting skin flap necrosis and wound gaping. Multiple neurosurgical revisions may be related to disrupted wound healing, cause repeated exposure to bacterial translocation during the surgical procedures and also associated with a higher risk of subgaleal collection, which leads to a higher risk of infection.<sup>20</sup> Superficial incisional infection with wound gaping and superficial flap necrosis were present in 3 (4.5%) of the patient where swab culture isolated MRSA, S.aureus to establish SSI. Organ/space SSI with gram positive organism. The one patient with superficial skin necrosis was managed with daily dressing and oral antibiotics. The remaining two patients with wound gaping had clear serosanguineous discharge, where resuturing was done and sensitive antibiotics was continued. The Propionibacterium and gram negative enterobacter with bone flap infection was established in 2 (3%) of the patient in our series. Amongst 4 patients who underwent more than one surgery following Cranioplasty 3 had extra dural hematoma and in 1 where bone flap could not be replaced due to intraoperative brain swelling, 2(3%) developed bone flap infection. There was significant association of SSI with number of cranial procedure performed in our series (pvalue.0.02). Pseudomeningocele, CSF leak, poor cosmesis, wound gaping were other complication in patient in our series. Though majority of the cranioplasty was performed in

young, adult, male in our series, no significant association was found with age (p=1.00), sex (p=1.00) and mode of injury (1.00).

## Conclusion

Cranioplasty is a common neurosurgical procedure that can be performed in a setting of minimal neurosurgical facility. This preservation technique of ABF is safe to be applied in resource limited settings. SSI is significantly associated with the number of surgery following cranioplasty. However, a prospective multicentre randomized controlled study is necessary to confirm our findings.

**Source of financial support:** None

**Conflict of interest:** None

## References

1. Gooch MR, Gin GE, Kenning TJ, et al. Complications of cranioplasty following decompressive Craniectomy: analysis of 62 cases. *Neurosurg Focus*. 2009; 26(6). <https://doi.org/10.3171/2009.3.FOCUS0962>.
2. Caro-Osorio E, De La Garza-Ramos Martinez-Sanchez SR, Olazarán-Salinas F. Cranioplasty with polymethylmethacrylate prostheses fabricated by hand using original bone flaps: technical note and surgical outcome. *Surg Neurol Int*. 2013 Oct;4:136. <https://doi.org/10.4103/2152-7806.119535>.
3. Anger C, Dijon M, Park H. Delayed minimally invasive Cranioplasty. *Minim Invasive Neurosurg* 2003; 46(3):186-190. <https://doi.org/10.1055%2Fs-2003-40738>.
4. Sultan SM, Davidson EH, Butala P, et al. Interval cranioplasty: comparison of current standards. *Plast Reconstr Surg*. 2011; 127(5):1855-1864. <https://doi.org/10.1097/PRS.0b013e31820e89a5>.
5. Cheng-Hsin C, Han-Chung L, Chun-Chung C, et al. Cryopreservation versus subcutaneous preservation of autologous bone flaps for Cranioplasty: Comparison of the surgical site infection and bone resorption rates. *Clinical Neurology and Neurosurgery*. 2014; 124:85-89. <https://doi.org/10.1016/j.clineuro.2014.06.029>.
6. Joji I, Takumi K, Mashahi N. Does Difference in the Storage Method of Bone Flaps After Decompressive Craniectomy Affect the Incidence of Surgical Site Infection After Cranioplasty? Comparison Between Subcutaneous Pocket and Cryopreservation. *The Journal of Trauma: Injury, Infection, and Critical Care*: January 2010; 68(1):183-187. <https://scite.ai/reports/10.1097/ta.0b013e3181c45384>.
7. Prasad G L, Menon GR, Kongwad LI, et al. Outcomes of Cranioplasty from a Tertiary Hospital in

- a Developing Country. *Neurol India*.2020;68:63-70. <https://doi.org/10.4103/0028-3886.279676>.
8. Shakya B, KC B, Thapa A. Surgical outcome of ex-vivo preserved Autologous Cranioplasty-A novel Approach. *Nepal Journal of Neurosciences* 2019; 16(3):43-49. DOI: <https://doi.org/10.3126/njn.v16i3.27355>.
  9. Bhaskar IP, Zaw NN, Zheng M, et al. Bone flap storage following Craniectomy: A survey of practices in major Australian neurosurgical centres. *ANZ Journal of Surgery*.2011; 81(3):137-141. <https://doi.org/10.1111/j.1445-2197.2010.05584.x>.
  10. Malcolm JG, Rindler RS, Chu JK, et al. Complications following cranioplasty and relationship to timing: A systematic review and meta-analysis. *J Clin Neurosci*. 2016;33:39-51.<https://doi.org/10.1016/j.jocn.2016.04.017>.
  11. Zhang J, Peng F, Liu Z, et al. Cranioplasty with autogenous bone flaps cryopreserved in povidone iodine: a long-term follow-up study. *J Neurosurg*.2017; 127:1449–1456.<https://doi.org/10.3171/2016.8.JNS16204>.
  12. Horan TC, Gaynes RP, Martone WJ, et al. CDC definitions of nosocomial surgical site infections 1992: a modification of CDC definitions of surgical wound infections. *Infect Control Hosp Epidemiol*. 1992; 13:606–608. <http://dx.doi.org/10.1017/S0195941700015241>.
  13. Horan TC, Gaynes RP, Martone WJ, et al. CDC definitions of nosocomial surgical site infections, 1992: a modification of CDC definitions of surgical wound infections. *Am J Infect Control*. 1992; 20(5):271–274. [http://dx.doi.org/10.1016/S0196-6553\(05\)80201-9](http://dx.doi.org/10.1016/S0196-6553(05)80201-9).
  14. Samabasivan M. Epidemiology of Neurotrauma. *Neurology and Prevention. J Emerg Trauma Shock*. 2015; 8(3): 131–139.<https://doi.org/10.4103/0974-2700.160700>.
  15. Gururaj G. Epidemiology of traumatic brain injuries: Indian scenario. *Neurol Res*. 2002; 24(1):24-8. <https://doi.org/10.1179/016164102101199503>.
  16. Solon M, Philippe Judith. Optimal bone flap size for decompressive craniectomy for refractory increased intracranial pressure in traumatic brain injury taking the patient's head size into account. *World Neurosurg*.2020; 137:430-436.<https://doi.org/10.1016/j.wneu.2020.01.232>.
  17. Sultan SM, Davidson EH, Butala P, et al. Interval cranioplasty: comparison of current standards. *Plastic and Reconstructive Surgery*. 2011; 127(5):1855-1864. <https://doi.org/10.1097/PRS.0b013e31820e89a5>.
  18. Chibbaro S, Di Rocco F, Mirone G, et al. Decompressive craniectomy and early cranioplasty for the management of severe head injury: a prospective multicenter study on 147 patients. *World Neurosurgery*.2011; 75(3-4):558-562.<https://doi.org/10.1016/j.wneu.2010.10.020>.
  19. Brian C, Timothy G, Sasha V, et al. Complications After In Vivo and Ex Vivo Autologous Bone Flap Storage for Cranioplasty: A Comparative Analysis of the Literature. *World Neurosurgery*.2016; 96:510-515. <https://doi.org/10.1016/j.wneu.2016.09.025>.
  20. Mohamad SA, Mohd Haspani MS, Idris B. There are no differences between factors determining graft infection in autologous bone flap replacement and acrylic cranioplasty: a prospective observational study at Hospital Kuala Lumpur. *Malays J Med Sci*. 2016; 23(5): 83–90. <http://dx.doi.org/10.21315/mjms2016.23.5.11>.