


Successful retrieval of a retained J guidewire from the right atrium and aortic arch using a self-invented snare device



Chuan Chen *PhD*¹, Robin Bhattarai *PhD*², Yang Yang *MD*³, Cong Ling *PhD*⁴, Lun Luo *MD*⁵, Hui Wang *PhD*⁶

^{1,4,5,6}Department of Neurosurgery, Third Affiliated Hospital of Sun Yat-sen University, Guangdong, PR China

²Department of Neurosurgery, B and C Medical College Teaching Hospital and Research Center, Birtamode, Jhapa, Nepal

³Department of Radiology, Third Affiliated Hospital of Sun Yat-sen University, Guangdong, PR China

Date of submission: 12th March 2021

Date of acceptance: 29th April 2021

Date of publication: 1st June 2021

Abstract

Guidewire retention during an interventional treatment is a very rare complication that can lead to possible serious complications, such as thrombosis, embolization, sepsis, and perforation. Hence, a retained guidewire must be retrieved as soon as possible. Here, we provide the first report of a case of accidental retention of a 0.035" J guidewire in the right atrium and aortic arch during basilar artery aneurysm embolization. We found that due to the heavier weight of the J guidewire and its hydrophilic-coated layer, it could not be removed using previously reported methods for micro-guidewire retention. Therefore, we constructed a self-invented snare device consisting of a 0.014" micro-guidewire and a 4-Fr MP-A1 catheter and successfully retrieved the J guidewire, thus avoiding open surgery and its associated serious complications. According to our experience, this novel technique described here is quite easy to perform, safe, effective, can avoid serious complications and prevent the need for open surgery.

Key words: Aneurysm embolization, Retained J guidewire, Retrieval, Thromboembolic event.

Introduction

Given the widespread use of interventional techniques, guidewire retention is a rarely reported complication.¹ Because serious complications, such as thrombosis, embolization, sepsis, vessel dissection, and perforation, can occur after guidewire retention, the guidewire needs to be retrieved as soon as possible via an interventional

technique or open surgery.²⁻⁴ In the few existing recent reports, the retained guidewires were mostly 0.014" or 0.021" micro-guidewires, and the methods of management included the use of a gooseneck micro-snare, stenting against the vessel wall, deep-guided catheter wedging with balloon inflation and cardiovascular surgery.^{3,5,6} Here, we provide the first report of a case of accidental retention of a 0.035" J guidewire in the right atrium and aortic arch during basilar artery aneurysm embolization. After considering the difference in hydrophilic properties between the J guidewire and micro-guidewires and the retention characteristics in this case, we successfully retrieved the wire using a self-invented snare device, thus avoiding serious complications. To the best of our knowledge, no similar report has previously been published.

Access this article online

Website: <https://www.nepjol.info/index.php/NJN>

DOI: <https://doi.org/10.3126/njn.v18i2.35728>

HOW TO CITE

Chen C, Bhattarai R, Yang Y, Ling C, Luo L, Wang H. Successful retrieval of a retained J guidewire from the right atrium and aortic arch using a self-invented snare device. *NJNS*. 2021;18(2):67-70.



Address for correspondence:

Prof. Hui Wang

Department of Neurosurgery

Third Affiliated Hospital of Sun Yat-sen University

Guangzhou, Guangdong Province, PR China.

E-mail: 33691681@qq.com

Phone: +86 13922190409

Fax: +86 020 85252170

Copyright © 2021 Nepalese Society of Neurosurgeons (NESON)

ISSN: 1813-1948 (Print), 1813-1956 (Online)



This work is licensed under a Creative Commons Attribution-Non Commercial 4.0 International License.

Case report

A 75-year-old female patient was admitted to our hospital in September 2018 due to rupture of a basilar artery aneurysm. She was urgently treated with interventional embolization on the day of admission. During the operation, we found that the patient's right vertebral artery was occluded at its origin and that the left vertebral artery was severely distorted at its origin. Thus, we could not place a 6-Fr guiding catheter (Cordis Corp., Florida, USA) into the left vertebral artery (forced placement would likely have caused vertebral artery

spasm and posterior circulation ischaemia). We, therefore, advanced a J guidewire (Radifocus, Terumo, Tokyo, Japan) into the left brachial artery through a 6-Fr guiding catheter to stabilize the guiding catheter towards the left vertebral artery orifice so that aneurysm embolization could be performed smoothly. Unfortunately, the Y valve did not completely lock the J guidewire. Hence, at the end of the embolization, the J guidewire rushed into the right atrium and the aortic arch as a result of the pressure exerted by the high-pressure syringe (Figure 1A), the end of which was still in the guiding catheter (located at the T12 level) (Figure 1B).

After confirming that the activated clotting time was greater than 300 s, we first tried to use the traditional gooseneck micro-snare and balloon inflation method, but due to the heavier weight of the J guidewire and its hydrophilic-coated layer, these methods both ended in failure. Consequently, we constructed a self-invented snare device consisting of a 0.014" micro-guidewire (Microvention, Terumo, Tokyo, Japan) and a 4-Fr MP-A1 catheter (Cordis Corp., Florida, USA) as follows. We folded the micro-guidewire end until it formed a small loop (approximately 1.5 cm in length) and fixed it in

place with two 4-0 silk threads to ensure that the micro-guidewire formed a circle that was large enough to push the J guidewire through it (Figure 2A). The device was then placed close to the J guidewire in the 6-Fr guiding catheter, and the micro-guidewire loop was then used to capture the end of the J guidewire. Once the J guidewire was captured by the micro-guidewire loop (Figure 2B and supplementary video 1), the micro-guidewire was rotated to maximize the friction between the micro-guidewire loop and the J guidewire (Figure 2C). The J guidewire tail was then pulled back into the 4-Fr MP-A1 catheter (Figure 2D and supplementary video 2).

Finally, we slowly pulled out both the captured J guidewire and the self-invented snare device from the 6-Fr guiding catheter (Figure 3 and supplementary video 3).

Since there was no stent deployed during the surgery, there was no need for the patient to take any anticoagulant or antiplatelet medicine after the surgery. The patient was discharged on the 7th day after surgery without any complications and was free of clinical symptoms and thromboembolic events after a follow-up period of 6 months.

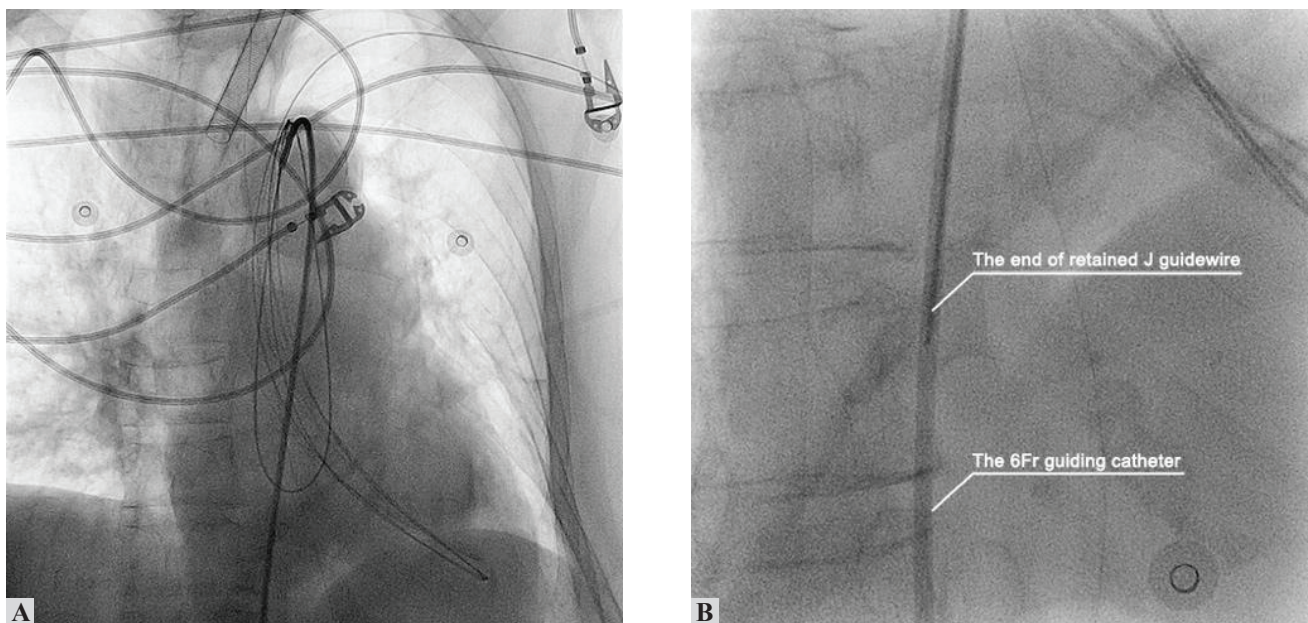


Figure 1: Radiological images showing a (A) 0.035" J guidewire that was retained in the right atrium and aortic arch; (B) The end of the J guidewire still located in the 6Fr guiding catheter (T12 vertebral level)

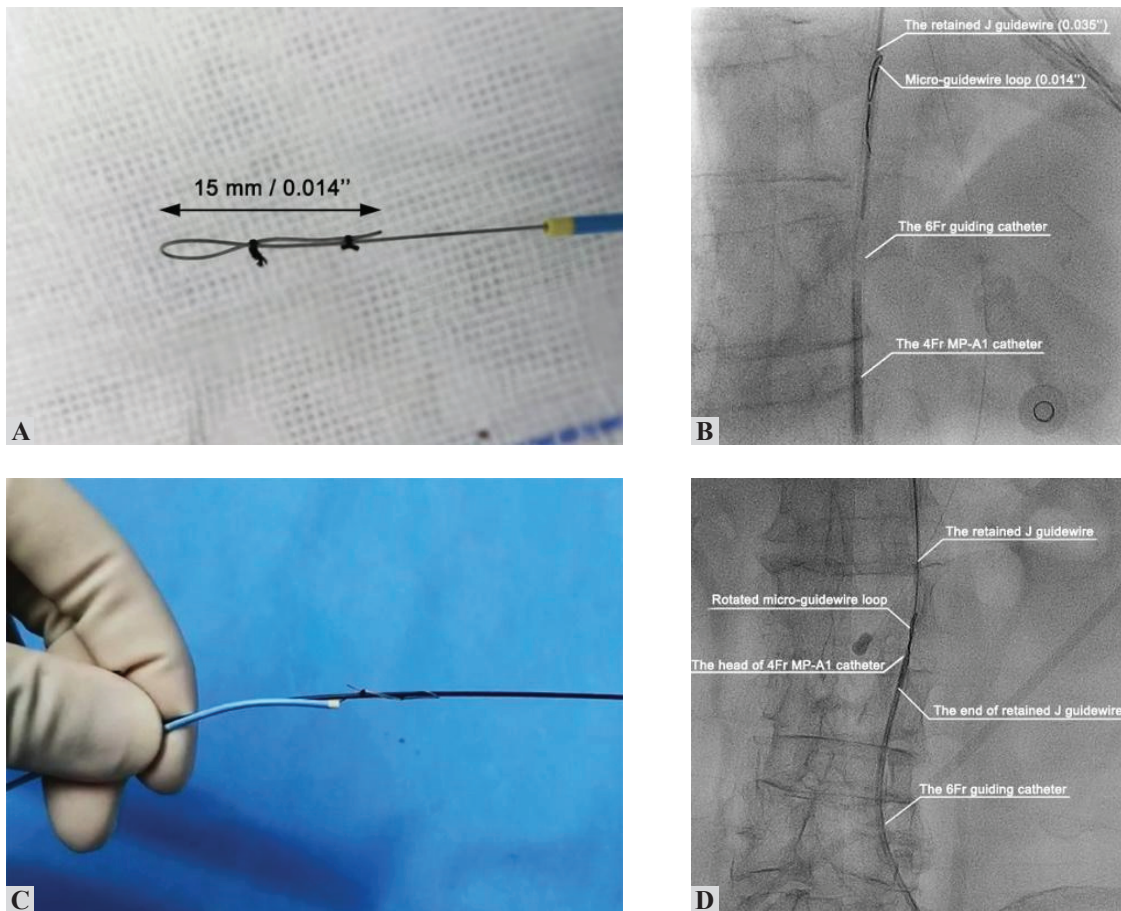


Figure 2: Radiological and intraoperative images showing the process of retrieving the J guidewire with a self-invented snare device. (A) The fabrication of the self-invented snare device. (B) A micro-guidewire was used to capture the end of the J guidewire. (C) The micro-guide wire was rotated to increase its friction with the J guidewire. (D) The J guidewire was then dragged into the 4Fr MP-A1 catheter

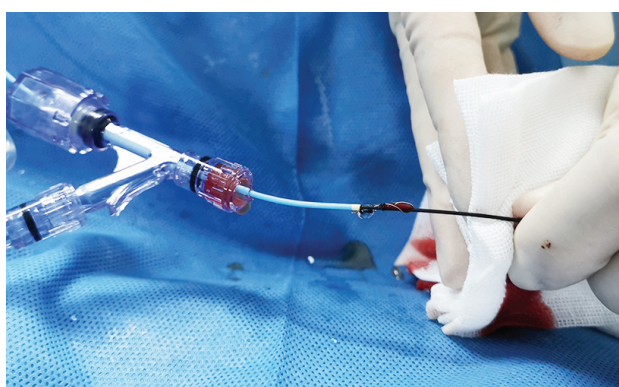

Figure 3: Intraoperative images demonstrating that the J guidewire was pulled out of the body.

Discussion

Guidewire retention is a very rare complication that can occur during cerebrovascular intervention or cardiovascular intervention. However, if a retained guidewire is not retrieved in a timely manner,

complications, such as thrombosis, embolization, sepsis, vessel dissection, and perforation, may occur in the early or late stage.⁷ Retrieval of the guidewire by open surgery can result in greater trauma and additional surgical risks. In contrast, although it is sometimes difficult to retrieve the guidewire via interventional methods, these approaches are less invasive and time-saving and are therefore often preferred.⁸ In the few relevant published case reports, the retained micro-guidewires were all 0.014” or 0.021”. According to the retention conditions, these guidewires can in most cases be successfully removed using a gooseneck micro-snare or deep-guide catheter wedged with balloon inflation.⁹ The technique of a gooseneck micro-snare is to snare the lost wire and retrieve it into the guiding catheter, and the method of using a deep-guide catheter wedged with balloon inflation is to trap the retained microwire between the outer wall of balloon and inner wall of guiding catheter. However, in this case, a 0.035” J guidewire was retained; these wires are heavier than micro-guidewires and therefore require greater pulling force; additionally, the presence of a hydrophilic surface layer also means that more friction is required to

pull it out. After attempting conventional interventional methods, we were able to remove the guidewire using a self-invented snare device. The advantage of our self-invented snare device is that it can be used to increase friction with the J guidewire by rotating the micro-guidewire (Supplementary video 4). This was the key to the successful removal of this J guidewire.

Conclusion

Retention of a 0.035" J guidewire is a very rare interventional complication that may be difficult to resolve via conventional interventional methods. The self-invented snare device described in this study consisted of a folded 0.014" micro-guidewire and a 4-Fr MP-A1 catheter and was successfully used to retrieve a retained J guidewire. This technique is easy to perform, is safe and effective, and can prevent the need for open surgery, which can result in additional complications.

Conflict of Interest: None

Source(s) of support: This work was supported by the National Natural Science Foundation of China (Grant No. 81901211), the Guangdong Basic and Applied Basic Research Foundation (Grant No. 2019A1515010384), the Third Affiliated Hospital of Sun Yat-Sen University Clinical Research Program (Grant No. QHJH201908), and the Medical Science and Technology Research Foundation of Guangdong Province (Grant No. A2019462).

Supplementary material captions

1. Video showing the process used to loop the micro-guidewire to capture the end of the J guidewire. <https://youtu.be/G1ihatXeIuI>
2. Video showing the process used to drag the J guidewire into the guiding catheter with a self-invented snare device. <https://youtu.be/E5P7P0CJ7YI>
3. Video showing the process used to pull the J guidewire out to the outside of the body. <https://youtu.be/c4Opfe4nJfE>
4. Video showing the process used to increase friction by rotating the micro-guidewire of the self-invented snare device. <https://youtu.be/YqV9B0bWLa8>

References

1. Patil S, Ramalingam R, Kharge J, et al. Successful Retrieval of Uncoiled Coronary Guidewire Using Simple Balloon Method. *J Clin Diagn Res.* 2015;9(10):OD01-3.<https://doi.org/10.7860/JCDR/2015/15323.6599>
2. Cho JY, Hong SJ. Successful Retrieval of Entrapped Gaia Guidewire in Calcified Chronic Total Occlusion Using Rotational Atherectomy Device. *Int Heart J* 2018;59(3):614-7.<https://doi.org/10.1536/ihj.17-188>
3. Ahmad T, Chithiraichelvan S, Patil TA, et al. Surgical retrieval of entrapped coronary angioplasty guidewire from the aorta. *Asian Cardiovasc Thorac Ann.* 2016;24(1):81-4.<https://doi.org/10.1177/0218492314546496>
4. Al-Amri HS, AM AL-M, Calafiore AM. Left main approach for retrieval of retained guidewire fragment. *J Card Surg.* 2012;27(3):307-8.<https://doi.org/10.1111/j.1540-8191.2011.01352.x>
5. Patel T, Shah S, Pandya R, et al. Broken guidewire fragment: a simplified retrieval technique. *Catheter Cardiovasc Interv.* 2000;51(4):483-6.[https://doi.org/10.1002/1522-726X\(200012\)51:4<483::AID-CCD24>3.0.CO;2-F](https://doi.org/10.1002/1522-726X(200012)51:4<483::AID-CCD24>3.0.CO;2-F)
6. Goyal V, Hernandez GA, Cohen MG. Successful transradial retrieval of an embolized guidewire during transradial vascular access. *Catheter Cardiovasc Interv.* 2014;83(7):1089-92.<https://doi.org/10.1002/ccd.25461>
7. Perez-Diez D, Salgado-Fernandez J, Vazquez-Gonzalez N, et al. Images in cardiovascular medicine. Percutaneous retrieval of a lost guidewire that caused cardiac tamponade. *Circulation.* 2007;115(24):e629-31.<https://doi.org/10.1161/CIRCULATIONAHA.107.689000>
8. Deora S, More D, Shah S, et al. Successful retrieval of broken coiled guidewire from left atrium during balloon mitral valvotomy: a rare complication. *Acute Card Care.* 2014;16(3):110-1.<https://doi.org/10.3109/17482941.2014.921311>
9. Baumann S, Rupp D, Becher T, et al. Retrieval of a fractured angioplasty guidewire after percutaneous retrograde revascularization of coronary chronic total occlusion. *Coron Artery Dis.* 2018;29(1):81-2.<https://doi.org/10.1097/MCA.0000000000000535>