

# Bamboo in the brain: Impalement injury over orbito-cranial region via superior orbital fissure



Bibesh Pokhrel <sup>MS<sup>1</sup></sup> , Amit Thapa <sup>MCh<sup>2</sup></sup> 

<sup>1,2</sup>Department of Neurological Surgery, Kathmandu Medical College Teaching Hospital, Sinamangal, Kathmandu, Nepal

Date of submission: 14<sup>th</sup> February 2021

Date of acceptance: 26<sup>th</sup> April 2021

Date of publication: 1<sup>st</sup> June 2021

## Abstract

Intracranial wooden foreign bodies due to transorbital penetrating injury sparing orbital globe are relatively rare with no reported cases till date. A multidisciplinary approach with multiple imaging modalities is needed for preoperative surgical planning.

In this case report, we report a case of a 3-year-old male who presented to the emergency department with a history of fall from 5 feet with no vision over right eye. A cut injury of around 2 cm with sutures in situ was present over the nasal ridge with pus discharge. CT scan head showed foreign body over temporal region. Right fronto-temporo-orbito-zygomatic craniotomy with removal of foreign body was done. Deep seated abscess seen over temporal fossa was evacuated and intravenous antibiotics were continued postoperatively. Contrast enhanced CT repeated on 15<sup>th</sup> postoperative day showed no remaining abscess or foreign body. The patient was discharged on oral antibiotics. The wound healed completely with no improvement of vision in 1-week follow-up.

**Key words:** Brain abscess, Orbito-cranial penetrating injury, Wooden foreign body.

## Introduction

Intracranial penetrating foreign body is relatively rare compared to other modes of head injury among children. Approximately 1.6 million individuals are blinded by ocular injuries.<sup>1</sup> Foreign bodies enter the cranial cavity either through low resistance corridors like nose, ear, orbits or through high resistance corridors like the skull in case of high velocity penetrating injury. These injuries can occur due to gunshot, accidents, assaults or suicidal attempt.<sup>2</sup> There has been reported cases of child abuse, where foreign body are inserted through the anterior fontanelle with intention of infanticide.<sup>3</sup>

Objects like wood, metals or glass can get lodged in different areas of the skull depending upon the impact velocity, nature of object (sharp/blunt), angle and area of impact and cause complications accordingly.<sup>4</sup> Foreign body through the orbital region are particularly difficult to access because of the peri-orbital swelling associated with it. In all cases of suspected foreign body, CT scan is the imaging modality of choice as X-ray might not detect wooden foreign bodies. Intracranial wooden foreign body is often difficult to interpret as radiological appearance of dry wood is similar to that of air, while that of wet wood is similar to that of soft tissue.<sup>5</sup> Adding difficulty to that is the presence of pneumocephalus in case of penetrating foreign body, mimicking a wooden foreign body.

As the orbit is a conical pyramidal cavity, foreign bodies to the orbit often get deflected towards the apex, which has optic canal, the superior and the inferior orbital fissures and supraorbital and infraorbital foramen; to reach the intracranial cavity. The foreign body can also penetrate the thin orbital roof and get lodged in the frontal lobe in case of vertically directed objects.<sup>6</sup>

We present a case of impaled bamboo stick over orbito-cranial region via superior orbital fissure without any vascular injury.

## Case Report

A 3-year-old male presented to our emergency department with a history of a fall from a 5 feet wall while playing 7 days prior to presentation. During the fall, he impacted his face on the floor and a bamboo shoot penetrated his nasal bridge, which he pulled out.

### Access this article online

Website: <https://www.nepjol.info/index.php/NJN>

DOI: <https://doi.org/10.3126/njn.v18i2.34965>

### HOW TO CITE

Pokhrel B, Thapa A. Bamboo in the brain: Impalement injury over orbito-cranial region via superior orbital fissure. *NJNS*. 2021;18(2):71-5.



### Address for correspondence:

Professor Amit Thapa

Head of Department, Department of Neurological Surgery

Kathmandu Medical College Teaching Hospital

Sinamangal, Kathmandu, Nepal.

E-mail: [dramitthapa@yahoo.com](mailto:dramitthapa@yahoo.com)

Phone: +977 9851177995

Copyright © 2021 Nepalese Society of Neurosurgeons (NESON)

ISSN: 1813-1948 (Print), 1813-1956 (Online)



This work is licensed under a Creative Commons Attribution-Non Commercial 4.0 International License.

He was then taken to a nearby clinic, where suturing was done and was discharged on oral antibiotics. He complained of diminished vision and pus discharge from the sutured site on the 5th day and he was referred to our center. On examination, the patient's vitals were stable, GCS was 15 and neurologic examination did not reveal any abnormalities. He had proptosis of the right eye with a fixed and dilated pupil and no vision (Figure 1). Ophthalmological evaluation revealed conjunctival congestion and chemosis; optic disc evaluation was normal and extraocular muscles were restricted. ~2cm cut injury with sutures in situ was present over the nasal ridge with pus discharge. Ophthalmoscope examination revealed intact orbit globe with injury of optic nerve.

On suspicion of impalement foreign body, CT head and orbit was done which revealed linear hypodense area with air density in the right orbit extending from the right orbital apex to the right medial temporal lobe via the superior orbital fissure (Figure 2). CT angiography showed proximity of the middle cerebral artery and cavernous sinus internal carotid artery to the foreign body and a probable abscess formation in the subperiosteal aspect of the superior right orbit and in the right medial temporal lobe. There were inflammatory changes noted in the right intra and extraconal space right eye leading to proptosis (Figure 3). However, there was no evidence of obvious vascular injury by foreign body. The sutures were removed and abscess were allowed to drain. Intravenous antibiotics was started.

A right fronto-temporo-orbito-zygomatic osteoplastic craniotomy was done by raising a modified bicoronal flap (Figure 4). The foreign body was visualized piercing the medial part of the orbit and going into the medial aspect of the right temporal lobe through superior orbital

fissure (Figure 5). Since the wood was stuck, it had to be broken down and removed in pieces so that there is no further injury while extraction (Figure 6). Deep seated abscess was seen over the temporal lobe and drained. The breach in the dura and superior orbital fissure was repaired. Ophthalmologist evaluated the case and re-suturing of the wound was done. Post-operative period of the patient was uneventful. Intravenous antibiotics were continued for 2 weeks. Proptosis, orbital cellulitis and edema resolved gradually. Contrast enhanced CT was repeated on 15<sup>th</sup> post-op day which showed no remaining abscess (Figure 7). His neurological status was normal throughout the hospital stay. The patient was discharged on oral antibiotics. The wound healed completely with no improvement of vision in 1-week follow-up (Figure 8).

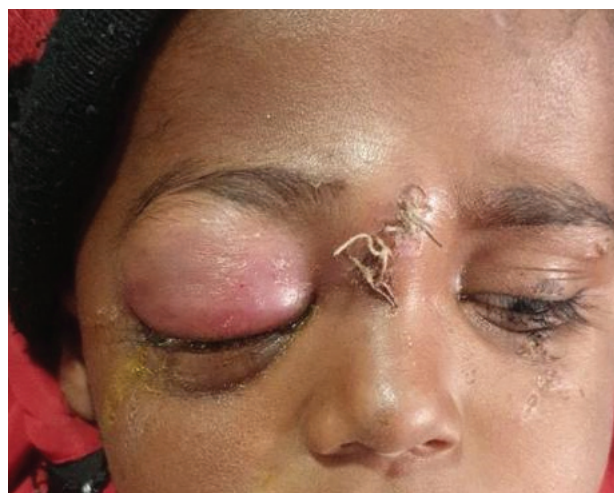

Figure 1: Patient on presentation to ER

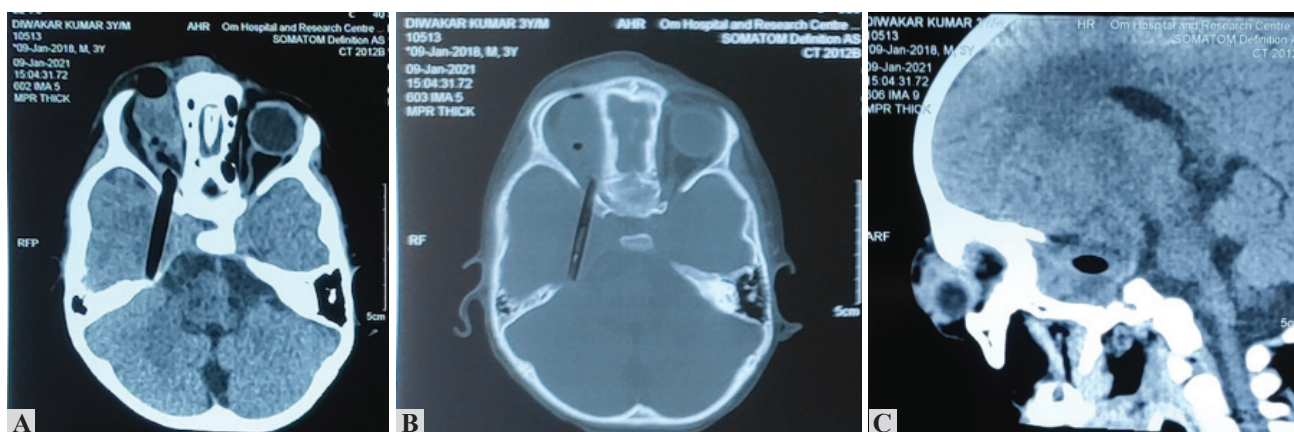

Figure 2: CT head and orbit showing hypodense area in (A) axial, (B) axial bone window and (C) sagittal view in the right orbit extending from the right orbital apex to the right medial temporal lobe via the superior orbital fissure



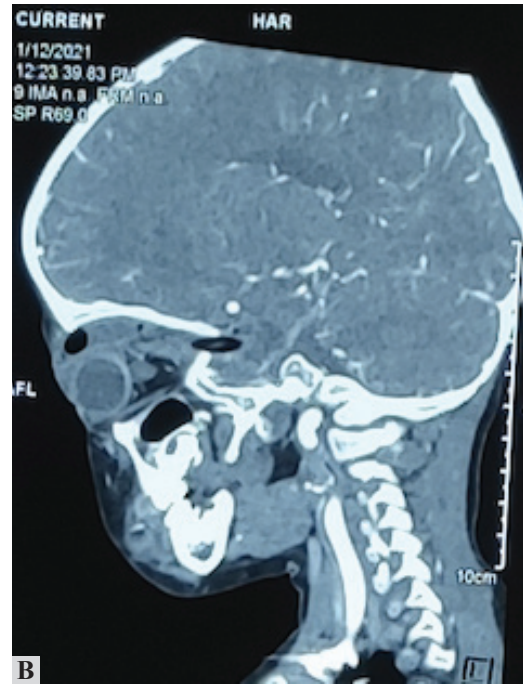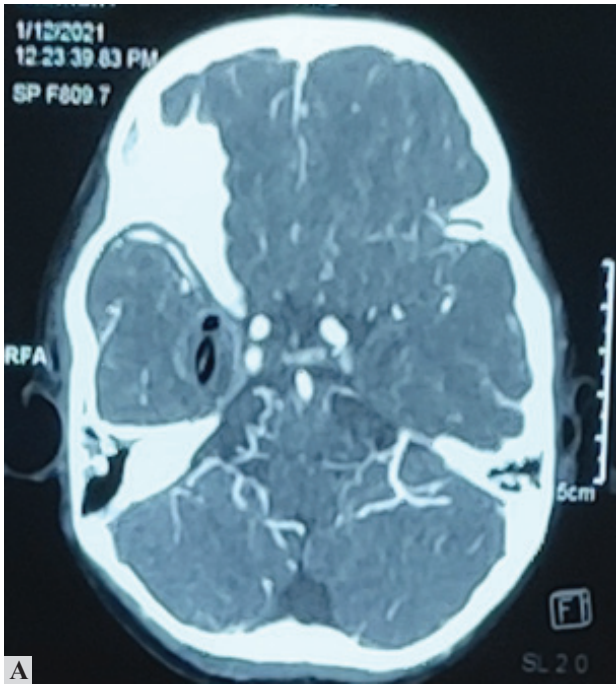


Figure 3: CT angiography showing foreign body in proximity of middle cerebral artery in (A) axial, (B) sagittal view

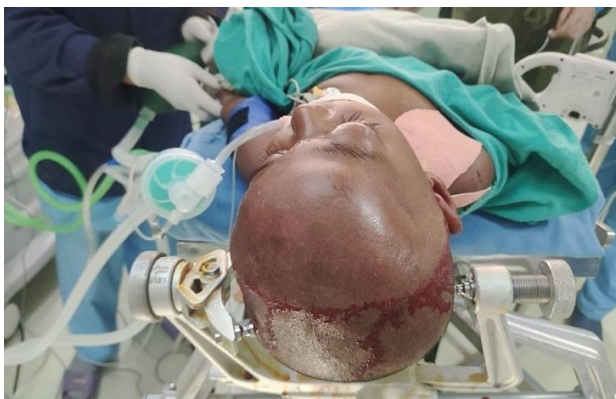

Figure 4: A modified bicoronal flap was planned and a right fronto-temporo-orbito-zygomatic osteoplastic craniotomy was done



Figure 6: Pieces of foreign body removed

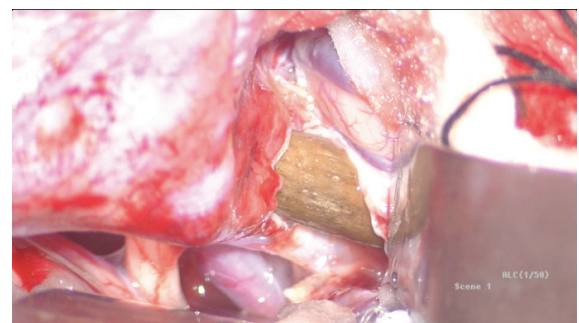
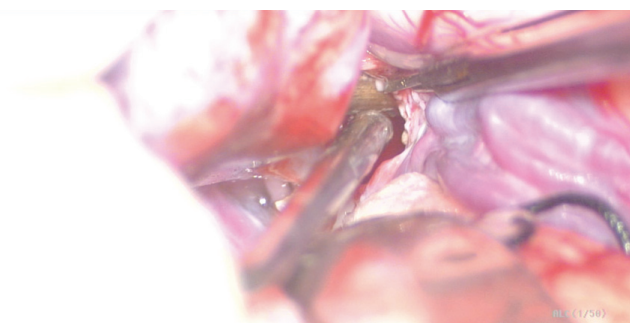


Figure 5: Intraoperative images showing foreign body piercing medial part of the orbit and going into the medial aspect of right temporal lobe through superior orbital fissure

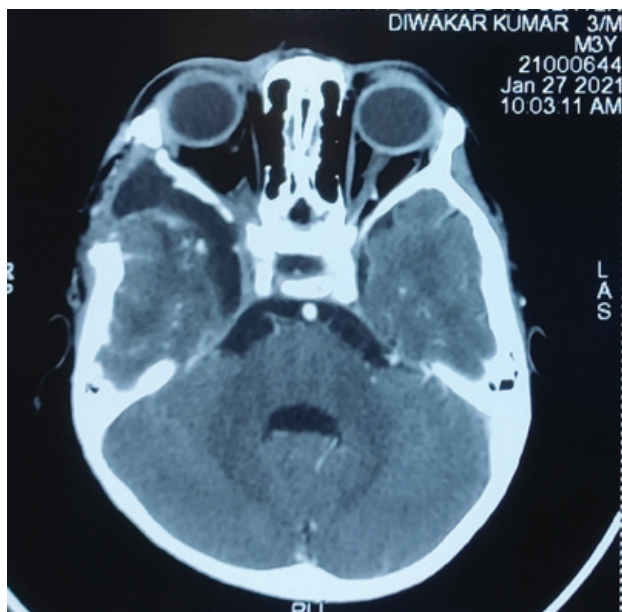

Figure 7: CECT brain and orbit done after 15 days post-op

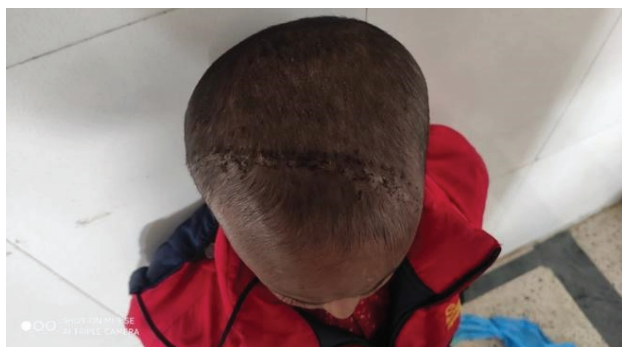

Figure 8: Wound on follow up; 3 weeks post-op

## Discussion

An impalement injury results from projectile trauma to low resistance corridors of the skull with a pointed tip object. Apart from the external damage of entry point with loss of integrity or bone fractures, more serious complications like life threatening vascular injury, damage to neural structures and adjacent intracranial structures can occur from a penetrating foreign body. Life threatening vascular injury can occur from injury to the internal carotid artery, basilar artery, cavernous sinus. Similarly, pituitary gland, cranial nerves I-VI, frontal lobe, temporal lobe, and the brain stem are also prone to injury.<sup>5,7</sup> A comb entering via the left orbit through the cavernous sinus with complete occlusion of cavernous segment of left ICA extending upto the pons has been described in literature.<sup>8</sup>

Apart from the primary trauma like bone fractures, vision loss, neuronal damage or sometimes death due to massive bleeding; impalement foreign bodies can produce life threatening secondary infection. Hence, a proper

treatment antibiotic regimen needs to be established. 48% brain abscess and 64% infection rate has been described even after proper antibiotic coverage.<sup>9</sup> Therefore, immediate evaluation with detailed history and physical examination and appropriate surgical management after detailed radio imaging is crucial for the management of penetrating intracranial foreign body.

Any case of suspected intracranial foreign body, CT is the primary diagnostic tool. CT cerebral angiography is required to identify or exclude the presence of injury to the intracranial vascular structures or proximity of vessels to foreign body. Magnetic resonance imaging can be helpful in cases where clear picture of the foreign body is not achieved, however it can only be done after conforming the absence of magnetic metallic foreign body.

Surgery for removal of an impaled foreign body can be achieved through transcranial, transorbital or a combination of both according to the location of foreign body. Endoscopic removal instead of craniotomy or endoscopic removal through nasal or paranasal sinus has also been used in some cases of residual foreign body.<sup>10</sup>

Sometimes, foreign body granulomas can occur due to clips used in surgery or because of cotton gauge left during surgeries.<sup>11</sup> Patient can present with seizures, thrombosis, obstructive hydrocephalus, fistulas(carotid- cavernous or arteriovenous), hematomas, focal neurological deficits or life threatening CNS infection like meningitis.<sup>2</sup> Most of them develop symptoms ranging from 1 week to 6 months after injury.<sup>12</sup> In our case, the patient developed abscess within 1 week, but there have been reports in literature where the symptoms have developed 13 years after injury as well.<sup>13</sup>

## Conclusion

Impalement injury in the brain with formation of abscess is a medical emergency which requires multidisciplinary expertise to achieve a good clinical outcome. Good clinical workup combined with appropriate radiographic evaluation along with a proper planning to surgically remove the foreign body is the management strategy with the aim of preserving neurovascular function and avoiding infection. Even in the absence of symptoms, removal of residual foreign body with full antibiotic coverage should be done to avoid foreign body granuloma and CNS infection in the future.

**Conflict of Interest:** None

**Source(s) of support:** None

## References

1. Parajuli A, Bastola J, Shrestha GB, Shrestha JB. A case of transorbital intracranial injury presenting

- with subtle neurological deficit. *Nep J Oph.* 2016;7(2):186-90.<https://doi.org/10.3126/nepjoph.v7i2.14977>
2. Gökçek C, Erdem Y, Köktekir E, et al. Intracranial foreign body. *Turk Neurosurg.* 2007;17(2):121-4.
  3. Gopaul R, Xiao WS, Yan J, Wei DZ. Intracranial foreign body through the sagittal sinus: case report and review of literature. *Chin Neurosurg J.* 2016;2(1):16.<https://doi.org/10.1186/s41016-016-0029-4>
  4. Baranwal VK, Gupta RP, Johri S, Dutta AK, Murthy PK, Avinash Mishra. A case of orbitocranial foreign body. *Medical Journal Armed Forces India.* 2016;72(1):82-4.<https://doi.org/10.1016/j.mjafi.2014.03.010>
  5. Dunn IF, Kim DH, Rubin PA, Blinder R, Gates J, Golby AJ. Orbitocranial wooden foreign body. *Neurosurgery.* 2009;65(2):E383-E384.<https://doi.org/10.1227/01.NEU.0000347474.69080.A1>
  6. Gaur N, Sharma P, Takkar B, Shashni A. Transorbital globe sparing penetrating cranial injury with a metallic screw: large cranio-orbital foreign body. *BMJ Case Reports.* 2017.<https://doi.org/10.1136/bcr-2017-221248>
  7. Yin HY, Dhanireddy S, Braley AE. Management of an unusual orbitocranial penetrating injury. *Case Reports in Ophthalmological Medicine.* 2020;2020:1-5.<https://doi.org/10.1155/2020/9070595>
  8. Xu F, Li J, Sun S, et al. The surgical management of a penetrating orbitocranial injury with a bakelite foreign body reaching the brain stem. *Brain Inj.* 2013;27(7-8):951-6.<https://doi.org/10.3109/0269905.2.2013.775502>
  9. Kaiser MC, Rodesch G, Capesius P. CT in a case of intracranial penetration of a pencil: A case report. *Neuroradiology.* 1983;24(4):229-31.<https://doi.org/10.1007/BF00399777>
  10. Yao Y, Shen F, Chen A, Ying G, Zhu Y. Percutaneous endoscopic removal of a residual foreign body at the orbital-cranial region after transorbital penetrating injury: a novel minimally invasive technique. *Chin Neurosurg J.* 2017;3(1):38.<https://doi.org/10.1186/s41016-017-0102-7>
  11. Karadas S, Dursun R, Kiymaz N. Treatment of intracranial foreign body. *J Pak Med Assoc.* 2014;64(7):828-9.
  12. Nishio Y, Hayashi N, Hamada H, Hirashima Y, Endo S. A case of delayed brain abscess due to a retained intracranial wooden foreign body: A case report and review of the last 20 years. *Acta Neurochir.* 2004;146(8).<https://doi.org/10.1007/s00701-004-0283-7>
  13. Horner FA, Berry RG, Frantz M. Broken pencil points as a cause of brain abscess. *N Engl J Med.* 1964;271:342-5.<https://doi.org/10.1056/NEJM196408132710703>