


# Primary central nervous system diffuse large B-cell lymphoma: a report on unusual presentation with acute onset diplopia and proptosis



Bibesh Pokhrel *MS*<sup>1</sup>, Amit Thapa *MCh*<sup>2</sup>

<sup>1,2</sup>Department of Neurosurgery, Kathmandu Medical College Teaching Hospital (KMCTH), Kathmandu, Nepal

Date of submission: 28<sup>th</sup> June 2020

Date of acceptance: 25<sup>th</sup> July 2020

Date of publication: 12<sup>th</sup> August 2020

## Abstract

Acute onset of diplopia with proptosis in case of primary CNS lymphoma has not been reported yet in literature. Blurred vision, reduced vision, and floaters are the commonest reported presentations. We report a case of a 41-year-old HIV positive male who presented with diplopia in the left eye for two weeks with proptosis of the left eyeball. CT Scan study of head and orbit showed heterogeneously enhancing large soft tissue calcified orbital mass pushing the left eyeball out of orbit. Right fronto-temporo-orbito-zygomatic (FTOZ) osteoplastic craniotomy with gross total excision of tumor was performed. Histopathological evaluation was suggestive of non-Hodgkin's lymphoma. Immunohistochemistry confirmed the diagnosis of diffuse large B-cell lymphoma, non-germinal center type. Five months follow-up showed good recovery with no evidence of recurrence.

**Key words:** Diffuse large B-cell lymphoma, HIV positive, Primary CNS lymphoma, Primary intraocular lymphoma-activated B cell

## Introduction

Primary Central Nervous System Lymphoma (PCNSL) accounts for less than 5% of primary brain tumor; a rare variant of extra-nodal non-Hodgkin's Lymphoma (NHL).<sup>1</sup> Histologically, diffuse large B-cell lymphoma (DLBCL) accounts for more than 96% of PCNSL confined

to the brain, leptomeninges, intraocular structures, cranial nerves, cerebrospinal fluid (CSF) and spinal cord without any systemic disease.<sup>2</sup> PCNSL risk is increased in any immunocompromised patients, with incidence of 2-10% in HIV positive patients.<sup>1</sup> Though the incidence of PCNSL in HIV patients has significantly decreased after the patient is started on combined antiretroviral therapy (cART), PCNSL is still common in patients not taking cART or in advanced HIV disease.<sup>3</sup>

Compared to other brain tumors, PCNSL has a very good response to chemotherapy and radiotherapy; but comparing with systemic lymphomas, the survival is less.<sup>4</sup> Patients present with neurologic signs that has developed over weeks, like focal neurologic deficits, mental and behavioral changes or seizures depending upon the location of lesion.

Primary intraocular lymphoma (PIOL) is a sub-type of PCNSL, which originates within the CNS and involves the retina, vitreous and the head of optic nerve.<sup>5</sup> Ophthalmic involvement is present in only 15-25% of the PCNSL cases,<sup>4</sup> while CNS manifestation is seen in 56-90% of PIOL cases.<sup>5</sup> Diplopia and protrusion of the eyeball are not common presentation of PCNSL and can be mistaken for other disease entity. A proper workup should be done for CNS manifestation of PCNSL.

### Access this article online

Website: <https://www.nepjol.info/index.php/NJN>

DOI: <https://doi.org/10.3126/njn.v17i2.30178>

### HOW TO CITE

Pokhrel B, Thapa A. Primary central nervous system diffuse large B-cell lymphoma: a report on unusual presentation with acute onset diplopia and proptosis. *NJNS*. 2020;17(1):65-68



<sup>1</sup>ORCID id: 0000-0002-1997-9859

<sup>2</sup>ORCID id: 0000-0003-1896-3115

### Address for correspondence:

Professor Amit Thapa

Head of Department, Department of Neurological Surgery

Kathmandu Medical College Teaching Hospital (KMCTH)

Sinamangal, Kathmandu, Nepal

Contact number: +977 9851177995

E-mail: dramitthapa@yahoo.com

Copyright © 2020 Nepalese Society of Neurosurgeons (NESON)

ISSN: 1813-1948 (Print), 1813-1956 (Online)



This work is licensed under a Creative Commons Attribution-Non Commercial 4.0 International License.

### Case report

A 41 years old male presented to the outpatient department with complaint of diplopia in left eye for two weeks and protrusion of left eyeball. His hypertension which was diagnosed two years back was under control with regular medications. On examination, he had impaired function of left lateral rectus muscle, with bilateral 3mm, reactive pupil, with GCS of 15. His vision acuity was 20/20 over right eye and could count fingers with left eye. On routine pre-operative evaluation, he was found to be seropositive for HIV. His plasma viral load was around 158k copies/ml, and Log<sub>10</sub> (copies/ml) was 5.19. Other laboratory parameters were within normal limits. CT scan of head and orbit showed bony destruction in the posterolateral wall of left orbit involving frontal and sphenoid bone with heterogeneously enhancing large soft tissue mass with calcification. The calcified lesion was bulging into the left orbit abutting the superior-posterior aspect of the globe, lacrimal gland and superior rectus muscle (Figure 1).

Contrast enhanced CT study of Chest, Abdomen, Pelvis and Neck was unremarkable. Testicular ultrasound

and CSF analysis did not show any evidence of systemic lymphoma. Right fronto-temporo-orbito-zygomatic (FTOZ) osteoplastic craniotomy with gross total excision of tumor was performed. As tumor was extending intracranially involving sphenoid bone and was densely adhering adjacent dura, excision of involved bone with lax duraplasty was performed along with temporary lateral tarsorrhaphy. Several greyish-brown tumor specimens were sent for histopathological evaluation which revealed features suggestive of Non-Hodgkin's Lymphoma with differential diagnosis of high-grade sarcoma or poorly differentiated carcinoma. Immunohistochemistry done with markers (CK, CD3, CD 10, CD20, MUM1, BCL6, TdT) supported the diagnosis of non-germinal center type of diffuse large B-cell lymphoma (Figure 2).

Patient was started on c-ART and chemotherapy. 3-month post-operative contrast MRI brain with orbit showed no evidence of residual tumor or recurrence. (Figure 3). Till date, the patient has received 4 cycles of chemotherapy. 5 months following surgery, the patient has no new complaint with complete resolution of diplopia and proptosis (Figure 4). The patient is instructed to follow up every 3 months in our outpatient department.

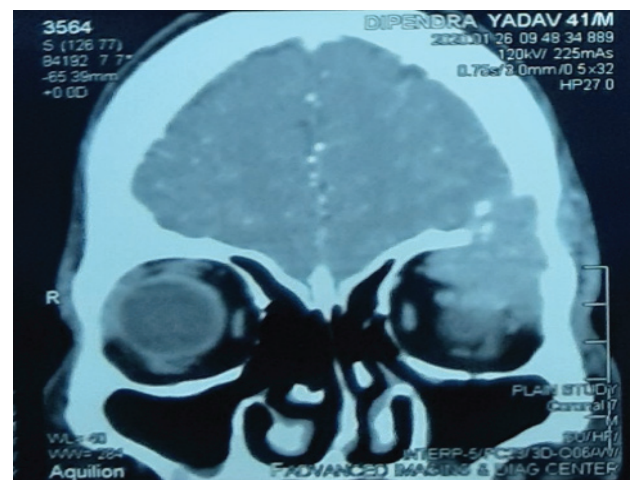
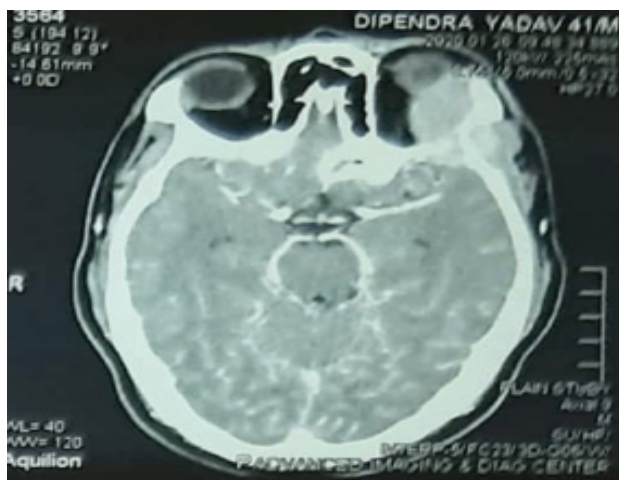


Figure 1: Pre-op CT scan of head and orbit (Axial and Coronal) showing heterogeneously enhancing large soft tissue calcification in left orbit with bony destruction.

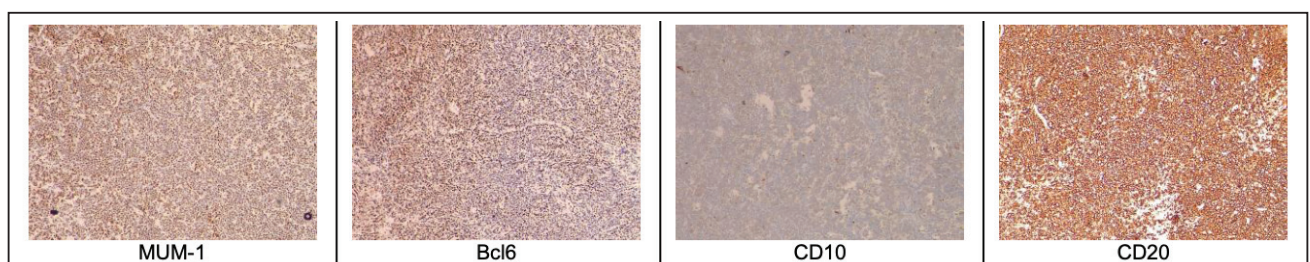
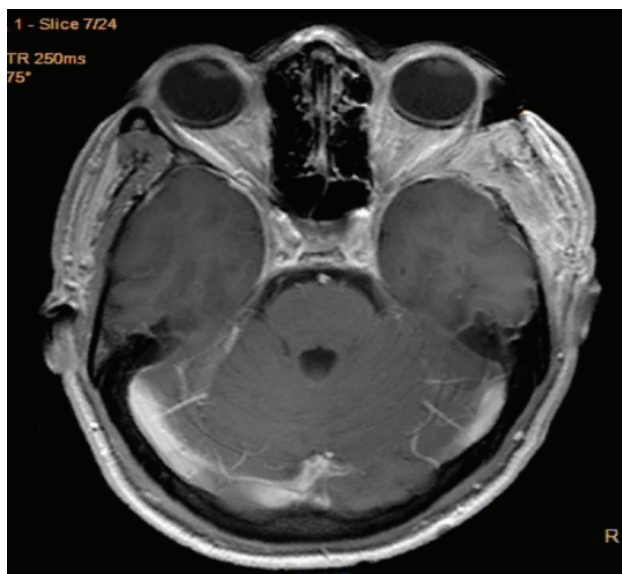
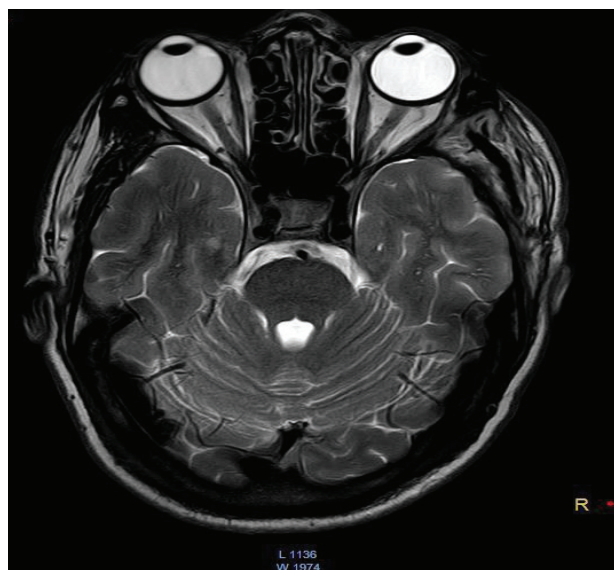
Figure 2: Immunohistochemistry panel. IHC marker MUM1: Immunoreactive, score 3+ in atypical lymphoid cells, BCL6: Immunoreactive, score 3+ in atypical lymphoid cells, CD10: Non-Immunoreactive in atypical lymphoid cells, CD20: Immunoreactive, score 4+ in atypical lymphoid cells





A



B

Figure 3: 3-month post-operative MRI orbit a) contrast T1WI b) T2WI

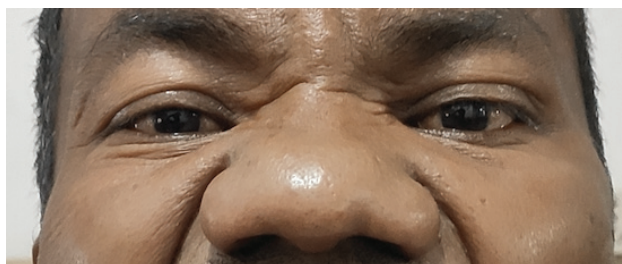


Figure 4: Five months post-operative photo of the patient. Normal left eye with no protrusion seen.

## Discussion

Primary diffuse large B-cell lymphoma (DLBCL) of the central nervous system (CNS) is an aggressive B-cell neoplasm accountable for <1% of all NHL. 96% of PCNSL belong to DLBCL, with other less frequent histologic subtypes include T-cell PCNSL, Burkitt lymphoma (BL), plasmablastic lymphoma, primary effusion lymphoma (PEL) and marginal zone lymphoma.<sup>6</sup> These differ in prognosis as well as in the phase of HIV infection. BL occurs in higher CD4 cell counts while PCNSL and PEL occur in severe immunocompromised individual.<sup>7</sup>

According to the latest edition of WHO classification, DLBCL histopathological subtype are identified by gene expression profiling. Cell of origin classification in DLBCL includes germinal center B-cell (GCB) subtype and activated B cell (ABC), implying PCNSL develops from a germinal/non-germinal center of a mutated B cell outside of CNS.<sup>6</sup> As the ABC- subtype is associated with worse prognosis in systemic DLBCL, it has a poor prognosis in the majority of PCNS DLBCL, owing to the

morphologically similar structures. The overall five-year survival in an immunocompetent patient would be 30% with the best treatment protocols.<sup>8</sup>

Craniotomy and excision of tumor in patients without any neurological deficits have shown to benefit the patient. As mentioned in some papers, surgical biopsy was preferred than surgical tumor reduction due to risk of postoperative neurological deficit and no benefit in overall survival.<sup>9</sup> With significant development made in the field of neurosurgery, gross total excision of tumor in patients with single lesion tumor and good performance status seems safe with reduction of postoperative neurological deficits.<sup>6</sup>

DeAngelis et al stated that high dose methotrexate (HD-MTX) and HD- cytarabine and whole brain radiotherapy are the main component of DLBCL-CNS therapy given to immunocompetent patients with progression free survival ranging from 36 months to 42 months.<sup>10</sup>

Antiviral therapy has improved the prognosis of patients with HIV associated NHL. Since CD4 counts, presence of AIDS and whether the patient is receiving cART influences the overall survival of the patient, proper selection of chemotherapy can benefit the patient.<sup>3</sup>

## Conclusion

Acute onset diplopia with proptosis is a rare extraocular clinical manifestation in PCNSL. Craniotomy with tumor mass reduction followed by chemo/radiotherapy is the management of choice in patients with DLBCL-CNS. The prognosis is good after complete excision of tumor and chemotherapy along with cART therapy.

**Conflict of Interest:** None

**Source(s) of support:** None

## References

1. Kasamon YL, Ambinder RF. AIDS-Related Primary Central Nervous System Lymphoma. **Hematology/Oncology Clinics of North America.** **2005**;19(4):665-87. <https://doi.org/10.1016/j.hoc.2005.05.004>
2. Wang X. Primary central nervous system germinal center B-like diffuse large B-cell lymphoma: a case report. **CCMBM.** **2017**;14(2):247. <https://doi.org/10.11138/ccmbm/2017.14.2.247>
3. Olszewski AJ, Fallah J, Castillo JJ. Human immunodeficiency virus-associated lymphomas in the antiretroviral therapy era: Analysis of the National Cancer Data Base: HIV-Associated Lymphomas: NCDB Analysis. **Cancer.** **2016**;122(17):2689-97. <https://doi.org/10.1002/cncr.30112>
4. Grommes C, DeAngelis LM. Primary CNS Lymphoma. **J Clin Oncol.** **2017**;35(21):2410-18. <https://doi.org/10.1200/JCO.2017.72.7602>
5. Grimm SA, McCannel CA, Omuro AMP, et al. Primary CNS lymphoma with intraocular involvement. **Neurology.** **2008**;71(17):1355-60. <https://doi.org/10.1212/01.wnl.0000327672.04729.8c>
6. Jelacic J, Todorovic Balint M, Raicevic S, et al. The possible benefit from total tumour resection in primary diffuse large B-cell lymphoma of central nervous system – a one-decade single-centre experience. **British Journal of Neurosurgery.** **2016**;30(1):80-5. <https://doi.org/10.3109/02688697.2015.1071328>
7. Dunleavy K, Wilson WH. Implications of the shifting pathobiology of AIDS-related lymphoma. **J Natl Cancer Inst.** **2013**;105(16):1170-1. <https://doi.org/10.1093/jnci/djt192>
8. Mahadevan A, Rao CR, Shanmugham M, Shankar SK. Primary central nervous system diffuse large B-cell lymphoma in the immunocompetent: Immunophenotypic subtypes and Epstein-Barr virus association. **Journal of Neurosciences in Rural Practice.** **2015**;6(01):8-14. <https://doi.org/10.4103/0976-3147.143171>
9. Ferreri AJM, Reni M, Pasini F, et al. A multicenter study of treatment of primary CNS lymphoma. **Neurology.** **2002**;58(10):1513-20. <https://doi.org/10.1212/wnl.58.10.1513>
10. De Angelis LM, Seiferheld W, Schold SC, Fisher B, Schultz CJ. Combination chemotherapy and radiotherapy for primary central nervous system lymphoma: Radiation Therapy Oncology Group Study. **J Clin Oncol.** **2002**;20(24):4643-8. <https://doi.org/10.1200/JCO.2002.11.013>