

# Craniopharyngioma arising from fourth ventricle


Binit Kumar Jha *MS*<sup>1</sup>, Prabhat Jha *MS*<sup>2</sup>, Rajiv Jha *MCh*<sup>3</sup>, Prakash Bista *MCh*<sup>4</sup>

<sup>1,2,3,4</sup>National Neurosurgical Referral Center, National Academy of Medical Sciences, Kathmandu, Nepal

Date of submission: 24<sup>th</sup> May 2020

Date of acceptance: 12<sup>th</sup> July 2020

Date of publication: 12<sup>th</sup> August 2020



## Abstract

Craniopharyngiomas usually involve the sellar and suprasellar space. Very few cases of craniopharyngiomas arising in the posterior fossa without extension to the sellar and suprasellar space have been reported in literature. This case describes a patient with craniopharyngioma confined only to the ventricular system.

**Key words:** Craniopharyngioma, Posterior fossa

## Introduction

Craniopharyngiomas arise from the ectodermal epithelium of the pharyngo-hypophyseal duct, which persists after involution of Rathke's cleft. They are dysodontogenic tumors with benign histology and malignant behavior with a tendency to invade surrounding structures.<sup>1,2</sup>

They are extra-axial partially cystic slow growing epithelial tumors and account for 1.2–4.6% of all intracranial tumors.<sup>3, 4, 5</sup> Craniopharyngiomas usually present as a single large cyst or multiple cysts filled with a turbid, proteinaceous, brownish yellow material that glitters owing to the high content of floating cholesterol crystals.

Craniopharyngiomas are primarily suprasellar tumors (75%) while a small intrasellar component is present in 20–25% of cases. Purely intrasellar location is quite uncommon (<5%). They can rarely occur in the infrasellar region, anterior, middle and posterior cranial fossa.<sup>6,10,11</sup>

Extension of craniopharyngiomas to the posterior cranial fossa occurs in 4–5.9% of cases.<sup>4</sup> Posterior fossa craniopharyngiomas may occur either as recurrence/extension or primary tumor (de novo). This case describes a craniopharyngioma confined to the fourth ventricle which is extremely rare.

## Case presentation

A 20-year-female presented with headache, vomiting and difficulty in walking for 1 month. Headache was mild to moderate in intensity, throbbing, mainly at the back of the head and non-radiating. Vomiting was non-projectile, containing ingested food particles, 7–8 episodes per day, non-bilious or blood stained. There was no history of trauma, loss of consciousness, abnormal body movements, fever or ear discharge. There is no history of hypertension, diabetes mellitus or tuberculosis. Her bowel and bladder habits were normal. She does not consume alcohol and she is a non-smoker.

On examination, her vital signs were within normal limits. Her Glasgow Coma Scale (GCS) was 15. Her pupils were bilateral round equal reactive to light. Her sensory, motor and cranial nerve examination were within normal limits. Signs of meningeal irritation were absent. The patient swayed towards the left side on standing, nystagmus was present on the left side and she had a wide stepping gait. The systemic examination was normal.

All other hematological and biochemical investigations were within normal limits.

Non-contrast computed tomography (CT) of head showed gross dilatation of lateral ventricles and third ventricle with lesion in fourth ventricle. (Figure 1)

### Access this article online

Website: <https://www.nepjol.info/index.php/NJN>

DOI: <https://doi.org/10.3126/njn.v17i2.30166>

### HOW TO CITE

Jha BK, Jha P, Jha R, Bista P. Craniopharyngioma arising from fourth ventricle. *NJNS*. 2020;17(2):51-54



<sup>1</sup>ORCID id: 0000-0002-0844-2538

<sup>2</sup>ORCID id: 0000-0001-5504-5917

<sup>3</sup>ORCID id: 0000-0002-2830-7835

<sup>4</sup>ORCID id: 0000-0002-4811-6964

### Address for correspondence:

Dr. Binit Kumar Jha

National Neurosurgical Referral Center

National Academy of Medical Sciences

Kathmandu, Nepal

Contact Number: 977-9851220978

E-mail: [binitjha.95@gmail.com](mailto:binitjha.95@gmail.com)

Copyright © 2020 Nepalese Society of Neurosurgeons (NESON)

ISSN: 1813-1948 (Print), 1813-1956 (Online)



This work is licensed under a Creative Commons Attribution-Non Commercial 4.0 International License.

Magnetic Resonance Imaging (MRI) of brain with contrast showed a ring enhancing cystic lesion in aqueduct and fourth ventricle with the cyst seen extending to the anterior recess of the third ventricle, small enhancing nodule in the anterior superior aspect of the aqueduct with considerable mass effect likely pilocytic astrocytoma. Moderate proximal obstructive hydrocephalus with periventricular seepage was seen. (Figure 2)

The patient underwent ventriculo-peritoneal shunt then midline suboccipital craniotomy with telovelar approach and excision of the mass.

Pre-operative findings were 2 x 3 x 3 cu mm sized easily suckable cystic mass arising from the 4th ventricle

with solid component likely nodule. The cystic component contained yellowish turbid fluid. The lesion was completely excised. The wall of the cyst was sent for histopathological examination which showed findings suggestive of craniopharyngioma WHO Grade I. The sections showed multiple fragments consisting of squamous epithelium arranged in lobules and trabeculae cells forming stellate reticulum, wet keratin and calcification. Pilooid cells, Rosenthal fibers and atypical features not seen. (Figure 3)

Postoperatively patient made an uneventful recovery with no neurological deficits. Patient was discharged on the 10th postoperative day. The Glasgow outcome score at discharge was 5/5. At follow-up of 6 months, the patient remains asymptomatic with no evidence of a recurrence.

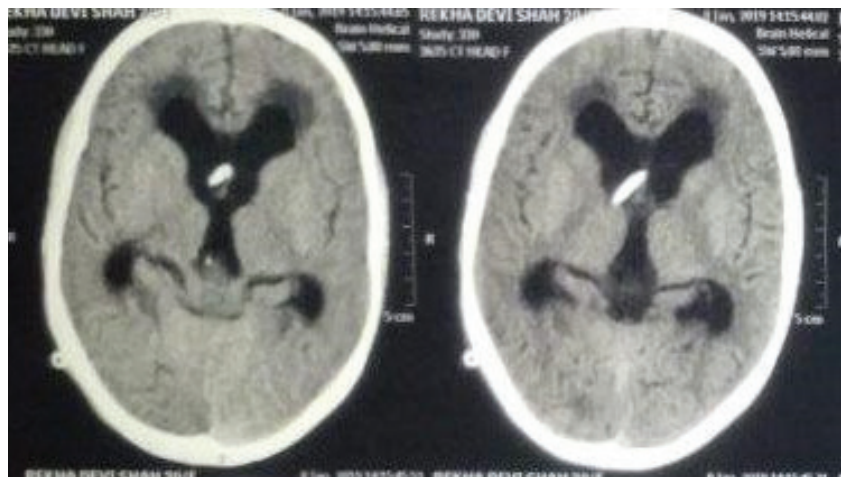
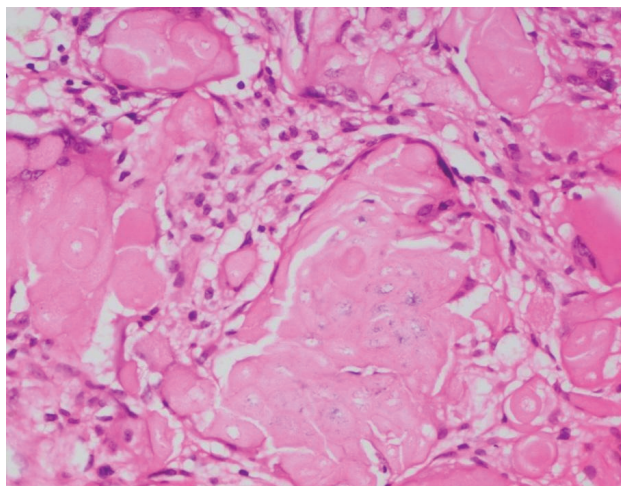


Figure 1: CT head of the patient after VP shunt

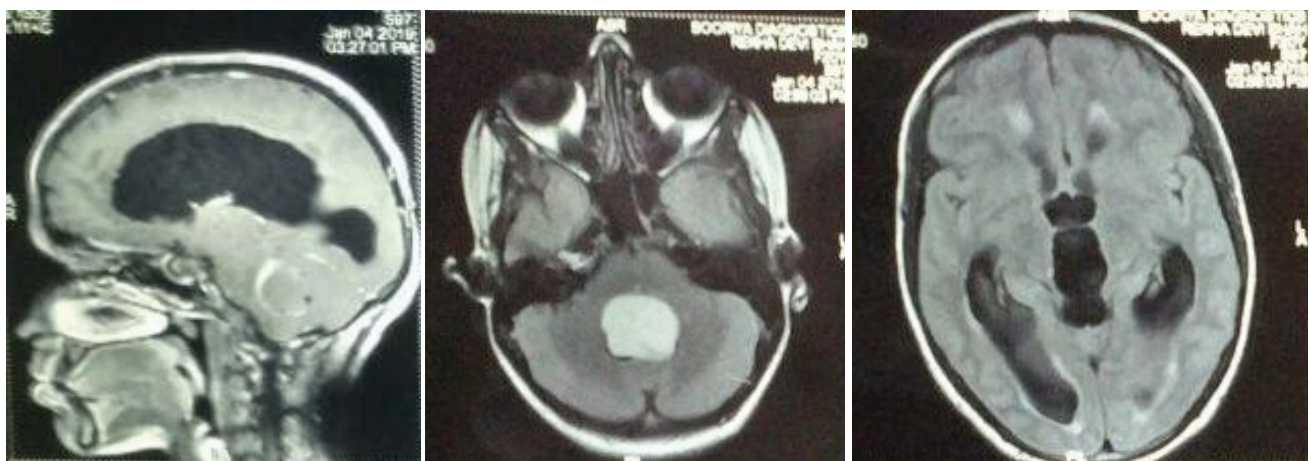

Figure 2: MRI head showing a mass lesion in fourth ventricle region with dilatation of third and lateral ventricles



**Figure 3:** Histopathological image of the tumor showing multiple fragments of tumor arranged in lobules

### Discussion

The first description of a craniopharyngioma was in 1857 by Zenker. The incidence ranges from 0.13 to 2 per 100,000 population per year, with a point prevalence of 1 to 3 per 100,000 population.<sup>7</sup> The tumor is equally common in males and females with no racial predilection. Distribution by age is bimodal with the peak incidence in children at 5–14 years and in adults at 65–74 years of age.<sup>8</sup> It accounts for 5% of all tumors in children and 50% of all sellar/para sellar tumours.<sup>7-9</sup>

Craniopharyngiomas are most commonly located extra-axially in the sellar or suprasellar area in 90% of cases.<sup>10</sup> They can extend to the infrasellar region (5% of cases) and anterior (2–5%), middle (2%), or posterior (1–4%) cranial fossa.<sup>11</sup>

Posterior fossa craniopharyngiomas are extremely rare.<sup>11</sup> They can be an extension of the suprasellar or sellar component. They can recur in posterior fossa after surgical resection of sellar or parasellar tumors. The third group involves craniopharyngiomas that arise de novo in the posterior fossa either in the cerebellopontine angle or in the fourth ventricle.<sup>12,13</sup>

Zhou L et. al. reported seven patients with pathologically proven craniopharyngiomas located in the posterior fossa. All tumors were located in the retrochiasmatic area with primary presentation of headache, diplopia and ataxia.<sup>14</sup> Hamit et. al. reported a case of craniopharyngioma originating in the posterior fossa three years after resection of craniopharyngioma in the suprasellar area.<sup>15</sup> Connolly et. al. reported three cases of giant posterior fossa craniopharyngiomas presenting with hearing loss. All tumors were extensions of those in sellar and suprasellar region.<sup>16</sup>

The occurrence can be explained by two hypotheses.<sup>5,17</sup> The embryogenetic theory suggests that the adamantinomatous type arises from epithelial remnants of the craniopharyngeal duct or Rathke's pouch along a line that extends from the vomer through the midline sphenoid bone to the floor of sella turcica. The metaplastic theory suggests that the squamous papillary type occurs as a result of metaplasia of squamous epithelial cell rests that are remnants of the part of the stomodeum that contributed to the buccal mucosa.<sup>5,17</sup>

The tumors located in posterior fossa usually present with symptoms of raised intracranial pressure. Algahtani et. al. reported a case of fourth ventricle craniopharyngioma presenting with headache and loss of consciousness.<sup>18</sup>

Diagnosis of tumors in the sellar and parasellar regions are usually done by Magnetic Resonance Imaging which shows a part solid/part cystic lesion with calcification and the diagnosis is confirmed on histopathological examination.<sup>19</sup> In our case, pilocytic astrocytoma was the provisional diagnosis but histopathological examination confirmed findings of craniopharyngioma.

### Conclusion

Posterior fossa craniopharyngioma is an extremely rare condition and is usually diagnosed on histopathological examination.

**Conflict of Interest:** None

**Source(s) of support:** None

### References

1. Stamm AC, Vellutini E, Balsalobre L. Craniopharyngioma. **Otolaryngol Clin North Am.** 2011;44(4):937-viii. <https://doi.org/10.1016/j.otc.2011.06.015>
2. Müller HL. Craniopharyngioma. **Handb Clin Neurol.** 2014; 124:235-53. <https://doi.org/10.1016/B978-0-444-59602-4.00016-2>
3. Makino K, Nakamura H, Yano S, Kuratsu J; Kumamoto Brain Tumor Group. Population-based epidemiological study of primary intracranial tumors in childhood. **Childs Nerv Syst.** 2010;26(8):1029-34. <https://doi.org/10.1007/s00381-010-1126-x>
4. Bunin GR, Surawicz TS, Witman PA, Preston-Martin S, Davis F, Bruner JM. The descriptive epidemiology of craniopharyngioma. **J Neurosurg.** 1998;89(4):547-51. <https://doi.org/10.3171/jns.1998.89.4.0547>
5. Aquilina K, O'Brien DF, Farrell MA, Bolger C. Primary cerebellopontine angle craniopharyngioma

- in a patient with gardner syndrome. Case report and review of the literature. **J Neurosurg.** **2006**;105(2):330-3. <https://doi.org/10.3171/jns.2006.105.2.330>
6. Price EB, Moss HE. Osborn's Brain: Imaging, Pathology, and Anatomy. **Neuroophthalmology.** **2014**;38(2):96-7. <https://doi.org/10.3109/01658107.2013.874459>
  7. Bunin GR, Surawicz TS, Witman PA, Preston-Martin S, Davis F, Bruner JM. The descriptive epidemiology of craniopharyngioma. **J Neurosurg.** **1998**;89(4):547-51. <https://doi.org/10.3171/jns.1998.89.4.0547>
  8. Daly AF, Rixhon M, Adam C, Dempegioti A, Tichomirowa MA, Beckers A. High prevalence of pituitary adenomas: a cross-sectional study in the province of Liege, Belgium. **J Clin Endocrinol Metab.** **2006**;91(12):4769-75. <https://doi.org/10.1210/jc.2006-1668>
  9. Haupt R, Magnani C, Pavanello M, Caruso S, Dama E, Garre ML. Epidemiological aspects of craniopharyngioma. **J Pediatr Endocrinol Metab.** **2006**; 19:289-93.
  10. Carmel PW, Antunes JL, Chang CH. Craniopharyngiomas in children. **Neurosurgery.** **1982**;11(3):382-9. <https://doi.org/10.1227/00006123-198209000-00008>
  11. Sener RN, Kismali E, Akyar S, Selcuki M, Yalman O. Large craniopharyngioma extending to the posterior cranial fossa. **Magn Reson Imaging.** **1997**;15(9):1111-2. [https://doi.org/10.1016/s0730-725x\(97\)00137-9](https://doi.org/10.1016/s0730-725x(97)00137-9)
  12. Link MJ, Driscoll CL, Giannini C. Isolated giant cerebellopontine angle craniopharyngioma in a patient with Gardner syndrome: case report. **Neurosurgery.** **2002**;51(1):221-6. <https://doi.org/10.1097/00006123-200207000-00033>
  13. Powers CJ, New KC, McLendon RE, Friedman AH, Fuchs HE. Cerebellopontine angle craniopharyngioma: case report and literature review. **Pediatr Neurosurg.** **2007**;43(2):158-63. <https://doi.org/10.1159/000098394>
  14. Zhou L, Luo L, Xu J, et al. Craniopharyngiomas in the posterior fossa: a rare subgroup, diagnosis, management and outcomes. **J Neurol Neurosurg Psychiatry.** **2009**;80(10):1150-4. <https://doi.org/10.1136/jnnp.2008.149088>
  15. Hamit ZG, Egemen N, Ildan F, Bacaci K. Craniopharyngioma of the Posterior Fossa. **Neurosurgery.** **1991**;29(3):446-8. <https://doi.org/10.1227/00006123-199109000-00020>
  16. Connolly ES Jr, Winfree CJ, Carmel PW. Giant posterior fossa cystic craniopharyngiomas presenting with hearing loss. Report of three cases and review of the literature. **Surg Neurol.** **1997**;47(3):291-9. [https://doi.org/10.1016/s0090-3019\(96\)00253-4](https://doi.org/10.1016/s0090-3019(96)00253-4)
  17. Miller DC. Pathology of craniopharyngiomas: clinical import of pathological findings. **Pediatr Neurosurg.** **1994**;21 Suppl 1:11-7. <https://doi.org/10.1159/000120855>
  18. Algahtani AY, Algahtani HA, Jamjoom AB, Samkari AM, Marzuk YI. De novo Craniopharyngioma of the Fourth Ventricle: Case Report and Review of Literature. **Asian J Neurosurg.** **2018**;13(1):62-5. <https://doi.org/10.4103/1793-5482.185063>
  19. Rossi A, Cama A, Consales A, et al. Neuroimaging of pediatric craniopharyngiomas: a pictorial essay. **J Pediatr Endocrinol Metab.** **2006**;19 Suppl 1:299-319.