

**Ashish Jung Thapa MS**

Centre for minimally Invasive Brain and Spine Surgery  
Aditya Super-specialty Hospital, Jabalpur, India  
ORCID iD: <https://orcid.org/0000-0002-1571-604X>

**Asheesh Tandon MCh**

Centre for minimally Invasive Brain and Spine Surgery  
Aditya Super-specialty Hospital, Jabalpur, India  
ORCID iD: <https://orcid.org/0000-0002-7215-1612>

**Alok Agrawal MCh**

Centre for minimally Invasive Brain and Spine Surgery  
Aditya Super-specialty Hospital, Jabalpur, India  
ORCID iD: <https://orcid.org/0000-0003-3733-4162>

**Address for correspondence:**

Dr. Ashish Jung Thapa  
Centre for minimally Invasive Brain and Spine Surgery  
Aditya Super-specialty Hospital, Jabalpur  
Napier Town, Jabalpur 482002, Madhya Pradesh, India  
E-mail: [zenith\\_horizan@yahoo.com](mailto:zenith_horizan@yahoo.com)  
Contact number: +91 9691808598

**Date of submission:** 23<sup>rd</sup> February 2020

**Date of acceptance:** 25<sup>th</sup> March 2020

DOI: <https://doi.org/10.3126/njn.v17i1.28346>

**HOW TO CITE**

Thapa AJ, Tandon A, Agrawal A. Giant Intracerebral Hydatid Cyst in a boy. NJNS. 2020;17(1):44-47

To access Nepal Journal of Neuroscience Archives, scan QR code:



## Giant Intracerebral Hydatid Cyst in a boy

**Abstract**

Giant intracerebral hydatid cysts are an extremely rare condition caused by the infestation of larvae of *Taenia echinococcus* (TE). Humans are infected through the feco-oral route by the ingestion of food and milk, contaminated by dog feces containing the ova of parasite or direct contact with dogs. We report a case of a seventeen-year-old boy with giant right temporo-parieto-occipital hydatid cysts (HC).

Giant intracerebral hydatid cysts being rare and can at times lead to death, so surgical excision with pre-operative consideration and intraoperative rupture prevention is the best management for a better prognosis.

**Key words:** Cerebral, Giant, Hydatid cyst, Multiple

**Introduction**

Hydatid is a word derived from Greek meaning-a cyst containing watery fluid and a tapeworm larva. The most common species causing a human infection is *Echinococcus granulosus*. Hydatid cysts of the brain are usually single, spherical and unilocular. Multiple cysts are extremely rare.<sup>1</sup> 50 to 75% of the intracranial hydatid cyst is encountered in children.<sup>2</sup> CNS involvement is associated with features of raised intracranial pressure. Surgical excision followed by a long course of albendazole remains the mainstay of treatment. We describe a giant hydatid cyst mass in a young boy with a successful and complete excision of the cyst.

**Case Report**

A seventeen-year male presented in our outpatient department with chief complaints of generalized episodic headache, progressive for eight months associated with visual blurring. There was a history of recurrent left-sided focal seizures with secondary generalization for three months, with no other significant history with no focal neurologic deficits. His medical and family history was unremarkable. Fundoscopic examination revealed bilateral papilledema.

Laboratory tests and chest x-ray were unremarkable.

Brain computed tomography (CT) demonstrated a large polycystic mass with thin-walled septae with peripheral enhancement (Figure 1). Magnetic resonance imaging (MRI) demonstrated a huge mass of multiple cystic lesions extending into the right parieto-temporo-occipital region with midline shift to the left side (Figure 1). The lesion was well defined, hypo-intense on T1 weighted images and hyper-intense on T2 weighted images. The cystic mass showed multiple septae on T1 weighted images. There was evidence of perilesional edema on T2 weighted and FLAIR images. There was evidence of thin enhancement of the peripheral cyst wall on contrast MRI.

Based on the above mentioned findings, a provisional

diagnosis of hydatid cyst was made. Right temporo-parietal craniotomy was done for excision of the cyst. The surrounding brain was covered with a moist saline pack. Gradual and careful dissection of the individual cyst was undertaken to avoid rupture and spillage of cyst content. The complete excision of the lesion was achieved (Figure 2). Histopathology confirmed the diagnosis of hydatid cysts. Postoperatively the patient was initiated on Oral Albendazole. Follow up MRI on two months after surgery revealed a residual cavity with no remnant cyst (Figure 2). In a year of follow up, he has been free of headache and visual blurring however he has suffered two episodes of seizures and mild left-sided incoordination.

### Discussion

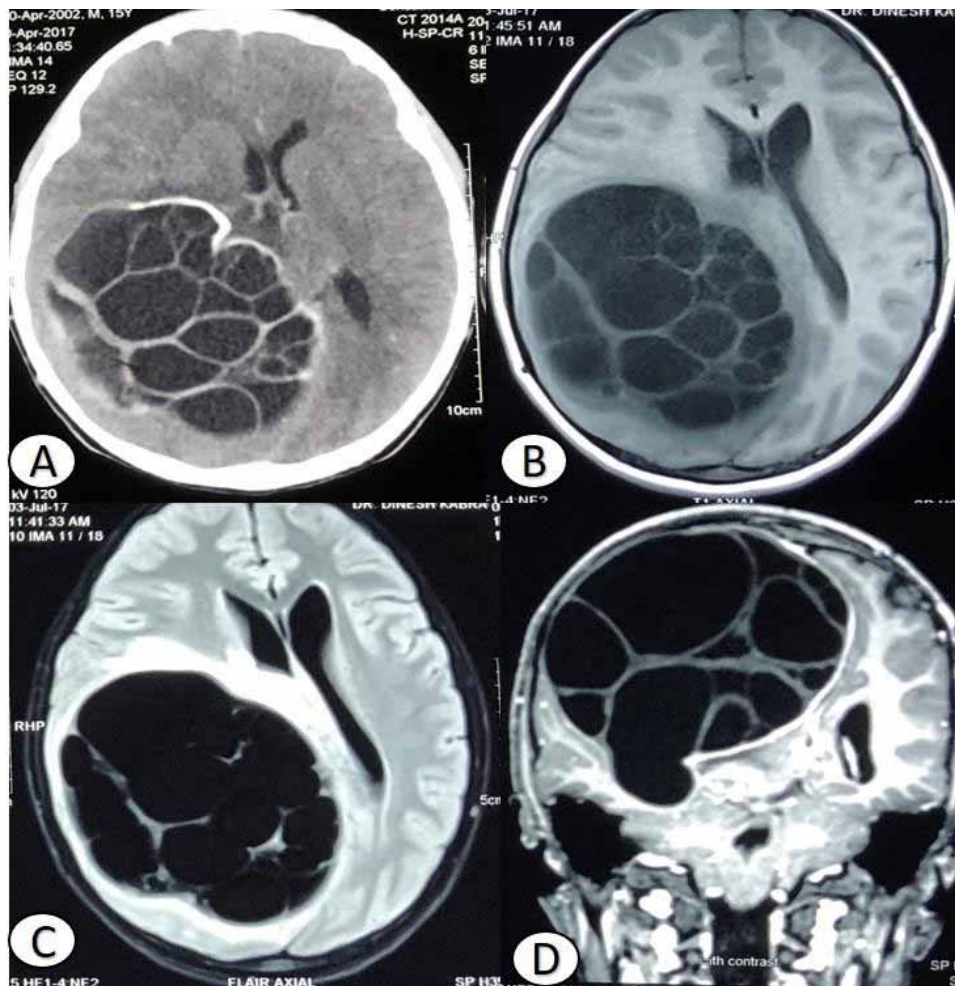


Figure 1. (A) Contrast-enhanced CT Brain showing multi septate cyst with enhancement in right parieto-temporal area. (B) T1W Axial MRI brain showing multiple cystic lesion in right parieto-temporal area with mass effect. (C) Flair MRI with axial section suggestive of peri-cystic edema and midline shift. (D) Contrast-enhanced MRI coronal image showing peripheral enhancement with multiple hydatid cysts

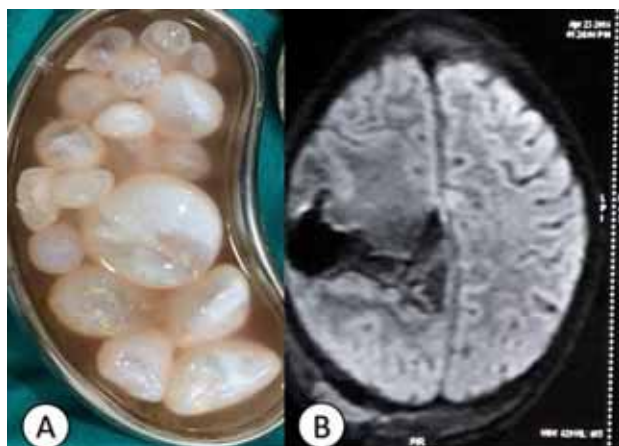


Figure 2. (A) Intraoperative snap of excised cysts. (B) Postoperative MRI axial image showing excised cyst with residual cavity

Intracranial hydatid disease accounts for 0.5-3% of all the cases of hydatid disease.<sup>6</sup> Giant intracranial hydatid cyst is very rare, with a reported incidence of 1-2% of all cases of hydatid cyst.<sup>9</sup> Hydatid disease is endemic in the Middle East, Mediterranean countries, South America, North Africa, and Australia.<sup>5</sup> Definitive hosts are dogs, wolves, and other carnivores, sheep and cattle are the intermediate hosts and humans, the accidental intermediate hosts get infected through food or water containing echinococcus eggs. The larvae escaping the filtering mechanism of the liver reach the lungs from where they enter the systemic circulation and other organs. The larva in the organ escapes host immunity cysts, daughter cysts, and scolexes are then formed. Cerebral hydatid cysts grow about 1 cm in diameter per year which may be more rapid in children.<sup>3</sup> Multiple cerebral cystic echinococcus lesions are extremely rare and usually occur in the supra-tentorial area involving the watershed area of the middle cerebral artery, especially the parietal lobe.<sup>8</sup> Intracranial cerebral hydatid cyst can be classified as primary (single) or secondary (multiple).<sup>12</sup> A total of 17 cases were reported of intra-cerebral multiple hydatid cysts,<sup>10</sup> the slow development of symptoms and late neurological deficits are often preceded by signs of increased intracranial pressure. Focal neurological deficits like hemiparesis, visual deficit, diplopia, gait disorder, and seizures occur depending on the location of the cyst.<sup>1</sup>

Preoperative suspicion is crucial for surgical planning and good outcome and can be diagnosed using CT scans or MR imaging. A large intra-parenchymal, well-defined border cystic lesion is seen on CT scans, rim enhancement and peri-cystic edema are less common. On T2W images, it appears as a cystic lesion with a hypo-intense halo around the cyst capsule<sup>4</sup> and can be differentiated from

others like brain abscess and cystic astrocytoma by the absence of significant rim enhancement, peri-focal edema, and mural nodule.<sup>2</sup> Other differentials include arachnoid cysts, epidermoid cysts, enlarged perivascular spaces, neurological cysts, and porencephalic cysts.<sup>10</sup>

Intact and complete removal of hydatid cysts remains the treatment of choice and the hydro-dissection technique being the best method for intact delivery. Extra precautions during excision to prevent premature rupture during the extirpation of the multiple cysts. Many reports suggest that the Dowling technique is the most effective approach for the removal of cerebral hydatid cysts.<sup>2</sup> The cyst wall adhesions can be troublesome so excision with microsurgical tools is essential. Premature rupture can be catastrophic, saline should not be used to kill the larvae because it could cause an anaphylactic reaction, chemical meningitis or serious neurological deficits.<sup>9</sup> Although the aspiration may facilitate the removal of these cysts, it carries the risk of contamination if contents are spilled. In cases where the hydatid cyst is giant, there may be no cortical tissue between the cyst wall and dura as in our case. In such a situation meticulous dural opening with fine micro scissors is required to avoid any damage to the wall of cysts that lie just below the dura and thereby preventing cyst rupture.

Although the primary treatment is surgery, pre- and postoperative administration of albendazole should be considered. It helps to sterilize the cyst, decreases the chance of anaphylaxis, decreases the tension in the cyst wall and lowers the risk of recurrence. Albendazole is prescribed at a dosage of 10 to 15 mg/kg/day and administration should be continuous without interruption. However, the optimal dosage of albendazole and the optimal duration of treatment is still unknown. In the present case, we have used a total dose of 400mg twice daily and intend to continue for a period of 6 months as per the available literature.<sup>9,11</sup>

## Conclusion

Giant cerebral hydatid cysts are a rare occurrence and consequences of raised ICP precedes the symptoms and neurological deficits become inevitable. The surgical excision with preoperative consideration and intraoperative rupture prevention is the best management for a better prognosis.

## References

1. Duishanbai S, Jiafu D, Guo H, Liu C, Liu B, Aishalong M, et al. Intracranial hydatid cyst in children: report of 30 cases. *Childs Nerv Syst.* 2010; 26:821-7.

- <https://doi.org/10.1007/s00381-009-1008-2>
- Ersahin Y, Mutluer S, Guzelbag E. Intracranial hydatid cysts in children. **Neurosurgery.** **1993**; 33:219–24. PMID: 8367043
  - Reddy DR. Managing cerebral and cranial hydatid disease. **Neurol India.** **2009**; 57:116-8. <https://doi.org/10.4103/0028-3886.51276>
  - Siraj MU, Glasgow F, Haq MU, Imran M. A giant intracranial hydatid cyst excised in toto; Case report and review of literature. **Anaesth Pain & Intensive Care.** **2010**; 14(2):112-4. Corpus ID: 181327057
  - Onal C, Barlas O, Orakdögen M, Hepgül K, Izgi N, Unal F. Three unusual cases intracranial hydatid cyst Pediatric age group. **Pediatr Neurosurg.** **1997**; 26:208–13. <https://doi.org/10.1159/000121193>
  - Evliyaoglu C, Yuksel M, Gul B, Kaptanoglu E, Yaman M. Growth rate of multiple intracranial hydatid cysts assessed by CT from the time of embolisation.
  - Sierra J, Oviedo J, Berthier M, Leiguarda R. Growth rate of secondary hydatid cysts of the brain. Case report. **J Neurosurg.** **1985**; 62:781–2. <https://doi.org/10.3171/jns.1985.62.5.0781>
  - Gupta S, Desai K, Goel A. Intracranial hydatid cyst: a report of five cases and review of literature. **Neurol India.** **1999**; 47:214–7. PMID: 10514582
  - Cavuşoğlu H, Tuncer C, Ozdilmaç A, Aydın Y. Multiple Intracranial Hydatid Cysts in a Boy. **Turk Neurosurg.** **2009**; 19:203-7. PMID: 19431138
  - Izci Y, Tüzün Y, Seçer HI, Gönül E. Cerebral hydatid cysts: technique and pitfalls of surgical management. **Neurosurg Focus.** **2008**; 24: E15. <https://doi.org/10.3171/FOC/2008/24/6/E15>
  - Chen S, Li N, Yang F, Wu J, Hu Y, Yu S, et al. Medical treatment of an unusual cerebral hydatid disease. **BMC Infect Dis.** **2018 Jan**; 18(1):12. <https://doi.org/10.1186/s12879-017-2935-2>.