

Case Report

Puspa Raj Koirala, MBBS, MS

Third year MCh Neurosurgical Resident, Institute of Medicine, Tribhuvan University Teaching hospital, Kathmandu, Nepal

Suman Phuyal, MBBS, MS,

Second year MCh Neurosurgical Resident, Institute of Medicine, Tribhuvan university Teaching Hospital, Kathmandu, Nepal

Gopal Sedain MS, MCh,

Assistant Professor, Department of Neurosurgery, Institute of Medicine, Tribhuvan University Teaching Hospital, Kathmandu, Nepal

Sushil Krishna Shilpakar MS

Professor, Head of Department, Department of Neurosurgery, Tribhuvan University Teaching Hospital, Kathmandu, Nepal

Address for correspondence:

Puspa Raj Koirala
Department of Neurosurgery, Tribhuvan University Teaching Hospital, Kathmandu, Nepal

Date submitted : 19/2/2019

Date accepted : 5/5/2019

Nepal Journal of Neurosciences 16:58-61, 2019

Isolated Intraspinal Neurenteric Cyst, Mimicking Arachnoid Cyst: A Case Report

Neurenteric cysts account for 0.7-1.3% of spinal axis tumors. These uncommon lesions result from the inappropriate partitioning of the embryonic notochordal plate and presumptive endoderm during the third week of human development. Heterotopic nests of epithelium reminiscent of gastrointestinal and respiratory tissue lead to eventual formation of compressive cystic lesions of the pediatric and adult spine. We report a 40-year-old male presenting with slow-progressive myelopathic manifestation and ovoid non-enhancing cystic intradural extramedullary lesion at C7 level on MRI, mimicking intraspinal arachnoid cyst, who underwent successful surgical excision. The histopathological examination proved it to be a neurenteric cyst.

Keywords: Neurenteric cyst Intraspinal tumor

Neurenteric cyst (also known as endodermal cyst, enterogenous cyst, enteric cyst) is a congenital cystic lesion of the spine, lined with endoderm. They result from failure of separation of ectoderm from the endoderm during the third week of embryonic life with persistent canal of Kovalevsky. The eventual abnormality depends on the extent to which this adhesion subsequently disappears. Persistence of the entire primitive neurenteric canal results in vertebral anomalies, whereas persistence of only part of the canal results in isolated intraspinal cyst.

Kubie and Fulton in 1928 first described this lesion as *teratomatous cysts* and later elaborated by Puusepp in 1934 as *intestinomas*. Holcomb and Matson coined the term “neurenteric cyst” in 1954.¹⁻³ Neurenteric cysts account for 0.7-1.3% of all spinal cord tumors.⁴ Approximately 90% of neurenteric cysts are located in

the intradural extramedullary compartment while the remaining 10% are divided between an intramedullary or extradural location.⁵

Isolated intraspinal neurenteric cyst mainly occurs in the cervical region. The clinical presentation may vary from a simple isolated intraspinal cyst with no other abnormalities to that of multiple visceral and vertebral anomalies. We report such a case of isolated intraspinal neurenteric cyst with no vertebral or visceral abnormality.

Case History

A 40-year-old male patient from Terai presented with continuous tingling of bilateral lower limbs for 6 months, followed by feeling of tightness in both thighs, abdomen and lower chest. Later, due to the progressive weakness of

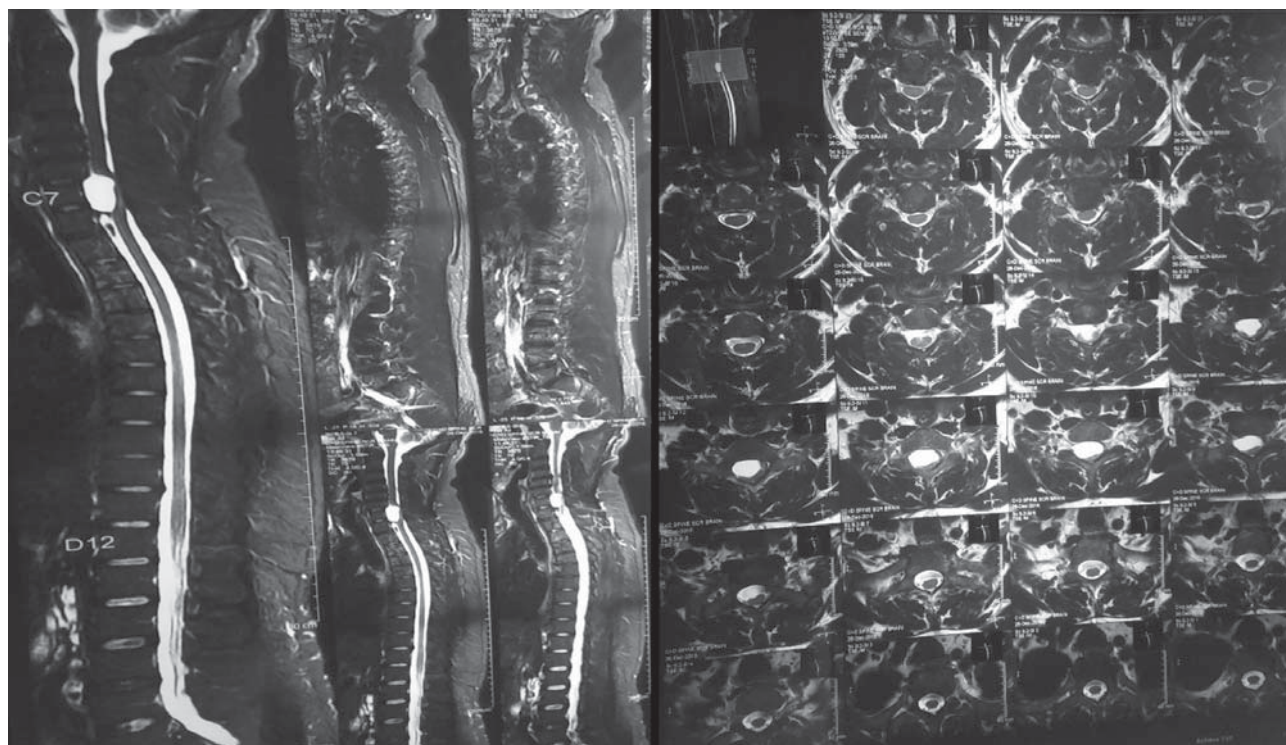


Figure 1: MRI showing T1 hypointense and T2 hyperintense ovoid non-enhancing intradural extramedullary cystic lesion located ventral to spinal cord at C7 level.

both lower limbs, he was unable to walk independently. In past, there was no history of trauma or fever. Neurological exam revealed nearly 5/5 power in all four limbs; however, severe spasticity in both lower limbs with upgoing plantar reflexes and prominent ankle clonus bilaterally. The anal sphincter tone was normal and there were no abnormal spinal reflexes such as bulbocutaneous or anocutaneous reflexes.

Magnetic resonance imaging of spine revealed ovoid non-enhancing cystic intradural extramedullary lesion located ventral to the spinal cord at C7 vertebra. The spinal cord was severely compressed posteriorly with subtle signal changes. (**Figure 1**) The MRI features were more consistent with intraspinal arachnoid cyst.

Preoperatively, a diagnosis of spinal arachnoid cyst was made, and the patient underwent cervicothoracic laminectomy with excision of cyst.

The patient was intubated, given general anesthesia and turned prone on Wilson's C-frame with adequate foam padding and hanging abdomen. A midline longitudinal posterior incision was made extending from spinous processes of C5 to T2 spine was made. The paraspinal muscles were dissected on both sides and lamina of C6 to T1 was exposed. Using Stryker neuroelectric drill, zip laminectomy of C6 to T1 was achieved. The dura was then incised in the midline, using number 15 scalpel blade, and extended on both ends, using Dandy nerve hook

protecting the arachnoid layer. The Intraoperative findings was thickened arachnoid with adhesions above and below the cystic lesion. The cord was observed to be displaced to the left side. The cyst was adherent with the arachnoid with thickened whitish layer extending ventral to the spinal cord at C7 level. The intradural cyst was completely dissected and resected including the attachment at ventral aspect of C7 level with marsupialization. After complete decompression of the cord, the dura incision was closed with continuous 4-0 vicryl suture in water-tight fashion. Finally, laminoplasty was achieved by placing the cut piece of lamina and spinous processes of C6 to T1, using 1-0 silk sutures bilaterally.

The histopathological specimen was processed and stained with Hematoxylin and Eosin. Microscopic examination revealed a cyst lined with ciliated pseudostratified columnar epithelium with focal areas of goblet cells as well. The wall showed fibrocollagenous tissue. The findings were consistent with neuroenteric cyst. (**Figure 2, 3**)

The postoperative course was uneventful. The patient was allowed to ambulate after 48 hours of surgery. The tightness below the waist disappeared. He was able to ambulate independently without support and there was significant improvement in the spastic gait. There was no bowel and bladder incontinence. He was discharged on postoperative day 10 after removal of staples.

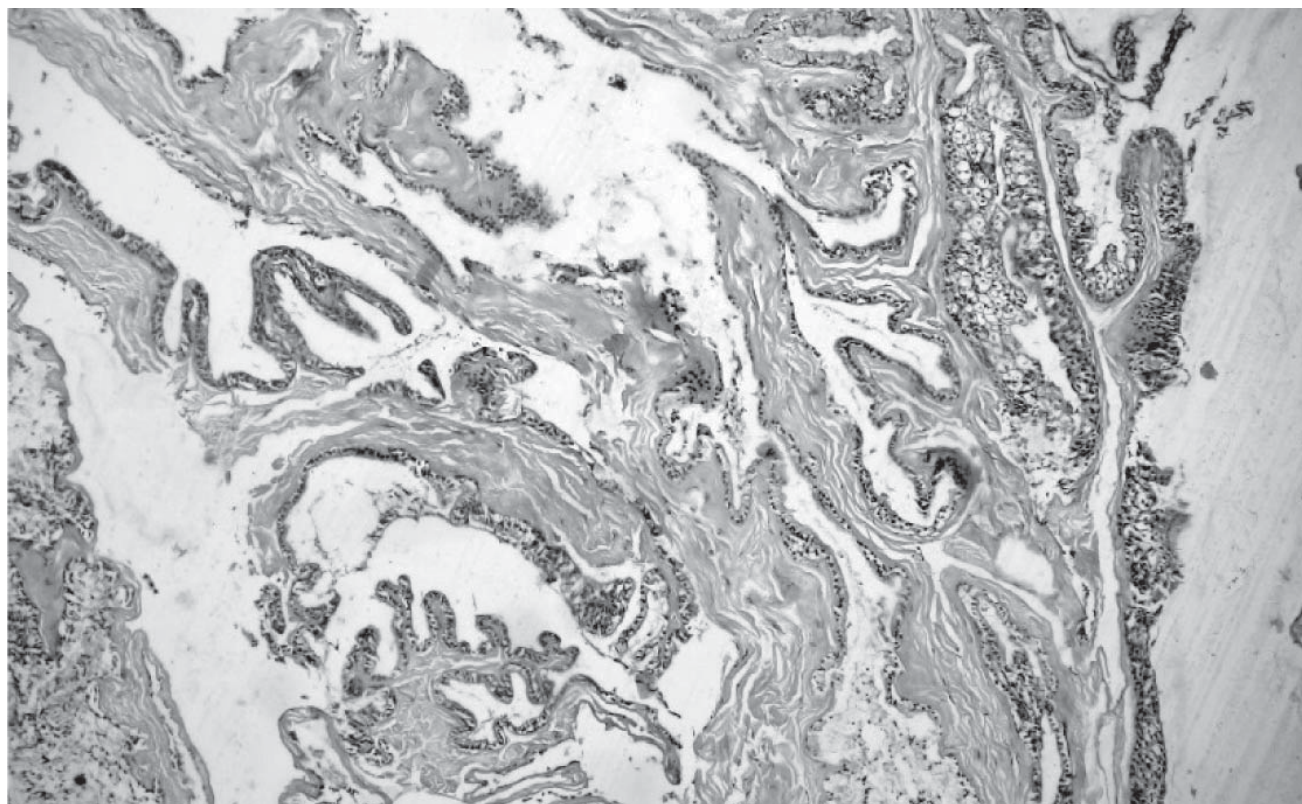


Figure 2: Low power view showing cystic structures resting on underlying stroma and columnar to cuboidal lining epithelium. (H and E stain x 100)

Discussion

The term intraspinal enterogenous cyst was used for the first time by Harriman to describe cysts previously known as endodermal or respiratory cysts. The age of presentation varies from 5 weeks to 52 years.⁶ These cysts are usually smooth, unilocular, most commonly located at the lower cervical or upper thoracic region and rarely in the lumbar region. The cysts uncommonly occur intracranially where they are located in the pons, cerebellopontine angle cistern or rarely in the foramen magnum.⁸ The most common location is the cervico-dorsal region similar to our case of 40-year-old male.

Various theories have been proposed to explain the embryological basis of these cysts. The main assumption postulates that the cyst forms as a result of primary adhesion of endoderm anterior to the notochord, incomplete fusion of the notochord, persistence of the neurenteric canal or formation of a split notochord and displacement of endodermal cells.⁹ Hemivertebrae, unsegmentation of vertebrae, spina bifida, and clefts in the vertebral bodies are all vertebral abnormalities that can be associated with neurenteric cysts. In our case, only a solitary cyst with thickened arachnoid and adhesions were noted. There was no vertebral or visceral anomalies.

Though neurenteric cysts are typically endodermal-lined cysts, histological variants were described and classified by Wilkins & Odome.

Histological classification of Neurenteric cyst (modified after Wilkins and Odome)

Type I Single pseudostratified, cuboidal or columnar epithelium with or without cilia lying on a basement membrane.

Type II Similar to type I with addition of mucous glands, serous glands, smooth muscle, fat, cartilage, bone, elastic fibres, lymphoid tissue or nerve ganglion.

Type III Similar to type I with addition of ependymal or glial tissue.

Based on the above description, our case belonged to type 1 with presence of pseudostratified, cuboidal and columnar epithelium.

The choice of surgical technique varies according to the type of cyst and its exact anatomical location. However, surgical exploration is aimed at preventing spinal cord compression and cyst refilling after surgery. To achieve complete decompression of cord and prevent recurrence of the cyst, in our case, the cystic lesion was dissected completely and excised including the attachment ventral to the cord, followed by complete marsupialization and adequate adhesionolysis of arachnoid adhesions.

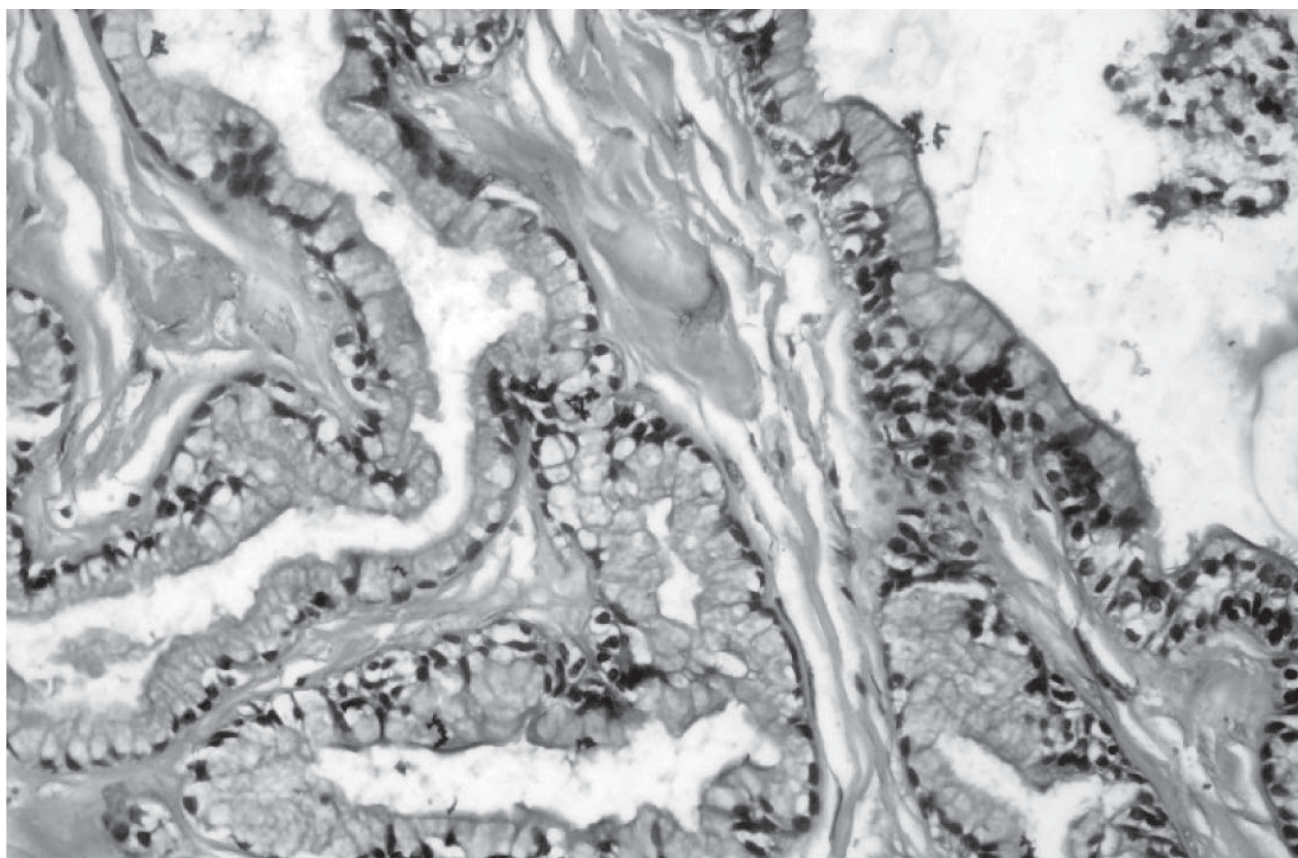


Figure 3: Higher magnification showing cyst lined by simple columnar epithelium resting upon collagenous stroma. (H and E stain x 400)

Conclusion

Intraspinal neuroenteric cyst is a benign embryological defect, which is diagnosed histopathologically and mostly requires simple excision. Due to similar clinical myelopathic presentation and non-specific radiological features, it may mimic arachnoid cyst in the spine preoperatively. For any patient presenting with myelopathic symptoms and cystic lesion on MRI, one needs to consider neuroenteric cyst as one of the differential diagnosis.

References

- Holcomb GW, Jr, Matson DD. Thoracic neuroenteric cyst. **Surgery** **35**:115–21, 1954
- Kubie LS FJF. A clinical and pathological study of two teratomatous cysts of the spinal cord, containing mucus and ciliated cells. **Surg Gynec Obstet** **47**:297–311, 1928
- Puusepp M. Variete rare de teratome sous-dural de la region cervicale (intestinome) **Rev Neurol Paris** **2**:879–86, 1934
- Fortuna A, Mercuri S. Intradural spinal cysts. **Acta Neurochir (Wien)** **68**:289–314, 1983
- Lippman CR, Arginteanu M, Purohit D, Naidich TP, Camins MB. Intramedullary neuroenteric cysts of the spine. Case report and review of the literature. **J Neurosurg** **94**:305–9, 2001
- Miyagi K, Mukawa J, Mekaru S, Ishikawa Y, Kinjo T, Nakasone S. Enterogenous cyst in the cervical spinal canal. Case report. **J Neurosurg** **68**: 292–6, 1988
- Mann KS, Khosla VK, Gulati DR, Malik AK), Spinal Neuroenteric cyst. Association with Vertebral anomalies, diastematomyelia, dorsal fistula, and lipoma. **Surg Neurol Apr**; **21** (4):358–62, 1984
- Lee WY, Tsir, HM, MC, Chuang SM. J Neuroenteric cyst at craniocervical junction: report of a case. **Formos Med Assoc Jul**; **91** (7): 722–24, 1992
- Macdonald RL, Schwartz ML, Lewis AJ. Neuroenteric cyst located dorsal to the cervical spine: case report. **Neurosurgery** **28**: 583–7, 1991