

Dr Balgopal Karmacharya MS, FCPS

Manipal Teaching Hospital
Phulbari, Pokhara 33701
Nepal

Dr Nikunja Yogi MS, MCh

Manipal Teaching Hospital
Phulbari, Pokhara 33701
Nepal

Dr Benju Pun, MBBS

Manipal Teaching Hospital
Phulbari, Pokhara 33701
Nepal

Address for correspondence:

Dr Balgopal Karmacharya
Manipal Teaching Hospital
Phulbari, Pokhara 33701, Nepal
Mobile: 9856033726
Email: dr.balgopal@hotmail.com

Date submitted : 18/12/2018

Date accepted : 28/4/2019

Surgical Outcome Of Isolated Extradural Hematomas Operated In A Teaching Hospital In Western Nepal

The aim of this determine the causes, frequency, location of isolated extradural hematomas in patients presenting with head injury and to find out the outcome of surgery in such patients. This is prospective observational study was conducted in the Neurosurgery Unit of Manipal Teaching Hospital from January 2012 to January 2017. All patients who presented with head injury and had isolated extradural hematomas were included in the study. Total number of patients admitted with diagnosis of extradural hematomas during that time period was 169 among which 94 patients underwent surgical treatment. Descriptive statistics data including age, gender, causes of injury, severity of head injury and Glasgow outcome scale were studied. Results in proportion and percentages were calculated by using Microsoft Excel 2013.

There were 169 patients who had isolated extradural hematomas. Among them, 75 patients were managed conservatively and 94 underwent craniotomy for evacuation of hematoma. This group of 94 patients who operative treatment was taken for this study. Male: female ratio was 1.6:1. Mean age was 23 years. Most of patients were in 20-40 age groups. Causes of extradural hematomas included motor vehicle accidents, falls and assaults. Mild and moderate head injury was present in 53 (56.38%) and 32 (34.0%) patients. Seventy nine patients (84.05%) of patients had good recovery while 3 (3.19%) patients expired.

Key Words: extradural hematoma, Glasgow Coma Scale, Glasgow Outcome Scale

An extradural hematoma results when bleeding occurs between the tough outer membrane covering the brain, the dura mater and the skull. It is a type of extra axial hematomas. As the hematoma expands it

strips the dura from inside of the skull. It is more common in young adults. It is rare in older population as they have very tightly adhered dura to bone. Even though extradural hematomas are relatively uncommon (<1% of all patients

with head injuries and <10% of those who are comatose), they should always be considered in evaluation of serious head injuries because patients with epidural hematomas who meet surgical criteria and receive prompt surgical intervention can have an excellent prognosis.⁸ Classically a patient with extradural hematoma loses consciousness transiently following injury, and then becomes fully conscious. As the hematoma enlarges and compresses the brain he or she becomes unconscious again. This is called lucid interval. Extradural hematomas result from injury to meningeal arteries or dural sinuses and are mostly result of fracture of overlying skull bone. As fractures result from local impact, such patients usually do not have underlying brain injuries. The neurological deficits are due to compression of brain and so they make good recovery following evacuation of hematomas.

This study was done to determine the causes and location of isolated extradural hematomas and their surgical outcome in patients in Manipal Teaching Hospital in Pokhara.

Methods and Materials

The study was carried out in Manipal Teaching Hospital, Phulbari Pokhara Nepal. The study was a prospective observational study. Institutional review board approval was taken from the hospital for the study. Consent was taken from the patients if they were able to communicate and from the next of kin if they were not able to give consent. Inclusion criteria was isolated extradural hematomas in all age groups and both genders. Patients with extradural hematomas with other intracranial injuries like contusions, subdural hematomas, and traumatic subarachnoid hemorrhage were excluded. The duration of the study was from January 2012 to January 2017. All patients who had isolated extradural hematomas and underwent surgery for evacuation of their hematomas were included in the study. The cause of injury, age and gender of patients and Glasgow coma score at admission were noted. Patients were followed for at least for one month after discharge from hospital. Outcome was assessed based on Glasgow outcome score at 1 month.

Results

During this study period, 169 patients with isolated extradural hematomas were admitted in Manipal Hospital. Among them 75 were treated conservatively and 94 were operated for evacuation of hematomas. There were 58 male and 36 female patients. Male: female ratio was 1.6:1.

Age group of patients is shown in Table 1. Half the patients were young age group from 20-40 years. Motor

vehicle accident was the commonest cause for extradural hematomas and contributed to half of patients. This was followed by falls from height. Physical assaults and sports related injuries contributed to remaining causes Table 2. Temporal area was commonest location for extradural hematoma followed by frontal and parietal location. About 10% of patients had posterior fossa extradural hematomas Table 3.

Age group	Number of patients	Percentage
<10 yrs	8	8.51
10-20	17	18.09
20-30	32	34.04
30-40	22	23.4
40-50	6	6.38
50-60	5	5.32
60-70	3	3.19
>70	1	1.07
Total	94	100

Table 1: Age Distribution of patients

Causes for injury	Number of patients	Percentage
Motor vehicle accidents	49	52.12
Falls	32	34.04
Physical assault	10	10.64
Sports related injury	3	3.2
Total	94	100

Table 2: Causes of head injury

Location of hematoma	Number of patients	Percentage
Frontal	22	23.4
Parietal	21	22.34
Temporal	26	27.66
Occipital	16	17.02
Posterior fossa	9	9.58
Total	94	100

Table 3: Location of extradural hematomas

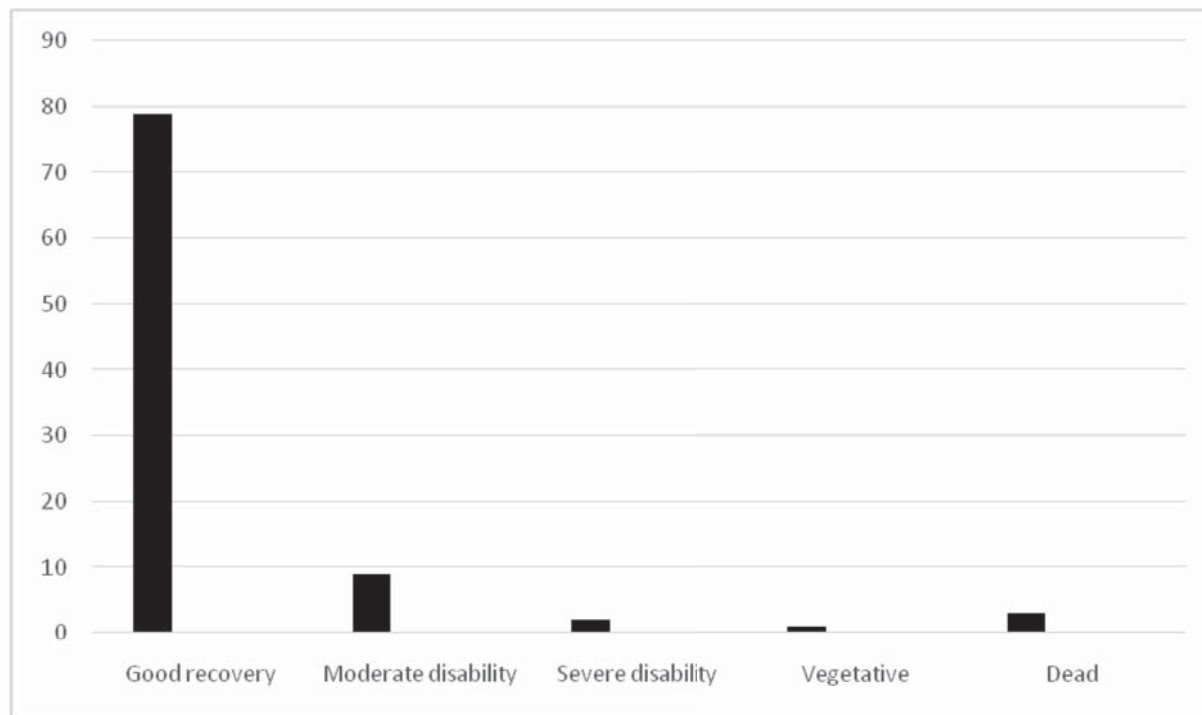


Figure 1: Glasgow Outcome scale at 1 month

Majority of patients with extradural hematomas had coma score of 13-15. Thirty two patients (34.04%) had moderate head injury and 9 patients had severe head injury with coma score of \leq 8 as shown in Table 4.

GCS	Number of patients	Percentage
13-15	53	56.38
9-12	32	34.04
3-8	9	9.58
Total	94	100

Table 4: Glasgow coma scale at admission

Glasgow outcome scale for the operated patients is shown in Figure 1. More than 90% of patients who had evacuation of hematoma had favorable outcome, good recovery (84.05%) or moderate disability (9.57%). Six patients (6.38%) had unfavorable outcome, severe disability in 2 patients (2.13%), persistent vegetative state in 1 patient (1.06%) and mortality in 3 patients (3.19%).

In the subgroup analysis, all patients who presented with GCS of 13-15 had good recovery. With moderate head injury, one patient had severe disability and one patient expired. Among patients with severe head injury, one patient had severe disability, one patient had persistent vegetative state and two patients expired.

Discussion

Extradural hematomas result when there is injury to meningeal arteries, veins or dural sinuses due to a fracture of skull bone. Laceration of the middle meningeal artery is the most common etiology. When extradural hematoma enlarges it causes intracranial hypertension and shift of brain. Extradural hematoma (EDH) is a major traumatic brain injury and a potentially life-threatening condition. However not all patients with extradural hematomas need surgery. In study done by Irie F et al., the most frequent cause of injury was a fall in the 0 year to 9 years age groups and road traffic crash in those aged 10 years to 24 years.⁵ Almost 81% of the EDH cases were due to accidental injury and 17% due to assault. In our study, motor vehicle accident was the cause of extradural hematomas in 52% and falls in 34%.

Findings in study done by RehmanL et al. in Pakistan was similar to our study.¹⁰ In this study motor vehicle accidents, falls and assaults caused extradural hematomas in 50%, 33% and 17% of patients respectively. Patients who have small extradural hematomas can be managed conservatively but some may subsequently deteriorate. In study done by Basamh M et al, only about 11.2% of patients initially triaged for conservative treatment required surgery.¹ Surgical treatment is indicated for patients with large extradural hematomas more than 30 mls, midline shift more than 5mm or with reduced level of consciousness.³

Operation for evacuation of extradural hematomas were performed on 40-62% of patients.^{5,11} Operation rate for extradural hematoma in our study was 55.62%. Prognosis following evacuation of hematoma depends on several factors. GCS is the single most important predictor of outcome.⁴ Gender, time from injury to management, location of hematoma had no significance impact on the outcome. However, Jeong YH showed that older age, higher degree of brain injury, surgical cases of extradural hematomas, decreasing pattern of coma scale between initial and final coma scale were prognostic factors in patients with extradural hematomas.⁷ Majority of patients with extradural hematomas have favorable outcome following surgery. At one month follow up almost 90% of patients had favorable outcome, 84.05% had good recovery and 9.57% had moderate disability. In a study done by Niaz A et al in Pakistan, good outcome was present in 80.9% of operated extradural hematomas and poor outcome was present in 19.1% of patients.⁹ Three patients were dead at one month's follow up. Mortality in our study was similar to study done by Irie Fumiko. In-hospital mortality and complication rate were determined to be 3.5% and 2.9%, respectively in another study carried out by Bir SC.² In a similar study done by Roka et al in Nepal, among consecutive 68 cases of posttraumatic extradural hematomas, favorable outcome was achieved in 87% of patients and the remaining 13% had unfavorable outcome.¹¹

Conclusion

Extradural hematomas are important traumatic extraaxial hematomas. Extradural hematomas were most commonly due to motor vehicle accidents. Frontal, temporal and parietal locations were commonest locations for such hematomas. Majority of such patients have favorable outcome.

References

1. Basamh M, Robert A, Lamoureux J, Saluja RS, Marcoux J. Epidural hematoma treated conservatively: when to expect the worst. **Can J Neurol Sci** 43:74-81,2016
2. Bir SC, Maiti TK, Ambekar S, Nanda A. Incidence, hospital costs and in-hospital mortality rates of epidural hematoma in the United States. **Clin Neurol Neurosurg** 138:99-103, 2015.
3. Bullock MR, Chesnut R, Ghajar J, Gordon D, Hartl R, Newell DW et al. Surgical management of acute subdural hematomas. **Neurosurgery Suppl** 58:S2-16, 2006
4. Dubey A, Pillai SV, Kolluri SV. Does volume of extradural hematoma influence management strategy and outcome? **Neurol India** 52:443, 2004
5. Irie F, Le Brocque R, Kenardy J, Bellamy N, Tetsworth K, Pollard C. Epidemiology of traumatic epidural hematoma in young age. **J Trauma Acute Care Surg** 71:847-53, 2011
6. Jennett B, Bond M. Assessment of outcome after severe brain damage: a practical scale. **The Lancet** 305:480-4, 1975
7. Jeong YH, Oh JW, Cho S, Korean Trauma Data Bank System Committee. Clinical Outcome of Acute Epidural Hematoma in Korea: Preliminary Report of 285 Cases Registered in the Korean Trauma Data Bank System. **Korean J Neurotrauma** 12:47-54, 2016
8. Maugeri R, Anderson DG, Graziano F, Meccio F, Visocchi M, Iacopino DG. Conservative vs. surgical management of post-traumatic epidural hematoma: a case and review of literature. **Am J Case Rep** 16:811, 2015
9. Niaz A, Nasir MH, Niraula K, Majeed S, Neupane J, Ghimire M, Vohra AH. Factors Affecting the Surgical Outcome in Extradural Hematoma in Punjab Institute of Neurosciences, Lahore, Pakistan. **Nepal Journal of Neuroscience** 14:13-8, 2017
10. Rehman L, Khattak A, Naseer A. Outcome of acute traumatic extradural hematoma. **J Coll Physicians Surg Pak** 18:759-62, 2008
11. Roka Y, Shah A. Post Traumatic Epidural Hematoma: Outcome Analysis in 68 Consecutive Unselected Cases. **Nepal Journal of Neuroscience** 7:6-9,2010
12. Teasdale G, Jennett B. Assessment of coma and impaired consciousness: a practical scale. **The Lancet** 304:81-4, 1974