

## Case Reports

### Manoj Bohara MD, PhD

Department of Neuroendovascular Therapy, Juntendo University Faculty of Medicine, Tokyo, Japan  
Department of Neurosurgery, Juntendo University Faculty of Medicine, Tokyo, Japan

### Kosuke Teranishi MD, PhD

Department of Neurosurgery, Juntendo University Faculty of Medicine, Tokyo, Japan

### Kenji Yatomi MD, PhD

Department of Neurosurgery, Juntendo University Faculty of Medicine, Tokyo, Japan

### Takashi Fujii MD

Department of Neuroendovascular Therapy, Juntendo University Faculty of Medicine, Tokyo, Japan  
Department of Neurosurgery, Juntendo University Faculty of Medicine, Tokyo, Japan

### Takayuki Kitamura MD

Department of Neurosurgery, Juntendo University Faculty of Medicine, Tokyo, Japan

### Munetaka Yamamoto MD, PhD

Department of Neurosurgery, Juntendo University Faculty of Medicine, Tokyo, Japan

### Hidenori Oishi MD, PhD

Department of Neuroendovascular Therapy, Juntendo University Faculty of Medicine, Tokyo, Japan  
Department of Neurosurgery, Juntendo University Faculty of Medicine, Tokyo, Japan

### Address for correspondence:

Manoj Bohara MD, PhD  
Department of Neuroendovascular Therapy and  
Department of Neurosurgery,  
Juntendo University Faculty of Medicine, Tokyo, Japan  
E-mail: boharamanoj111@gmail.com

**Date submitted:** 16/7/2018

**Date accepted:** 17/8/2018

**A**dural arteriovenous fistula (DAVF) is an aberrant connection between dural arteries and dural venous sinuses, meningeal veins or cortical veins. The DAVFs of posterior fossa usually involve transverse or sigmoid sinus.<sup>4</sup> An anterior condylar confluence (ACC) DAVF is a rare entity comprising approximately 3.6% of all DAVFs.<sup>4</sup> However, this lesion has been reported under various names in the past (e.g., DAVF involving the

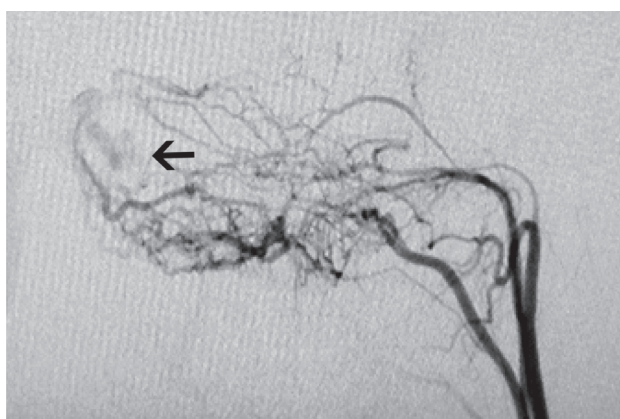
## Transvenous Coil Embolization for Dural Arteriovenous Fistula of the Anterior Condylar Confluence – a Case Report

Dural arteriovenous fistula (DAVF) of the anterior condylar confluence (ACC) is a rare entity accounting for about 3.6% of all DAVFs. We report on a 63-year-old male patient who presented with pulsatile tinnitus. Angiography revealed a DAVF supplied mainly by neuromeningeal branches of bilateral ascending pharyngeal arteries and draining into the ACC. Transvenous transjugular coil embolization was performed resulting in complete obliteration of the fistula and resolution of the symptoms. Due to the complexity of this venous structure at the skull base, detailed angiographic study is crucial for proper therapeutic planning and management of the patient. We here discuss the clinico-radiological features and various treatment modalities of the ACC DAVF.

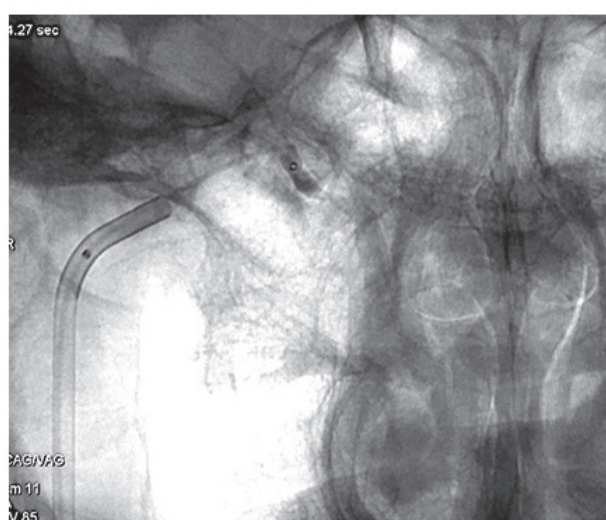
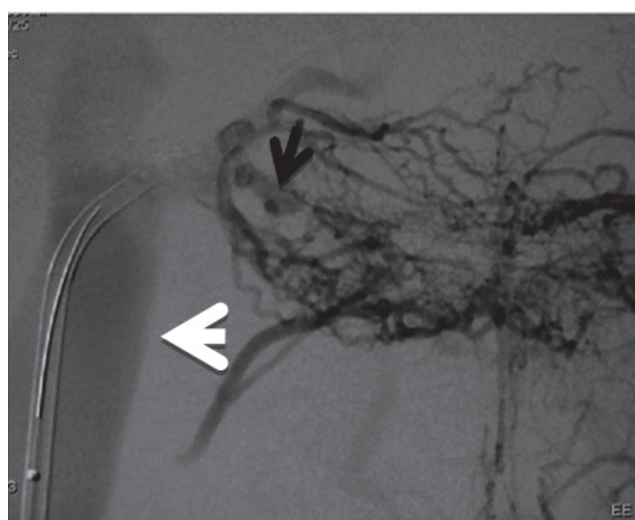
**Keywords:** Dural arteriovenous fistula, anterior condylar confluence, transvenous embolization, hypoglossal canal

hypoglossal canal, DAVF of the anterior condylar vein) or often referred to as DAVFs of inferior petrosal sinus (IPS), marginal sinus (MS), or foramen magnum, due to the complexity of venous structure at the craniocervical junction.<sup>1-3, 5, 7</sup>

Owing to the high-resolution diagnostic tools and the understanding of detailed anatomy of this location, endovascular techniques have been employed to



**Figure 1 :** Selective angiography of left ascending pharyngeal artery showing its neuromeningeal branches (denoted by white arrows) supplying the dural arteriovenous fistula (indicated by black arrow) draining into the anterior condylar confluence.



**Figure 2 : (A and B).** Microcatheter was transvenously inserted via internal jugular vein (indicated by white arrow) to the fistulous point (denoted by black arrow) at anterior condylar confluence.

successfully treat these lesions.<sup>4, 6, 9</sup> We here report on a 63-year-old male patient who presented with pulsatile tinnitus and was diagnosed with DAVF draining into ACC. The patient was successfully treated by transvenous embolization (TVE).

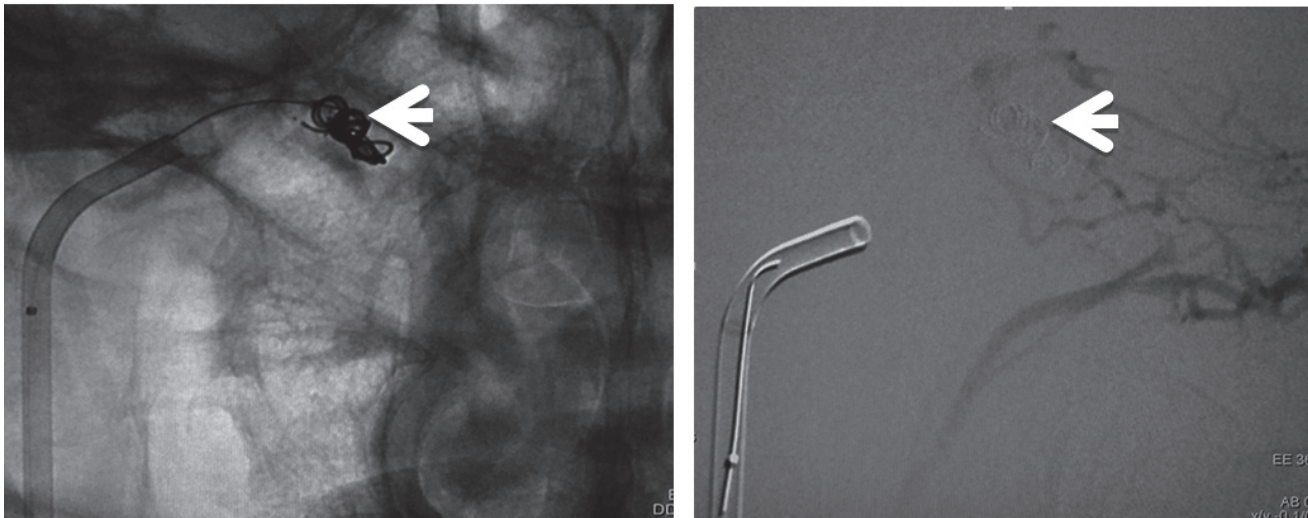
### Case Report

A 63-year-old man presented with right-sided pulsatile tinnitus for 4 months. He had no significant past medical history except abnormal lipid profile. An audible bruit was present behind the right ear. There were no other abnormalities on clinical examination. MR (magnetic resonance) angiography showed a DAVF supplied mainly by the bilateral ascending pharyngeal arteries (APA, branch of external carotid artery). Digital Subtraction Angiography

(DSA) disclosed a DAVF supplied predominantly by the neuromeningeal branches of the right and left APA, the right occipital artery, and the meningeal branches of right vertebral artery, and venous drainage into anterior condylar vein (ACV), posterior condylar vein (PCV) and internal jugular vein (IJV) (**Figures 1 and 2A**). TVE using coils was planned.

Under general anesthesia, TVE was performed via the right femoral vein; continuous irrigation with heparinized saline (3000 U heparin per 1000 ml saline) was performed. Through a 6F Envoy XB MPC guiding catheter (Cordis, Miami Lakes, FL, USA) in combination with Medikit 4F JB3 (Medikit, Tokyo, Japan) inner catheter positioned into the right internal jugular vein as close as possible to the shunt, Excelsior 1018 Pre-shaped 45 microcatheter

(Stryker, Fremont, CA, USA) was advanced over a 0.012-inch GT guidewire (Terumo, Tokyo, Japan) into the fistulous pouch (**Figure 2B**). Embolization was performed through the microcatheter using fibered platinum coils (GDC Vortex; Stryker, Fremont, CA, USA) (**Figure 3A**), while care was taken not to pack the hypoglossal canal too tightly to prevent CN XII palsy. Angiography performed immediately after the procedure revealed complete obliteration of the fistula (**Figure 3B**). Post-procedure Cone-beam CT (computed tomographic) image demonstrated coils adjacent to the hypoglossal canal (**Figure 4**). A loading dose of intravenous heparin (3000 U) was administered after introducing the guiding catheter and the activated clotting time (ACT) was maintained between 250 and 300 s throughout the



**Figure 3 : (A and B).** Selective angiography of left ascending pharyngeal artery immediately after coil embolization showing complete obliteration of the fistula (coils indicated by white arrow).

procedure. After the procedure, reversal was performed with protamine sulphate. Neurophysiological monitoring was not performed during the procedure. The patient's tinnitus resolved after embolization of the ACC DAVF and he had no postoperative neurological deficit.

### Discussion

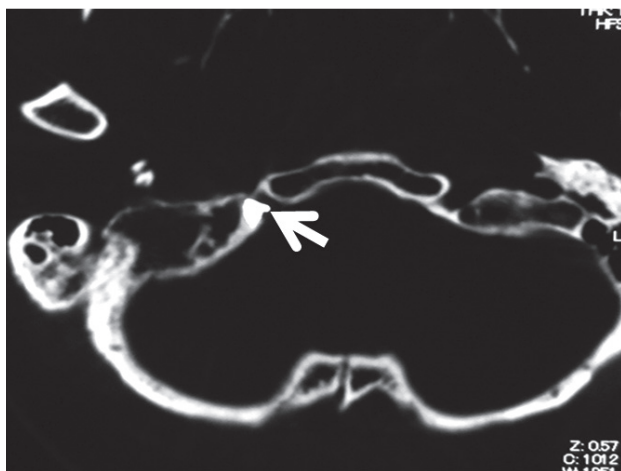
The ACC is an extracranial venous structure located just anterolateral to the hypoglossal canal and merges with the surrounding venous pathways. The term ACC was coined by San Millan Ruiz et al in 2002.<sup>8</sup> The arterial feeders supplying the ACC DAVF include mainly the neuromeningeal trunk of the ascending pharyngeal artery (APA), a branch of the external carotid system. Other arteries include the mastoid branches of the occipital artery, the petrosal branches of the middle meningeal artery, posterior auricular artery, posterior meningeal branch of the vertebral artery and the contralateral APA.<sup>6</sup> Various venous connections to the ACC have been shown: the MS and anterior internal vertebral venous plexus via the anterior condylar vein (ACV), the jugular vein or the suboccipital cavernous sinus via the lateral condylar vein (LCV), the inferior petro-occipital vein, and the cavernous sinus. Several emissary veins often connect the ACC with the junction between the IPS and the jugular bulb.<sup>8</sup> Thus, the anatomical knowledge of this complex venous structure at the skull base is important for understanding the symptomatology as well as the proper therapeutic planning.

Clinical features correlate with the pattern of the venous drainage. In most of the cases where DAVFs drain into the internal jugular vein, patients present with pulse-synchronous bruit or pulsatile tinnitus. If there is retrograde

flow in the IPS, ocular symptoms similar to carotid-cavernous fistula like chemosis, proptosis and diplopia are predominant. Cervical myelopathy can be a presentation due to venous hypertension in the anterior spinal vein. Patients have features of hypoglossal nerve palsy when DAVF drain into the ACV because hypoglossal canal serves as passage for both the ACV and the hypoglossal nerve.<sup>2,4,6,9</sup> Intracranial hemorrhage is more seen in Type 3 (pial or perimedullary) venous drainage than Type 1 (anterograde) and 2 (retrograde orbital).<sup>9</sup>

Detailed radiological assessment is very critical for appropriate planning of treatment. Contrast-enhanced MR scan is useful for depicting the venous structures at the craniocervical junction. T2-weighted axial images demonstrate flow-void sign around hypoglossal canal. In longstanding cases, CT scan may show enlargement of hypoglossal canal. Conventional DSA coupled with 3D rotational angiography remains the gold standard for identifying the fistulous point, feeders and drainers.<sup>7,9</sup> In cases with overlapping vessels and difficulty in delineating the fistulous point, contralateral carotid injection (as in our case) or superselective microcatheter injection can be useful to precisely locate the fistulous point.<sup>2,3</sup>

TVE seems to be an effective treatment for most of the ACC DAVFs, the most direct route being transjugular vein access. In the cases where this access is difficult because of tortuous, stenosed or hypoplastic vessels, access via other routes can be achieved. Spittauet *al* in their systematic review showed that TVE resulted in the highest rate of clinical care (91%) with a relatively low therapeutic risk (permanent morbidity 2.9%).<sup>9</sup> Possible complication of hypoglossal nerve palsy caused by mass effect from the coils in the ACV should be kept in mind. This



**Figure 4 :** Cone-beam computed tomographic image just after embolization showing the coil mass positioned in the anterior condylar confluence (white arrow) adjacent to the hypoglossal canal.

complication can be prevented by avoiding tight-packing of coils and using soft coils.<sup>4,5,6</sup> In the cases where TVE is not possible, transarterial embolization (TAE) using liquid embolic material can also be performed. TAE is generally considered less effective and carries a significant risk of lower cranial nerve palsies (IX–XII), as ACC DAVFs are commonly supplied by neuromeningeal division of APA, which also supplies the vasa nervorum of cranial nerves IX–XII. Moreover, the occasional anastomosis between APA and ICA and/or VA may predispose the patients to the risk of stroke after TAE.<sup>4</sup> Takemoto *et al* reported 3 cases of ACC DAVFs treated by TVE using liquid embolic material Onyx (Covidien, Irvine, CA, USA) with or without coils.<sup>10</sup> Complete obliteration was achieved in all the cases with only transient mild hypoglossal nerve palsy in one case.

If endovascular treatment alone cannot obliterate the fistula, direct surgical obliteration or stereotactic radiosurgery may be indicated. In a systematic review of 120 hypoglossal canal (HC) DAVFs, 15 underwent surgery with or without endovascular treatment.<sup>9</sup> Two patients (13.3%) had permanent morbidity after surgery. Spontaneous occlusion of HCDAVFs was observed in 5.8% of cases. This may suggest that a conservative strategy of “wait and watch” with regular angiographic follow-up can be adopted for type 1 ACC DAVFs depending on the patient age, symptoms or other factors. However, careful follow-up is warranted to evaluate any neurological deterioration and ascertain that the DAVFs do not progress to type 2 or 3.

## Conclusion

DAVFs involving the ACC are rare lesions of the skull base and may cause symptoms depending on the pattern of venous drainage. We here presented a patient with pulsatile tinnitus and diagnosed with DAVF involving the ACC, who underwent successful TVE. Detailed assessment of the location and pattern of venous drainage with selective TVE seems to be safe and effective treatment for such lesions.

## References

1. Barnwell SL, Halbach VV, Dowd CF, et al. Dural arteriovenous fistulas involving the inferior petrosal sinus: angiographic findings in six patients. *AJNR Am J Neuroradiol* **11**: 511–516, 1990
2. Ernst R, Bulas R, Tomsick T, et al. Three cases of dural arteriovenous fistula of the anterior condylar vein within the hypoglossal canal. *AJNR Am J Neuroradiol* **20**: 2016–2020, 1999
3. Kiyosue H, Tanoue S, Okahara M, et al. Ocular symptoms associated with a dural arteriovenous fistula involving the hypoglossal canal: selective transvenous coil embolization. Case report. *J Neurosurg* **94**: 630–632, 2001
4. Manabe S, Satoh K, Matsubara S, et al. Characteristics, diagnosis and treatment of hypoglossal canal dural arteriovenous fistula: report of nine cases. *Neuroradiology* **50**: 715–721, 2008
5. McDougall CG, Halbach VV, Dowd CF, et al. Dural arteriovenous fistulas of the marginal sinus. *AJNR Am J Neuroradiol* **18**: 1565–1572, 1997
6. Miyachi S, Ohshima T, Izumi T, et al. Dural arteriovenous fistula at the anterior condylar confluence. *Interv Neuroradiol* **14**: 303–311, 2008
7. Okahara M, Kiyosue H, Tanoue S, et al. Selective transvenous embolization of dural arteriovenous fistulas involving the hypoglossal canal. *Interv Neuroradiol* **13**: 59–66, 2007
8. San Millan Ruiz D, Gailloud P, Rufenacht DA, et al. The craniocervical venous system in relation to cerebral venous drainage. *AJNR Am J Neuroradiol* **23**: 1500–1508, 2002
9. Spittau B, Millán DS, El-Sherif S, et al. Dural arteriovenous fistulas of the hypoglossal canal: systematic review on imaging anatomy, clinical findings, and endovascular management. *J Neurosurg* **122**: 883–903, 2015
10. Takemoto K, Tateshima S, Rastogi S, et al. Onyx embolization of anterior condylar confluence dural arteriovenous fistula. *J Neurointerv Surg* **6**: e13, 2013