

Case Report

Bivek Pokhrel, MBBS

Department of Neurosurgery
Annapurna Neurological Institute and Allied Sciences
Maitighar, Kathmandu, Nepal

Pranaya Shrestha, MS

Department of Neurosurgery
Annapurna Neurological Institute and Allied Sciences
Maitighar, Kathmandu, Nepal

Pravesh Rajbhandari, MS

Department of Neurosurgery
Annapurna Neurological Institute and Allied Sciences
Maitighar, Kathmandu

Avinash Chandra, MD

Department of Neurology
Annapurna Neurological Institute and Allied Sciences
Maitighar, Kathmandu

Basant Pant, PhD

Chief of Neurosurgery
Annapurna Neurological Institute and Allied Sciences
Maitighar, Kathmandu

Address for Correspondence:

Bivek Pokhrel, MBBS
Department of Neurosurgery
Annapurna Neurological Institute and Allied Sciences
Maitighar, Kathmandu, Nepal
Email: drbivek@gmail.com

Received, 17 June, 2017

Accepted, 27 June, 2017

Trauma and scarring have been known to be predisposing factors for the development of meningiomas.² There are studies to show a statistically significant correlation between the development of meningiomas and a history of head trauma.^{21,22}

The relationship between trauma and development of astrocytoma is however not as well established. Although there have been a few case reports of the relationship between trauma and development of gliomas, in none of the cases reported was there documented evidence of the absence of a neoplasm at the time of injury. We present a patient in whom a malignant glioma developed 4 months after traumatic contusion of left temporo parietal region, with no tumor seen on CT performed Following Trauma.

Case Report

A 46-year-old male presented to our hospital with a history of abnormal body movement 2 month prior to the

Post-Traumatic Glioma: Report of A Case

Development of malignant glioma after trauma is a rare occurrence. Trauma and scarring have been known to be the predisposing factor for the development of meningiomas. Many people have discussed about the development of glioma post trauma but without proper evidence of documents prior to trauma with no evidence of tumor. We present you a case with evidence of not having tumor during trauma.

Key Words: head trauma, malignancy, post-traumatic glioma

admission in our hospital, which was generalized and was associated with frothing from mouth, upward rolling of eyes, tongue bite. The duration of first seizure was around 10 minutes and post-ictal deficit was about 1 hour. He also had a period of confusion, dementia and hallucination for few minutes. He was under Phenytoin Sodium 300mg once a day after consultation in Local Hospital. He had a past history of fall injury from motorbike 4 months back for which he was treated in other hospital conservatively.

CT head was done at that time which reveals small contusion over left parietal region.

His seizure was well controlled on Phenytoin but 10 days prior to the admission he had short-term memory loss, decrease hearing in bilateral ear, decrease appetite and bitemporal headache.

We did the CT Scan Head, which revealed Heterogeneous lesion in Left Temporo-Parietal region with Perilesional edema (**Figure 1, 2**). Then he was admitted and Magnetic Resonance Imaging (MRI) was

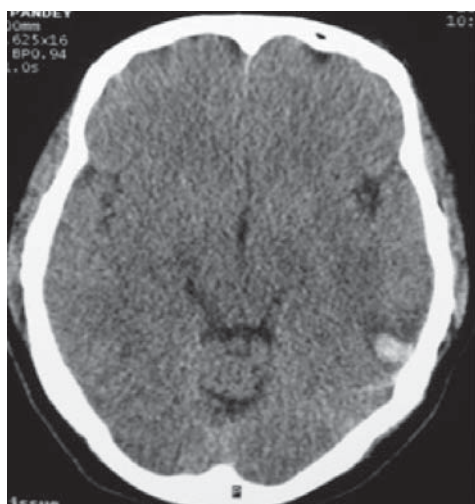

Figure 1: CT Scan Head after trauma showing left parieto-temporal contusion.

Performed which revealed approximately 4x4x3 cm size moderate heterogeneous peripheral enhancing mass with non-enhancing central necrotic area noted in left Temporo-parieto-frontal lobes with moderate Perilesional edema (Figure 3). The tumor was at the same location as the original site of injury. Histopathological report revealed Glioblastoma Multiformi (Figure 4).

Discussion

Epidemiological studies are largely equivocal on the link between traumatic brain injury and subsequent formation of glioma.²³ However, the presented case show formation of GBM at the site of prior brain injury.^{2,3,6,7,9-15,18} Trauma and glial scarring are known to be predisposing factors for the development of malignant glial tumors.²⁵ The development of glioblastoma multiforme following a traumatic cerebral contusion is possible.¹⁸ There are several case reports in the literature that discuss posttraumatic gliomas.^{2,3,6,9-16} but some of these cases might only be a statistical coincidence. Our hypothesis is that, in some patients an underlying biological vulnerability predisposes then to gliomagenesis after brain trauma. What is the mechanism that could potentially explain injury driven gliomagenesis?

We propose that the inflammatory response that ensues after traumatic brain injury is linked to oncogenic transformation of neural stem and progenitor cells that chemotactically migrate to the injured site in response to inflammation, and cancer has been firmly established in other organ system.⁵ It is therefore plausible that similar processes may underlie injury driven gliomagenesis in the brain. Hochberg et al.¹⁴ demonstrated that severe head injury is a significant risk factor for the development of glial tumors. Most other authors have not demonstrated

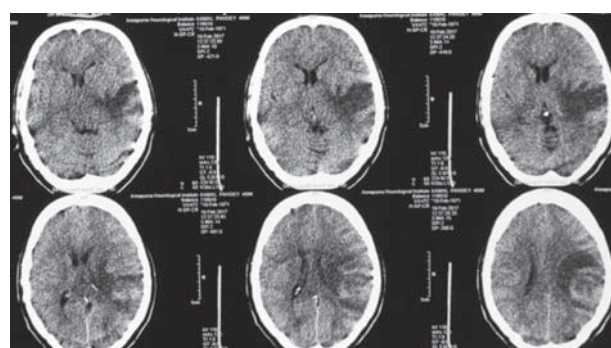


Figure 2: CT scan head showing edematous area in the left Parieto-temporal region.

a significant association between head trauma and gliomas.^{3,19,27} In most of these cases, the histopathological diagnosis was a continuation of the gliotic scar of the tumor^{3,6,7,8,10,17,21} and persisting splinters were found in the glioma nidus many years after penetrating injury.²⁴ Posttraumatic gliomas have been described, but in none of these prior reports has there been documented absence of a tumor at the time of the injury. A posttraumatic malignant glioma with radiological evidence of only a contusion prior to the development of the tumor was reported by Henry et al.¹¹

Ludwin demonstrated evidence of mitoses among astrocytes, microglia and oligodendrocytes 24 hours after trauma in mice. Trauma initiates glial cell proliferation by triggering various growth factors that result in malignant neoplasms.¹⁹ Schiffer et al.²⁵ detected astrocytic proliferation on the ipsilateral injury side in the rat brain two days after trauma, and astrocytic proliferation was demonstrated in regions of fluid percussion injury and deteriorated blood-brain barrier regions.¹³ Kernie et al.¹⁶ demonstrated significant astrocyte and neural precursor proliferation in response to traumatic brain injury regions at 60 days after trauma, and Propiono bacterium acnes was isolated within the posttraumatic glioma tissue.²⁴ Glioblastoma multiformes has also reported at the site of metal splinter injury²⁴ and gunshot injuries complicated with infectious processes may be responsible for the development of posttraumatic GBM after many years.²⁶ Glioblastoma multiformes may also develop after neurosurgical operations due to the collection of myelin basic protein in the brain.¹ Manuelidis¹⁷ has stated that bleeding, edema and scars should be distinguished from traumatic injury. A contrast CT/MR done soon after resolution of the traumatic contusion should not reveal a mass lesion. Otherwise, the possibility of a pre-existing tumor rather than a trauma-induced tumor is very high. A glioma diagnosis should also be confirmed by immunohistochemical tests, such as GFAB, KI-67, P53, S-100 and vimentin positivity.⁴

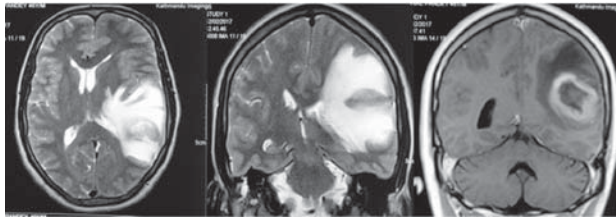


Figure 3: MRI Brain showing Lesion with Perilesional Edema

Conclusion

In conclusion, large-scale epidemiological studies have not shown a definitive link between traumatic brain injury and increased risk of developing GBM. However, the patient presented with GBM at the site of the brain injury 4 months later. It is, therefore, possible that an underlying biological vulnerability in a subset of patients with traumatic brain injury may predispose them to gliomagenesis. We propose a putative model that links neuro-inflammation to mutagenesis in neural stem and progenitor cells migrating to the site of injury, leading to their neoplastic transformation and glioma initiation. It can be the chance factor that we found the glioma post trauma, but we have strong evidence that points towards the development of glioma after the trauma and there was no any findings in the CT head during the time of trauma which was suggestive of any space occupying lesion in the brain, but we did the biopsy of the tumor which we found 4 months after trauma and which we had excised and found to be Glioblastoma Multiformes which cannot be a coincidence.

References

1. Alling C, Karlsson B, Vällfors B. Increase in myelin basic protein in CSF after brain surgery. **J Neurol** **223**: 225-230, 1980
2. Annegers JF, Laws ER, Kurland LT, Grabow JD. Head trauma and subsequent brain tumors. **Neurosurgery** **4**:203-206, 1979
3. Bohnen NI, Kurland LT. Epidemiology of brain tumors. In Vecht CJ, Vinken PJ, Bruyn GW, eds. *Neuro- Glioblastoma Multiforme Following Cerebral Contusion Surg Neurol* **61**: 180-2, 2004
4. Candolfi M, Curtin JF, Nichols WS, Muhammad AG, King GD, Pluhar GE, et al. Intracranial glioblastoma models in preclinical neuro-oncology: Neuropathological characterization and tumor progression. **J Neurooncol** **85**: 133-148, 2007
5. Coussens LM, Werb Z. Inflammation and Cancer. **Nature** **420**: 860-867, 2002
6. Di Trapani G, Carnevale A, Scerrati M, Colosino C, Vaccario ML, Mei D. Post traumatic malignant glioma. Report of a case. **Ital J Neurol Sci** **17**:283-286, 1996
7. Diezel P. Gliom nach trauma. **Frankfurt Z Path** **60**:316-326, 1949
8. Finkemeyer H, Behrend RC. Hirntrauma and gliomentstehung. **Zentralbl Neurochir** **16**:318-320, 1956
9. Hallervorden J. Oligodendroglion nach hirntrauma. **Nervenarzt** **19**:163-167, 1948
10. Henderson RD, Campbell SF. Head trauma and brain tumors revisited. **J Clin Neurosci** **7**:262-264, 2000
11. Henry PT, Rajshekhar V. Post-traumatic malignant glioma: case report and review of literature. **Br J Neurosurg** **14**:64-67, 2000
12. Heyck H. Glioblastom nach leukotomie. **Monatschr Psychiat Neurol** **128**:180-188, 1954
13. Hill-Felberg SJ, McIntosh TK, Oliver DL, Raghupathi R, Barbarese E. Concurrent loss and proliferation of astrocytes following lateral fluid percussion brain injury in the adult rat. **J Neurosci Res** **57**: 271-279, 1999
14. Hochberg F, Toniolo P, Cole P. Head trauma and seizures as risk factors of glioblastoma. **Neurology** **34**:1511-1514, 1984
15. Janda J, Mracek Z. Post traumatic astrocytoma. **Zentralbl Allg Pathol** **133**:55-59, 1987
16. Kernie SG, Erwin TM, Parada LF. Brain remodeling due to neuronal and astrocytic proliferation after controlled cortical injury in mice. **J Neurosci Res** **66**: 317-326, 2001
17. Manuelidis EE. Glioma in trauma. In: Minckler J, ed. *Pathology of the Nervous System*, McGraw-Hill Vol 2: 2237-2240, 1978
18. Messimy R, Pecker J. Posttraumatic glioma; difficulties of the problem. **Rev Neurol** **89**:620-621, 1953
19. Nygren C, Adami J, Ye W. Primary brain tumours following traumatic brain injury: a population based

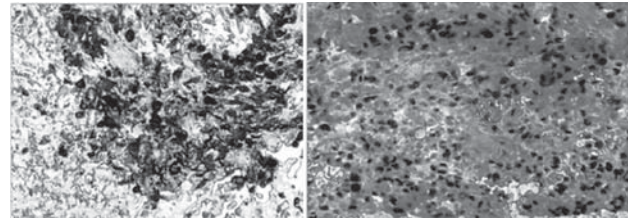


Figure 4: Histological picture showing high-grade glioma, glioblastoma multiformes. Many of neoplastic cells show Immunoreactivity of GFAP and Immunoreactivity to S-100

- cohort study in Sweden. **Cancer Causes Control** **12**:733-737, 2001
20. Perez-Diaz C, Cabello A, Lobato RD, Rivas JJ, Cabrera A. Oligodendrogliomas arising in the scar of a brain contusion. **Surg Neurol** **24**:581-586, 1985
 21. Preston-Martin S, Paganini-Hill A, Pike MC, Wood C. Case control study of intracranial meningiomas in women in Los Angeles county California. **J Natl Cancer Inst** **65**:67, 1980
 22. Preston-Martin S, Paganini-Hill A, Henderson BE, Roberts C. Risk factors for meningiomas in men in Los Angeles county. **J Natl Cancer Inst** **70**:863, 1983
 23. Preston-Martin S, Pogoda JM, Schlehofer B, et al. An international case-control study of adult glioma and meningioma: the role of head trauma. **Int J Epidemiol** **27**:579-586, 1998
 24. Sabel M, Felsberg J, Messing-Junger M, Neuen-Jacob E, Piek J. Glioblastoma multiforme at the site of metal splinter injury: a coincidence? Case report. **J Neurosurg** **91**:1041-1044, 1999
 25. Schiffer D, Giordana MT, Cvalla P, Vigliani MC, Attanasio A. Immunohistochemistry of glial reaction after injury in the rat: double staining and markers of cell proliferation. **Int J Dev Neurosci** **11**:269-280, 1993
 26. Witzmann A, Jellinger K, Weiss R. Glioblastoma multiforme developing after a gunshot injury of the brain. **Neurochirurgia** **24**:202-206, 1981
 27. Wrench M, Miike R, Lee M, Neuhaus J. Are prior head injuries or diagnostic X-rays associated with glioma in adults? The effects of control selective bias. **Neuroepidemiology** **19**:234-244, 2000