

**Prabin Shrestha, MD, PhD**

Department of Neuroscience  
B&B Hospital  
Gwarko, Lalitpur, Nepal

**Anish M Singh, MS**

Department of Neuroscience  
B&B Hospital  
Gwarko, Lalitpur, Nepal

**Isha Dhungana, MD, PhD**

Department of Neuroscience  
B&B Hospital  
Gwarko, Lalitpur, Nepal

**Address for Correspondence:**

Prabin Shrestha, MD, PhD.....  
Department of Neuroscience  
B&B Hospital  
Gwarko, Lalitpur, Nepal  
**Email:** prabinshrestha@hotmail.com

**Received,** 16 July, 2017

**Accepted,** 24 July, 2017

**D**egenerative disease of spine is one of the most common spinal problems.<sup>9,11,13</sup> In this process there is gradual loss of normal structure and function of spine with time. It is usually caused by age. It is the wear and tear effect on spine with time and age. It is not considered as disease as it is a natural process of degeneration of human body. It is usually not rapidly progressing and occurs due to daily physical stresses. It is aggravated by minor injuries and by other pathologies such as major trauma, tumors, osteoporosis, arthritis etc.

It is also called degenerative disc disease as involvement of intervertebral disc in this process is most apparent. Normal disc tissue is elastic, glue or jelly like, gelatinous, mucoid and not breakable. It is normally well hydrated containing water, about 80% of its weight. Abnormal disc is dehydrated, fibrous, less elastic, calcified and easily breakable in pieces.

Degenerated spine is usually not problematic in majority of cases. However in some cases it can create severe pain and disability.

Degenerative spinal disease mainly includes herniation of intervertebral disc, spinal canal stenosis and spondylolisthesis. These problems cause radiculopathy, myelopathy and/or severe pain.

Here we present the retrospective analytical study of our experience in degenerative spinal disease. The main objective of presenting this study is to share our experience.

## Degenerative Spine Surgery: Our Experience

Degenerative disease is the commonest spinal problem that any neurosurgeon or spinal surgeon encounters in his/her daily practice. Many such cases can be managed conservatively with appropriate investigations, while many others may need surgical intervention. At times it may be difficult to make proper decision for the management or for the appropriate surgical intervention.

Here we present the retrospective analytical study of our experience in degenerative spinal disease. The main objective of presenting this study is to share our experience.

**Key Words:** discectomy, herniation of cervical disc, herniation of lumbar disc, laminectomy

### Materials and Methods

This is a retrospective analytical study of degenerative spinal disease (DSD) and its management in our own experience in last 9 years since 2008 till 2016 AD. The surgical procedure was carried out in NORVIC hospital and BB hospital. The cases included DSD of lumbar spine and cervical spine. Single and multilevel Spinal canal stenosis and herniation of discs were the main pathologies in both lumbar and cervical spine that we dealt with. Infective, neoplastic and traumatic cases of spine were excluded.

Enblock multilevel laminectomy was performed in case of spinal canal stenosis with myelopathy. Similarly lumbar microdiscectomy was done for herniation of lumbar disc (HLD) and anterior cervical discectomy with fusion or fixation (ACDF) was done for herniation of cervical disc (HCD). No instrumentation was done for HLD whereas for HCD instrumentation such as anterior plating and screwing was done in selected cases. Posterior instrumentation was not done for any cervical canal stenosis. Bone cement (Methylmethacrylate) was used in most of the cases of HCD for fixation without any other instrumentation. In selected cases, bone graft or titanium cage along with plates and screw were used.

In case of lumbar discectomy, open surgery was done in all the cases, ie endoscopic surgery was not done in any cases.

### Results

Spinal surgery is one of the major works in our experience occupying more than half of total neurosurgical work. As shown in **Figure 1**, cranial surgery occupies >35% and peripheral nerve surgery occupies <10% of total neurosurgical procedures.

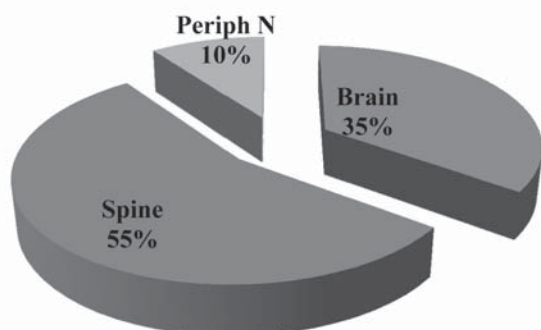


Figure 1: Chart showing proportion of various neurosurgical procedures

Among different spinal surgical procedures, degenerative spine surgery is the most common procedure occupying almost three fourth of total spinal surgery in our experience (**Figure 2**).

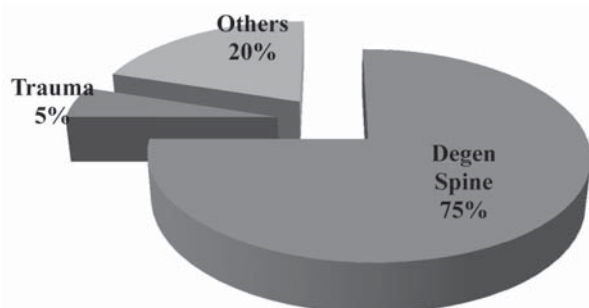


Figure 2: Chart showing proportion of various spinal surgical procedures

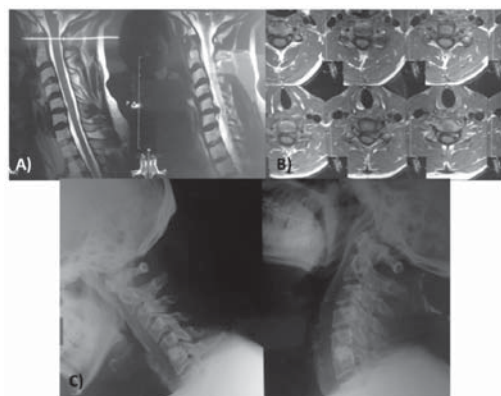


Figure 3: An illustration of HCD C5-6, A) preoperative MRI, B) postoperative MRI, C) postoperative X-ray

All together 849 cases of DSD were managed surgically in the above mentioned period. Among them lumbar cases occupied about 80% (697/849) of cases including 599 cases of lumbar microdiscectomy and 98 cases of lumbar multilevel laminectomy. Similarly, cervical spine cases occupied remaining 20% (153/849) cases including 79(52%) cases of ACDF, 4(3%) cases of posterior cervical discectomy and 70(45%) cases of cervical multilevel laminectomy.

In cervical spine surgery for DSD, age ranged from 30-75 years and sex distribution was almost similar. Similarly in lumbar spine surgery for DSD, age ranged from 14-87 years with almost equal sex distribution with slight male predominance. Recently more and more younger patients were being operated, >80% being <40 years of age probably due to more bike and car riding habits and sitting jobs. Side distribution of the herniation of disc at lumbar and cervical spine was almost equal. Surgical time for cervical spine surgery ranged from 60-100 minutes and that for lumbar spine surgery ranged from 20-75 minutes. More was the number of level of pathology, longer was the surgical time. Hospital stay for all the spinal surgeries for DSD was 3-7 days except for few exceptions.

Commonest level of HCD was C5-6, followed by C6-5 and C4-5. However, there was no significant difference in the number of cases among those 3 different levels. There was only 2 cases of HCD at C3-4. There were no cases of HCD at C2-3 and C7-T1. One case of HCD was a recurrent case which was operated earlier in another center few years back. There was not a single case of recurrence of cases operated by us.

For ACDF, we most of the time use bone cement (Methylmethacralate) for fixation of vertebral bodies (**Figure 3**). Less commonly we use autologous bone graft and titanium cage. Similarly, in majority of cases of HLD, small hemilaminotomy on ipsilateral side was done, but in some laminectomy was done to take out the disc due to some difficulties like giant disc herniation, significantly tough disc due to calcification etc(**Figure 4**).

Regarding Lumbar spine surgery, commonest level of HLD was L4-5 followed by L5-S1. However, there was no significant difference in the number of cases among those 2 different levels. There were very few cases of HLD at L2-3 and L3-4. There was no case of HLD at L1-2. There were 4 cases of recurrence of HLD in our experience. All the cases had re-HLD at the same level of previous surgery, 2 were males and 2 were females. All the case presented after 1-2 years after first surgery. All of them got better after second surgery.

Majority of cases of HLD and HCD were single level. About 10% of HLD and about 5% of cases of HCD had multilevel involvement and surgery was done in multiple levels.

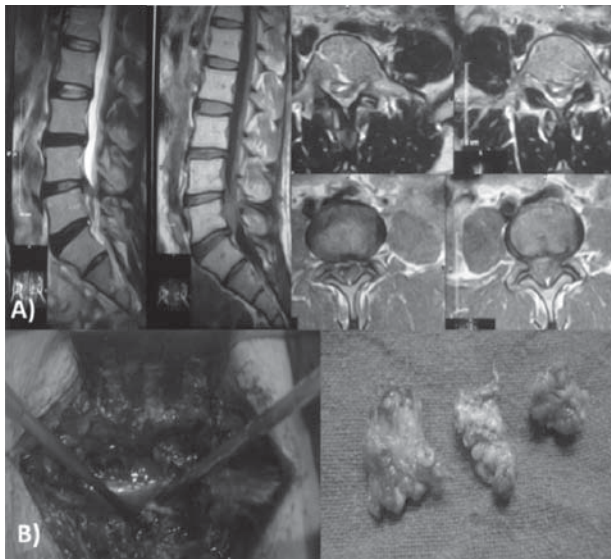


Figure 4: An illustration of HLD, A) preoperative MRI images, B) intraoperative pictures showing laminectomy and huge sequestered disc tissues taken out

Regarding surgical outcome, in case of cervical spine surgery, 77/81 (95%) cases didn't have any surgical complications and went back home safely. All of them improved significantly except few who had severe myelopathy preoperatively remained the same afterwards also. Remaining 4 cases had surgical complications. One developed central cord syndrome after surgery who already had mild quadriplegia preoperatively. Though her central cord syndrome improved to some extent, she remained mildly quadriparetic needing some support to stand and walk. One patient had severe surgical site infection and expulsion of bone cement. She recovered well after few weeks of IV antibiotics without removal of expelled bone cement. Two patients had minor CSF leak during surgery how improved spontaneously without any significant CSF leak.

All the cervical discectomy cases were operated under the microscope. In case of Lumbar discectomy, microscope was used in selected cases including all the cases of re-surgery.

In case of cervical laminectomy, all the patients went home back safely with improved neurological status. One patient expired after several weeks of surgery after going back home due to some medical complications. Few patients with severe myelopathy remained the same even after surgery.

Similarly in case of lumbar spine, 90% cases didn't have any surgical complications and went back home safely. They became completely asymptomatic afterwards except for few who had caudaequina syndrome preoperatively remained the same after surgery. Out of remaining 10%,

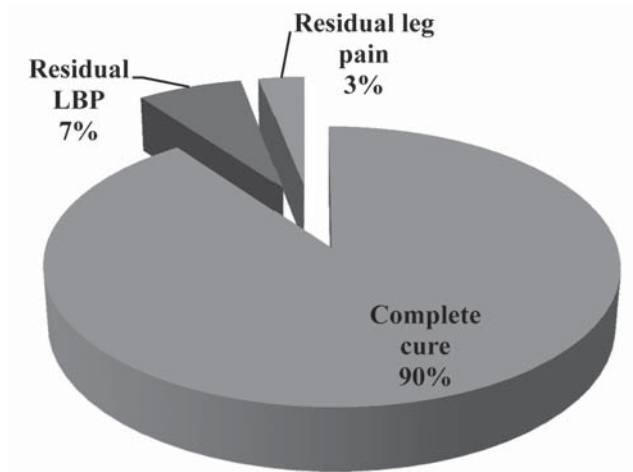


Figure 5: Chart showing outcome of microdiscectomy for HLD

about 6% cases had residual mild back pain at surgical site for few weeks to few months who became better with analgesics (Figure 5). In about remaining <5% cases, significant infection of surgical site was encountered needing readmission of patient and IV antibiotic treatment for few weeks.

Intraoperative dural tear and CSF leak was the main surgical complications that we faced in about 1% of cases. There was not a single case of significant nerve injury leading to post-operative neurological deficit.

In case of cervical laminectomy, all the patients went home back safely with improved neurological status. One female patient expired after few weeks of surgery due to some medical complications.

Hospital stay is variable from case to case after surgery of DSD. However, on an average, patients usually go home after 3-4 days of surgery in both HCD and HLD.

## Discussion

Degenerative spinal disease is age dependent. With time it progresses even though it is not the only and prime contributing factor. Studies have shown the same thing.<sup>13</sup>Our experience also shows that recently more younger patients are having problems of lumbar and cervical disc herniation.

Lordan J et al have conducted a review of literatures about different modalities of treatment of HLD and the outcome.<sup>11</sup> They have studied different modalities. Cervical discectomy without any graft or cage have been done with reasonably good result.<sup>5</sup> We don't have any experience of leaving the disc space as it is without any graft. Our practice is to use bone cement as a graft until and unless otherwise indicated.

ACDF is the standard and established surgical management for herniation of cervical disc.<sup>10,17</sup> There are different ways of ACDF, using bone graft, titanium cage, bone cement etc. Seaman S et al has mentioned that titanium and PEEK cage have similar fusion rate.<sup>2,3,19</sup> However, our experience is more with bone cement (PMMA) fixation of vertebra bodies after cervical discectomy. Chen C et al has clearly shown that there is no stability problem after interbody fusion by PMMA after cervical discectomy.<sup>2</sup> Similarly Chen JF et al have also use PMMA cage but filled with autologous cancellous bone graft which was found to be very effective.<sup>3</sup> However, our technique is different, we don't use any bone graft with PMMA, we directly fill the disc space with semisolid PMMA with thorough irrigation with normal saline solution. Once it is solidified after few minutes the spine is well stabilized. During our almost 8 years follow up there is not a single case of spinal instability due to PMMA except one case of PMMA expulsion from the disc space due to infection. Similarly, some literatures have shown anterior cervical discectomy without fusion is also equally effective.<sup>23</sup> However we don't have any experience of ACDF without fusion or fixation. Wilson DH et al have also showed that ACDF without bone graft have excellent outcome.<sup>22</sup> Dunsker SB also have the same experience.<sup>5</sup> Similarly Martins AN have similar experience and they suggested Cloward procedure ie bone graft fusion for patients symptomatic from advanced spondylosis and discectomy without bone graft insertion for those with minimal spondylosis or soft disc herniations.<sup>16</sup> However, Sunder Plassman M et al suggested fusion or fixation to reduce postoperative kyphosis and thus neck pain.<sup>20</sup>

Different complications have been reported after ACDF. Epidural hematoma after surgery is one of them as mentioned by U HS et al.<sup>21</sup> Fortunately, we haven't encountered such complications yet. Similarly spinal cord injury has been found to be a major complication in one study<sup>12</sup> and thus it was suggested to avoid unnecessary instrumentation. In our experience, not a single case of spinal cord injury has been encountered so far except one who developed central cord syndrome after ACDF who already had quadriplegia and myelopathy. Probably the cause of developing central cord syndrome in that case was intra-operative positioning rather than direct cord injury itself. Instrumentation is much less in our experience. We almost never do any instrumentation in spinal canal stenosis in DSD except in few exceptional cases. We don't have any case of lumbar/cervical discectomy or laminectomy leading to spinal instability.

Dural tear is one of the commonest complications of disc surgery in both HCD and GLD.<sup>4</sup> We have experienced dural tear and CSF leak in about <1 % of cases. We managed all the cases by primary repair and post-operative lumbar drain if needed. None of the cases underwent re-exploration and secondary repair.

Re-herniation of disc leading to need of re-surgery is another possible complication of DSD surgery. We do have such complications. Literatures have mentioned about this complication to be >12%.<sup>8,12</sup> However, in our experience, it is very few. Only 4 cases have been re-operated so far and got much better after second surgery.

Microscope is an essential tool for ACDF which we followed in all of our cases.<sup>7</sup> In case of Lumbar discectomy, microscope was used in selected cases including all the cases of re-surgery.

Physiotherapy is one of the treatment modalities for degenerative spinal problems.<sup>6</sup> For HLD cases we often refer our patients for it before finally we plan for surgery. Surgery is avoided as long as patient is better with conservative treatment and physiotherapy. However we don't encourage patients with HLD or HCD for extensive and aggressive physiotherapy which can, at times, lead to severe neurological complications as mentioned by Yang SD et al.<sup>24</sup> Our protocol of mobilization of patient after surgery is letting the patient walk slowly on the second day and discharge the patient on 3<sup>rd</sup> or 4<sup>th</sup> day of surgery except for few exceptional cases.<sup>6</sup> Light exercise and physiotherapy on bed is what we teach to our patients immediately after surgery, otherwise vigorous physiotherapy is avoided after surgery, it is not required in our experience.

Endoscopic surgery is regarded as minimally invasive spinal surgery these days.<sup>15,18</sup> We don't have any experience of endoscopic lumbar discectomy so far. Open lumbar discectomy we have been performing so far is not that invasive, incision is hardly few cm long and there is no wound healing issues so far. Patients can be discharged within few day of surgery, but in our experience patients tend to stay in hospital at least for few days to have complete rest even if we try to discharge them earlier. That's the reason why we haven't practiced endoscopic lumbar discectomy so far. Rather at times endoscopic procedure can create complications like as suggested by Yorukoglu AG et al.<sup>25</sup> Moreover, mastering endoscopic surgery is another challenge.

After discectomy in HLD or HCD, we never send the tissues for histopathological evaluation until and unless there is some abnormal tissues or signs of infection. Altun

I et al has suggested histological evaluation of disc tissues to see its nature.<sup>1</sup> We have also found calcification in some cases, calcification of ligamentum flavum, calcification of posterior longitudinal ligament and disc tissues etc. Though not that common, calcification of disc and other surrounding tissues makes the surgery difficult and we need to be more careful in such cases to avoid surgical complications.

Degenerative spine surgery as performed by neurosurgeon and orthopedic surgeons are probably not much different in Nepalese context except in few cases.<sup>14</sup> We have noticed more instrumentation by orthopedic surgeons in DSD cases as indicated by patients history before or after surgery. Instrumentation is extremely rare in our experience in usual degenerative spine in cervical and lumbar spine.

### Conclusion

DSD is a common spinal pathology. Appropriate surgery in appropriate time gives very good result. Level of satisfaction in both patients and ourselves is significantly high in our experience. DSD surgery is usually simple without any significant technical difficulties. However, at times it turns out to be much complicated than expected. Prompt management of technical difficulties and surgical complications give excellent result.

### References

1. Altun I, Yüksel KZ. Histopathological Analysis of Ligamentum Flavum in Lumbar Spinal Stenosis and Disc Herniation. *Asian Spine J*11:71-74, 2017
2. Chen C, Zhao W, Sun P, Wu C, Qu D, Ouyang J. Biomechanical study on effect of polymethylmethacrylate augmentation on cervical stability after anterior cervical interbody fusion. *Zhongguo Xiu Fu Chong Jian WaiKe ZaZhi*4: 1174-1179, 2010
3. Chen JF, Wu CT, Lee SC, Lee ST. Use of a polymethylmethacrylate cervical cage in the treatment of single-level cervical disc disease. *J Neurosurg Spine*3:24-28, 2005
4. Chinese Association of Orthopaedic Surgeons; Editorial Board of Evidence-Based Clinical Practice Guidelines for the Treatment of Dural Tears and the Consequent Cerebrospinal Fluid Leak During Spine Surgery, Beijing 100027, China. Evidence-based clinical practice guidelines for the treatment of dural tears and the consequent cerebrospinal fluid leak

during spine surgery. *ZhonghuaWaiKeZaZhi*55:86-89, 2017

5. Dunsker SB. Anterior cervical discectomy with and without fusion. *ClinNeurosurg* 24:516-521, 1977
6. Gilmore S, McClelland JA, Davidson M. Does walking after lumbar spinal surgery predict recovery of function at six months? Protocol for a prospective cohort study. *BMC MusculoskeletDisord*17:472, 2016
7. Hankinson HL, Wilson CB. Use of the operating microscope in anterior cervical discectomy without fusion. *J Neurosurg*43:452-456, 1975
8. Heindel P, Tuchman A, Hsieh PC, Pham MH, D'Oro A, Patel NN, et al. Reoperation Rates After Single-level Lumbar Discectomy. *Spine* 42:496-501, 2017
9. Heliövaara M, Knekt P, Aromaa A. Incidence and risk factors of herniated lumbar intervertebral disc or sciatica leading to hospitalization. *J Chronic Dis*40:251-258, 1987
10. Jacobs B, Krueger EG, Leivy DM. Cervical spondylosis with radiculopathy. Results of anterior discectomy and interbody fusion. *JAMA* 211:2135-2139, 1970
11. Jordan J, Konstantinou K, O'Dowd J. Herniated lumbar disc. *BMJ ClinEvid*. pii: 1118, 2011
12. Kraus DR, Stauffer ES. Spinal cord injury as a complication of elective anterior cervical fusion. *ClinOrthopRelat Res* 112:130-141, 1975
13. Ma D, Liang Y, Wang D, Liu Z, Zhang W, Ma T, et al. Trend of the incidence of lumbar disc herniation: decreasing with aging in the elderly. *ClinInterv Aging* 8:1047-1050, 2013
14. Mabud T, Norden J, Veeravagu A, Swinney C, Cole T, McCutcheon BA, et al. Complications, Readmissions, and Revisions for Spine Procedures Performed by Orthopedic Surgeons Versus Neurosurgeons: A Retrospective, Longitudinal Study. *Clin Spine Surg*. 2016 [Epub ahead of print]
15. Mahesha K. Percutaneous endoscopic lumbar discectomy: Results of first 100 cases. *Indian J Orthop*51:36-42, 2017
16. Martins AN. Anterior cervical discectomy with and without interbody bone graft. *J Neurosurg*44:290-295, 1976

17. McPherson WF. Advantages of anterior cervical discectomy. **J Tenn Med Assoc** **70**:879-880, 1977
18. Regev GJ, Kim CW, Salame K, Behrbalk E, Keynan O, Lador R, et al. A Comparison of Different Minimally Invasive and Open Posterior Spinal Procedures Using Volumetric Measurements of the Surgical Exposures. **Clin Spine Surg**. 2016 [Epub ahead of print]
19. Seaman S, Kerezoudis P, Bydon M, Torner JC, Hitchon PW. Titanium vs. polyetheretherketone (PEEK) interbody fusion: Meta-analysis and review of the literature. **J ClinNeuroscipii**: S0967-5868-(17)30433-2, 2017
20. Sunder-Plassmann M. Anterior cervical intervertebral disk operation without secondary fusion. Clinical and experimental studies. **Fortschr Med** **94**:322-326, 1976
21. U HS, Wilson CB. Postoperative epidural hematoma as a complication of anterior cervical discectomy. Report of three cases. **J Neurosurg** **49**:288-291, 1978
22. Wilson DH, Campbell DD. Anterior cervical discectomy without bone graft. Report of 71 cases. **J Neurosurg** **47**:551-555, 1977
23. Yamamoto I, Kurokawa K, Tew JM, Dunsker SB, Mayfield FH. Anterior cervical discectomy with and without fusion--clinical and experimental study. **No ShinkeiGeka** **6**:781-787, 1978
24. Yang SD, Chen Q, Ding WY. CaudaEquina Syndrome Due to Vigorous Back Massage With Spinal Manipulation in a Patient With Pre-Existing Lumbar Disc Herniation: A Case Report and Literature Review. **Am J Phys Med Rehabil**, 2017 [Epub ahead of print]
25. Yörükoğlu AG, Göker B, Tahta A, Akçakaya MO, Aydoseli A, Sabancı PA et al. Fully endoscopic interlaminar and transforaminal lumbar discectomy: Analysis of 47 complications encountered in a series of 835 patients. **Neurocirugia (Astur)**, 2017 [Epub ahead of print]