

Diagnostic Yield and Immediate Complications of Ultrasound guided Interventional Procedures in Bronchogenic Carcinoma in Multidetector Computed Tomography

Paudel S¹, Bhusal KR², Kayastha P³, Suwal S⁴, Katwal S⁵, Thapa M⁶

¹Associate Professor, ^{3,4}Assistant Professor, Department of Radiology and Imaging, Tribhuvan University Teaching Hospital, Maharajgunj, Kathmandu, Nepal

²Radiologist, Department of Radiology and Imaging, Lumbini Provincial Hospital, Butwal, Rupandehi, Nepal

⁵Radiologist, Department of Radiology and Imaging, National Trauma Center, Kathmandu, Nepal

⁶Associate Professor, Department of Radiology and Imaging, Pokhara Academy of Health Sciences, Western Regional Hospital, Ramghat, Pokhara, Nepal

Received: November 25, 2023

Accepted: January 21, 2024

Published: July 31, 2024

Cite this paper: Paudel S, Bhusal KR, Kayastha P, Suwal S, Katwal S, Thapa M. Diagnostic Yield and Immediate Complications of Ultrasound guided Interventional Procedures in Bronchogenic Carcinoma in Multidetector Computed Tomography. Nepal Journal of Medical Sciences, 2024;9(2):18:65-73. <https://doi.org/10.3126/njms.v9i2.72396>

ABSTRACT

Introduction: Lung cancer is the second most common cancer and most common cause of cancer mortality worldwide. Ultrasound is helpful in evaluation and to perform biopsy from lung mass, enlarged lymph nodes and from accessible metastatic lesion. It also aids to perform thoracocentesis. The purpose of this study was to assess the diagnostic yield of the interventional procedures under sonographic guidance in suspected bronchogenic carcinoma and to look for immediate complications of the procedures.

Methods: A prospective analytical study was conducted in the Department of Radiology and Imaging, Tribhuvan University Teaching Hospital (TUTH) in 46 patients (48 procedures) with Contrast Enhanced Computed Tomography (CECT) diagnosis of bronchogenic carcinoma from June 2022 to August 2023. Ethical clearance was obtained from Institutional Review Committee of Institute of Medicine (Reference No. 56 (6-11) E2 079/80). Ultrasound guided biopsy from lung mass, lymph nodes and metastatic liver lesion was performed. Thoracocentesis was performed in patients with pleural effusion. Immediate complications were recorded. Histopathology/cytology reports were collected and Diagnostic yield was calculated by binary classification.

Results: The overall diagnostic yield was 89.58% (43 out of 48 procedures). The highest yield was obtained from biopsy done from metastatic liver lesion and was 100% (n=1). Diagnostic yield from biopsy of lung mass was 93.93% (n=33) and that from supraclavicular lymph node was 87.50% (n=8). Diagnostic yield from pleural fluid cytology was 66.67% (n=6). Minor complications occurred in 18.75% (n = 9) of patients. Approximately 14.58% (n = 7) patients complained of pain. Only one required injectable pain killer for management. Small pneumothorax occurred in 4.17% (n=2) of cases which resolved with high flow oxygen supply.

Conclusions: In patients with contrast enhanced computed tomography diagnosis of bronchogenic carcinoma, ultrasound guided diagnostic procedures have good efficacy and safety. Ultrasound should be routinely used for the diagnosis of lung cancer when feasible.

Keywords: Bronchogenic carcinoma; Complications; Diagnostic yield.



Corresponding Author: Dr. Prakash Kayastha, Assistant Professor, Department of Radiology and Imaging, Maharajgunj Medical Campus, Tribhuvan University Teaching Hospital, Kathmandu, Nepal. Email: rjkuprakash@gmail.com

INTRODUCTION

Lung cancer is the second most common cancer worldwide and most common cause of cancer death worldwide. [1] Lung cancer is the commonest cancer overall in Nepal with incidence of 16 % and is among the leading cause of cancer related death in Nepal. [2,3]

Patients of lung cancer present with wide range of symptoms which are non-specific and thus the diagnosis relies on imaging and confirmation with biopsy. [4] Peripheral lung mass can be biopsied under CT or Ultrasonographic guidance. Other methods for diagnosis include bronchial/sputum wash, pleural fluid cytology, biopsy from the metastatic lesions. [5]

Ultrasound guided biopsies are safer with no radiation risk, can be performed on bed side, being done at real time. [6] In developing countries like Nepal, late presentation of lung cancer is not uncommon, where presentation can be with metastatic supraclavicular lymph nodes, pleural metastasis and adrenal metastasis which can be sampled under USG guidance. [7] In this study we evaluated diagnostic yield and immediate complications of ultrasound guided procedures in patients with bronchogenic carcinoma.

METHODS

This was a cross-sectional analytical study carried out in the Department of Radiology and Imaging, Tribhuvan University Teaching Hospital, Kathmandu, from June 2022 to August 2023. Ethical clearance was obtained from the Institutional Review Committee (IRC) of the Institute of Medicine (Reference No. 56 (6-11) E2 079/80). Informed written consent was obtained from the subjects before the study. All the suspected cases of bronchogenic

carcinoma in CT imaging and presenting for ultrasound guided tissue sample collection for histological diagnosis in Department of Radiology, TUTH were included. Patients with coagulation abnormality, centrally located lung mass in CT and previously histopathology proven lung carcinoma cases were excluded.

A probability sampling method was used and sample size was calculated as below:

Bronchogenic cancer prevalence rate in Nepal – 16%. [2,3] To calculate the sample size based on the specificity using formula:

Specificity of the USG guided tru-cut biopsy in suspected bronchogenic carcinoma in previous study was 90%. [8] $FP + TN = Z^2 \times \frac{(SP(1-SP))}{d^2}$

$$N (SP) = \frac{FP+TN}{(1-P)}$$

Where, FP = False positive, TN = True negative, SP = specificity, Z = 1.96 for 95 % confidence interval, d = precision (10 %), p = prevalence, N (SP) = Sample size based on specificity, $N (SP) = \frac{FP+TN}{(1-P)}$, $FP + TN = Z^2 \times \frac{(SP(1-SP))}{d^2} = 1.96^2 \times \frac{(0.90(1-0.90))}{0.1^2} = 34.57$. N

$$(SP) = \frac{FP+TN}{(1-P)} = \frac{34.57}{(1-0.16)} = 42$$

Total 46 patients were included in the study.

CT images (Figure 1A and 1B) as well as coagulation parameters, medical history/reports along with well-being of the patient was reviewed. Then patient was evaluated for feasibility of the ultrasound guided procedure. Lesions surrounded by non-aerated lung (Figure 2) and well visualized on ultrasound were selected for biopsy. Similarly, targetable suspicious lymph node with safer access without large vessels in the biopsy path were selected for nodal sampling. Informed written consent was taken after explaining about the diagnostic procedure and its complications.

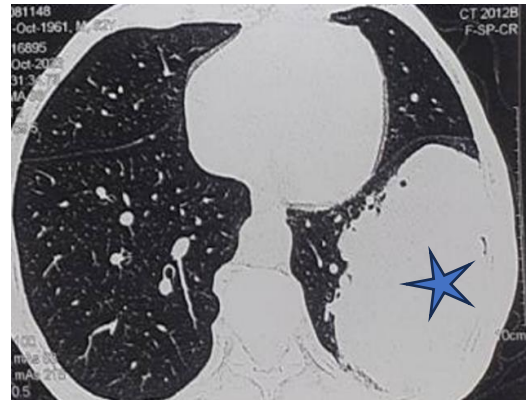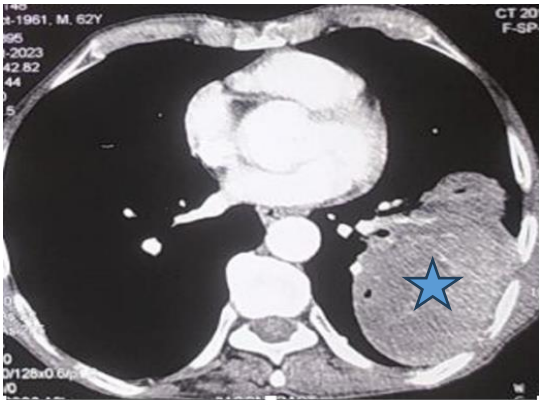


Figure 1A and 1B: Contrast Chest CT in mediastinal (A) and lung window (B) show a large enhancing peripheral lung mass (stars).

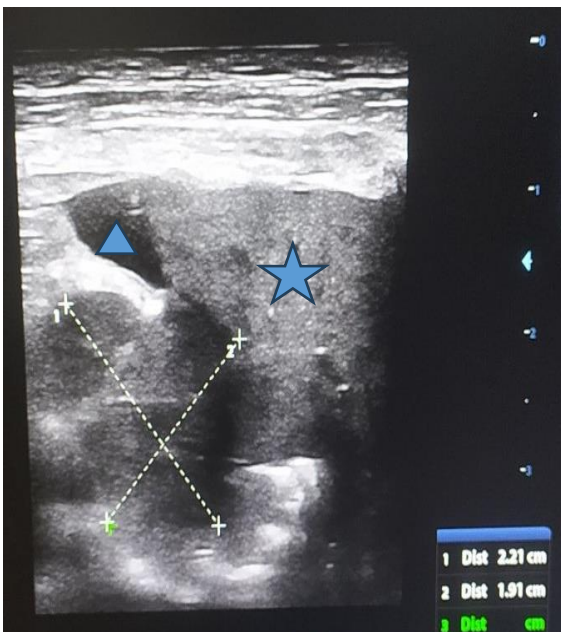


Figure 2: USG image in a different patient shows a central lung mass (between calipers) with adjacent collapsed lung (star) and minimal pleural effusion (arrow head)

The procedures were performed in Siemens Acuson NX3 machine using curvilinear (2-5 MHz) or linear (8-12 MHz) array probe depending upon the depth requirement to visualize the lesion as well as surrounding tissue.

Biopsy were performed under all aseptic precautions, after giving local anesthetic (2% lignocaine) along the desired biopsy path up to the pleura for lung mass and till the lymph node

capsule in suspicious lymph nodes. Biopsy sample from the lung mass (Figure 3) or suspicious malignant lymph node (Figure 4) was obtained with 18 G co-axial biopsy gun. Three to five core cut tissue samples were collected using co-axial technique. For lesions which were not accessible for biopsy, fine needle aspiration cytology (FNAC) was performed with 25G needle. Thoracentesis was performed with 20 ml syringe (18G spinal needle in obese patients) under US guidance.

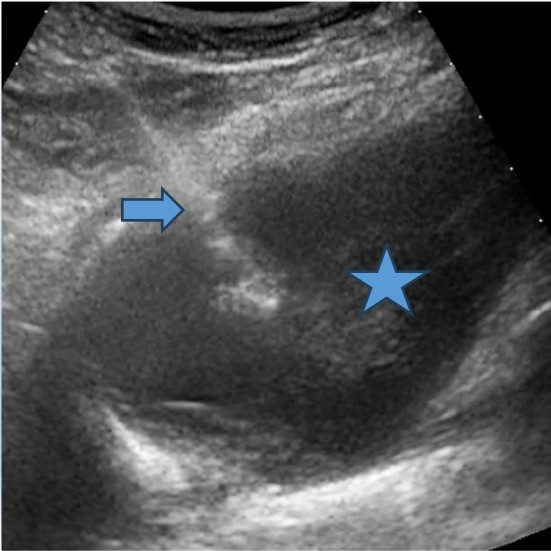


Figure 3: USG guided biopsy of lung mass (star), arrow points to biopsy needle

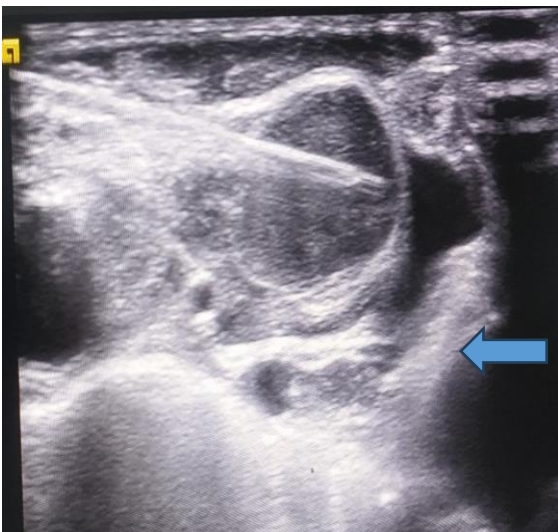


Figure 4: Biopsy from enlarged supraclavicular lymph node. Normal saline injected around this lymph node (arrow) to decrease the risk of injury to adjacent internal jugular vein. Sampling needle is seen in the target lymph node.

After the procedure, the biopsy site was examined for occurrence of complications like bleeding, pneumothorax at the procedural table side. The needle tract was then compressed. Pressure bandage applied. Patient was then shifted to observation bed kept in the biopsy side down position to acquire adequate compression with body weight. Patient was

observed for a period of one hour. Repeat ultrasound evaluation was done after one hour to look for development of complications like pneumothorax and hemothorax.

For patients, complaining pain, inj. Ketorolac 30 mg was given. Pneumothorax was identified by the dirty air shadowing at the puncture site

immediately on ultrasound (US). Those patients with pneumothorax and without shortness of breath were immediately kept in biopsy side down position and were treated with high flow oxygen @ 5-10 L/min via face mask to maintain oxygen saturation above 92%. Patients were observed for an hour and were regularly monitored for respiratory difficulty. Those not having any symptoms were weaned off oxygen after an hour and were observed for further another one hour. Clinical monitoring of the progression or development of symptoms as well as SpO₂ monitoring was done. If no symptoms of respiratory difficulty during the period, patient were reassessed on US and not showing features of pneumothorax were sent home.

The reports of the histopathology or cytology were collected. Any diagnosis from the analysis was taken as diagnostic yield whereas no diagnosis and requiring repeat examination was taken as diagnostically non – yielding. Diagnostic yield was evaluated by binary classification. Frequency of complications were documented and analyzed.

All the obtained data were entered in the MS Excel 2019 and converted into IBM SPSS version 25 for statistical analysis. The result of the study were analyzed using mean, standard deviation. Various percentages were calculated and were presented in pictorial form with pie-charts, table, line diagram and bar diagram. Results on continuous measurements are presented as mean \pm SD and results on categorical measurement are presented in numbers (%).

RESULTS

Total 48 procedures in 46 patients with diagnosis of bronchogenic carcinoma were

included. Mean age was 65 ± 11 years (range 43 to 82 years). Among 46 cases, 25 (54.35%) were male and 21 (45.65 %) were female. Most of the patients (n=39, 84.78 %) were smokers.

Out of total 48 US guided procedures done in 46 patients, 68.75 % (n=33) underwent ultrasound guided biopsy of lung mass, 16.67 % (n=8) underwent biopsy from the supraclavicular lymph node, 12.50% (n=6) underwent thoracentesis from the pleural effusion, 2.08% (n=1) underwent biopsy from the metastatic liver lesion (Table 1). In two patients, both biopsy from lung mass and thoracocentesis were performed.

Table 1: Various ultrasound guided procedures (48 procedures in 46 patients)

Procedure	Frequency (%)
Lung mass biopsy	33 (68.75)
Supraclavicular lymph node biopsy	8 (16.67)
Thoracocentesis	6 (12.50)
Biopsy from metastatic liver lesion	1 (2.08)
Total	48 (100)

Out of 48 procedures, overall diagnostic yield was obtained in 89.58% cases (n=43). Diagnostic yield was 93.93% (31 out of 33) among the ultrasound guided lung mass biopsy, 87.50% (7 out of 8) among the supraclavicular lymph node biopsy, 100% (1 out of 1) among biopsy from metastatic liver lesion and 66.67 % (4 out of 6) among those who underwent thoracocentesis. Maximum diagnostic yield was obtained from biopsy of metastatic liver lesion followed by biopsy of lung mass and supraclavicular lymph node. The lowest diagnostic yield was from the thoracocentesis sample analyzed by cytology (Figure 5).

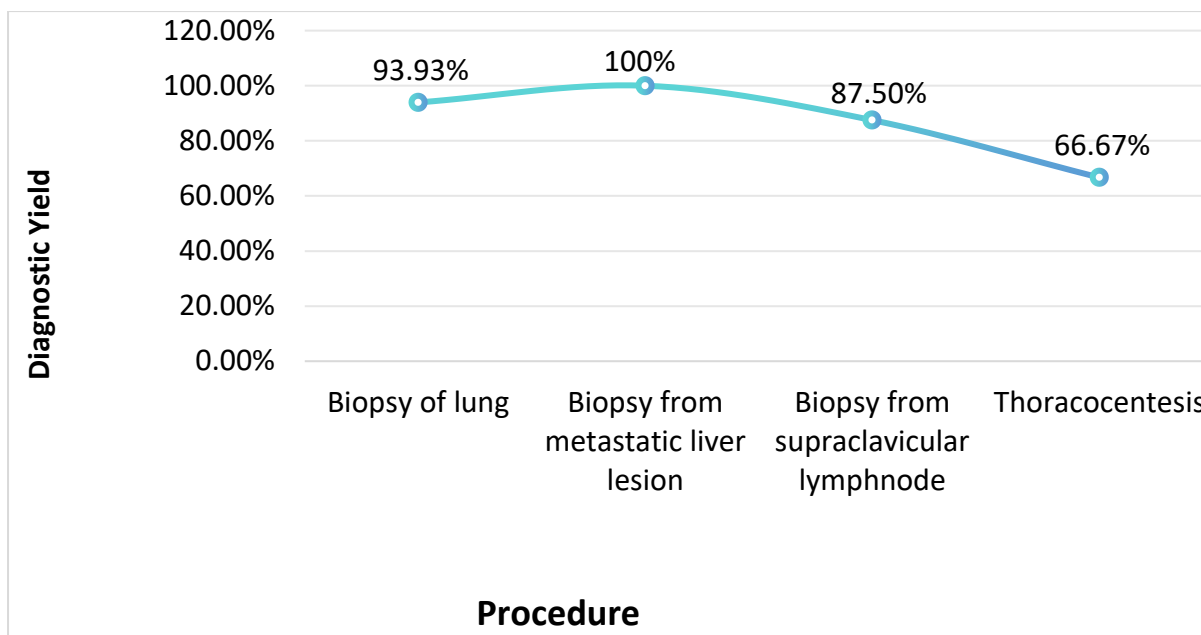


Figure 5: Line diagram showing diagnostic yield of USG guided diagnostic interventional procedures

Out of 48 procedures in 46 patients, 14.58% of patients (n=7) complained of mild pain. Among these only 1 patient required injectable painkiller (Inj. Ketorolac 30 mg I.V) for pain management. Small pneumothorax occurred in 4.17% cases (n=2) and was managed with high flow oxygen (Table 2). None of the patient with pneumothorax required intercostal chest tube drainage.

Table 2: Complications of ultrasound guided procedures (48 procedures in 46 patients)

Complications	Frequency of procedure n (%)
None	39 (81.25)
Pain	7 (14.58)
Pneumothorax	2 (4.17)
Total	48 (100)

Out of these 46 cases, 10.87 % (n=5) showed direct extension to adjacent chest wall. Rib erosion was noted in two (4.34%) cases. Among them 14 cases (30.43 %) had enlarged supraclavicular lymph node at presentation. Out of 46 cases, 28.26 % (n=13) had pleural

effusion. Among these cases with pleural effusion, enhancing pleural nodules/deposits were appreciated in 8 cases (61.5%), suggestive of malignant pleural effusion. Total 14 cases (30.43% cases) had CT diagnosed metastasis at presentation (Table 3).

Table 3: Various Imaging findings (n=46)

Finding	Frequency (%)
Enlarged supraclavicular lymph node	14 (30.43)
Distant metastasis	14 (30.43)
Pleural Effusion	13 (28.26)
Chest wall invasion lesion	5 (10.87)
Total	46 (100)

DISCUSSION

Though lung cancer can be suspected in imaging, tissue diagnosis is must for the confirmation of the diagnosis and planning for the treatment. Sample for tissue/cytological diagnosis can be obtained by bronchoscopic biopsy for central mass located near to primary or secondary bronchi. Peripheral tumors can be

biopsied either under Ultrasound or Computed Tomography (US or CT) guidance. Other methods include cytological analysis of pleural fluid, sputum, bronchial wash. Tissue sample can also be obtained from the metastatic lesions as well as from accessible enlarged lymph nodes.

Ultrasound is a widely used rapid, non-invasive, inexpensive and readily accessible imaging technique. It can be done at bed-side also. It has no risk of radiation hazard. Peripheral lung mass adjacent to chest wall, central/peripheral lung mass with adjacent collapse/consolidation reaching up to periphery, lung mass with contiguous involvement of chest wall, pleural nodularity/thickening are well assessed and can be sampled under ultrasound guidance. Similarly, US guided sampling can also be done from enlarged supraclavicular lymph nodes, accessible metastatic lymph nodes, metastatic lesions in liver, lung, vertebra and ribs.

We evaluated diagnostic yield and immediate complications of the various ultrasound guided procedures in patients with contrast enhanced computed tomography (CECT) diagnosis of bronchogenic carcinoma.

The overall diagnostic yield of ultrasound guided procedures was 89.58% which was comparable to other studies. [9-11] In a previous similar study, diagnostic yield of ultrasound guided biopsy was 90% with highest yield from chest wall biopsy and lowest from mediastinal biopsy. [9] Diagnostic yield for cancer was 94% in another similar study. [10] Similarly, diagnostic yield of ultrasound guided procedure was 90.6% for malignancy in the past similar study. [11] These findings highlight the high diagnostic potential of ultrasound guided procedures.

Diagnostic yield for ultrasound guided lung mass biopsy was 93.93% which was almost

similar with other studies. [8, 12] In one of the past study, diagnostic yield was 88.3% of ultrasound guided procedures in bronchogenic carcinoma. [8] In another retrospective study of 162 procedures in 158 patients who underwent CT and US-guided biopsies for pleural-based lesions, the diagnostic yield was 92.1% in the US group and 91.8% in the CT group. [12] In this study less complication rate (1.1 %) was seen in USG group as compared to 23.3% in the CT group. We had 100% diagnostic yield from the biopsy of metastatic lesion in liver. As biopsy from liver lesion was performed in only one patient, the result may not represent overall diagnostic yield of metastatic liver lesion.

Diagnostic yield of supraclavicular lymph node biopsy was 87.5% in our study which was similar to the previous study. [13] Diagnostic yield of supraclavicular lymph node biopsy in this study was 81.2%. Supraclavicular lymph node biopsy which is relatively easier to perform helps to identify advanced disease (N3 disease). It also avoids difficult biopsy in patients with centrally located primary mass where image guided procedures are riskier.

The diagnostic yield of the pleural fluid cytology in our study was 66.67 %. The diagnostic yield from the pleural fluid cytology is comparable to various studies in the literature. [14,15] In a past study, the overall accuracy of pleural fluid cytology was 59% with lower accuracy in cases of mesothelioma and squamous cell carcinoma. [14] Another study reported diagnostic yield of 73.2% from malignant pleural fluid cytology. [15] The diagnostic yield from the thoracentesis was lowest among different ultrasound guided procedures done in our study. Similar low diagnostic yield was seen from pleural fluid cytology in other studies as well. [14,15]

Ultrasound guided procedures are safer techniques. In our study, minor complications occurred in 18.75% of patients. Pain was the

most common complain reported in 14.58% of patients. Among these only 1 patient required injectable painkiller (Inj. Ketorolac 30 mg iv) for pain management. Small pneumothorax occurred in 4.17% cases and was managed with high flow oxygen. None of the patient with pneumothorax required intercostal chest tube drainage. The complications rate is comparable to other studies. [8 - 11] A past study reported minor pain in 20% of patients, hemoptysis in 4% of patients and none of the patient's developed pneumothorax. [10] Incidence of pneumothorax was 1.5% in another similar previous study which was marginally lower than ours. [8] Another past study reported 2.7% complication rates in ultrasound guided procedures [11] Hemothorax in 1.1% patients was reported in another study where it resolved with chest tube drainage. [9] None of our patients developed significant hemothorax or hemoptysis.

Relatively small sample size was one of the limitations of our study. We performed only US guided procedures and no comparison was done with CT guided procedures. Comparison with CT guided procedures would be better to label ultrasound guided procedures as more safe procedures. As all the procedures were performed by single person, chance of interpersonal variation is there. Long term follow up of the patients was not done for any long-term complications which was another limitation of our study.

CONCLUSIONS:

In patients with contrast enhanced Computed Tomography diagnosis of bronchogenic carcinoma, ultrasound guided diagnostic procedures have high diagnostic yield and safety. US is also helpful to stage lung carcinoma in adjunct to CECT. Ultrasound should be routinely used for the diagnosis of lung cancer when feasible. Further study on larger sample size and comparative results with CT guided procedures can be done to further

establish the efficacy as well as safety of the procedures.

REFERENCES

1. Worldwide cancer data | World Cancer Research Fund International [Internet]. [cited 2023 Jul 27]. [[Full Text](#)]
2. Population Based Cancer Registry in Nepal. Nepal Health Research Council. 2018 [[Full Text](#)].
3. Piya MK. Epidemiological profile of lung cancer in a Nepalese population: A single-institution review. 2019 May 26;37(15_suppl):e13087–e13087. [[DOI](#)]
4. Birring SS, Peake MD. Symptoms and the early diagnosis of lung cancer. *Thorax* 2005;60:268-269. [[DOI](#)]
5. Park HJ, Lee SH, Chang YS. Recent advances in diagnostic technologies in lung cancer. *Korean J Intern Med* 2020 Mar;35(2):257-268. [[DOI](#)]
6. Zhao ZL, Peng LL, Wei Y, Li Y, Wang GM, Yu MA. The accuracy of ultrasound-guided lung biopsy pathology and microbial cultures for peripheral lung lesions. *J Thorac Dis* 2020;12(3):858-865. [[DOI](#)]
7. Choe J, Kim MY, Baek JH, Choi CM, Kim HJ. Ultrasonography-guided core biopsy of supraclavicular lymph nodes for diagnosis of metastasis and identification of epidermal growth factor receptor (EGFR) mutation in advanced lung cancer. *Medicine* 94(29):p e1209, July 2015. [[DOI](#)]
8. Khan RA, Kumar V, Taimur M, Khan Seedat MA, Arshad MM, Amjad MA. Diagnostic Yield of Ultrasound-guided Trucut Biopsy in Diagnosis of Peripheral Lung Malignancies. *Cureus* 2019 Jun 2;11(6):e4802. [[DOI](#)]
9. Gershman E, Vaynshteyn I, Freidkin L, Pertzov B, Rosengarten D, Kramer MR.

- Marked safety and high diagnostic yield of freehand ultrasound-guided core-needle biopsies performed by pulmonologists. *Thorac Cancer*. 2022 Jun;13(11):1577-1582. [\[DOI\]](#)
10. Hussain M, Ashraf M, Chima K K. Diagnostic Yield of Ultrasound-Guided Tru-Cut Biopsies of Peripheral Lesions by the Pulmonologist. *Ann. Pak. Inst. Med. Sci*. 2015; 11(4): 215-217. [\[Full Text\]](#)
 11. Portela-Oliveira E, Souza CA, Gupta A, Bayanati H, Inacio J, Rakhra K. Ultrasound-guided percutaneous biopsy of thoracic lesions: high diagnostic yield and low complication rate. *Clin Radiol*. 2021 Apr 1;76(4):281–6. [\[DOI\]](#)
 12. Khosla R, McLean A, Smith J. Ultrasound-guided versus computed tomography-scan guided biopsy of pleural-based lung lesions. *Lung India* 2016 Sep-Oct;33(5):487–492. [\[DOI\]](#)
 13. Tey C, Pereira A, Xie C, et al P219 Potential utility of ultrasound guided supraclavicular lymph node biopsy in the diagnosis of lung cancer – remodelling the pathway. *Thorax* 2021;76:A208. [\[DOI\]](#)
 14. Porcel JM, Esquerda A, Vives M, Bielsa S. Etiology of pleural effusions: analysis of more than 3,000 consecutive thoracenteses. *Arch Bronconeumol* 2014 May;50(5):161-5. [\[DOI\]](#)
 15. Assawasaksakul T, Boonsarngsuk V, Incharoen P. A comparative study of conventional cytology and cell block method in the diagnosis of pleural effusion. *J Thorac Dis*. 2017 Sep;9(9):3161-3167. [\[DOI\]](#)