

Role of the American College Of Radiology –Thyroid Imaging Reporting and Data System (ACR TI-RADS) in Differentiating Benign and Malignant Thyroid Nodules

Lalchan S¹, Sharma P², Ghartimagar D³, KC S¹, Gyawali M¹, Poudel A⁴, Dahal R⁵

¹Assistant Professor, ²Associate Professor, ⁴Resident, ⁵Medical Officer, Department of Radiology, Manipal Teaching Hospital, Pokhara, Nepal.

³Professor, Department of Pathology, Manipal Teaching Hospital, Pokhara, Nepal.

Received: November 20, 2021

Accepted: January 29, 2022

Published: July 31, 2022

Cite this paper:

Lalchan S, Ghartimagar D, KC S, Gyawali M, Poudel A, Dahal R. Role of the American College Of Radiology – Thyroid Imaging Reporting and Data System (ACR TI-RADS) in Differentiating Benign and Malignant Thyroid Nodules. *Nepal Journal of Medical Sciences*. 2022;7(2):5-12. <https://doi.org/10.3126/njms.v7i2.47205>

ABSTRACT

Introduction: A thyroid nodule is commonly detected while performing an ultrasound of the neck. American College of Radiology, Thyroid Imaging Reporting and Data System (ACR TI-RADS) is a classification used to characterize thyroid nodules based on ultrasound findings. The objective of this study is to evaluate the role of ACR TI-RADS classification in differentiating benign and malignant thyroid nodules.

Methods: This is a prospective study conducted at Manipal Teaching Hospital. A total of 70 patients presenting to our radiology department for fine needle aspiration cytology (FNAC) of thyroid nodule were enrolled in the study. Thyroid nodules were grouped as 1- 5 according to the ACR TI-RADS. The ACR TI-RADS findings were correlated with FNAC and or biopsy findings as available. Subsequently; sensitivity, specificity, accuracy, positive predictive value and negative predictive value of ACR TI-RADS in differentiating benign from malignant nodules were assessed.

Results: Mean age of patients in our study was 52.16 years (18-89 years). Male patients were 11 (15.7 %) and female were 59 (84.30 %). According to Ultrasonography; 1.4% of thyroid nodules were labelled as ACR TI-RADS 1; 21.4% as ACR TI-RADS 2; 32.85% as ACR TI-RADS 3; 28.6 % as ACR TI-RADS 4 and 15.7 % as ACR TI-RADS 5. ROC curve analysis showed AUC of 0.78 (95% CI). ACR TI-RADS had sensitivity, specificity, positive predictive value, negative predictive value and diagnostic accuracy of 87.5%, 68.5 %, 45.16 %, 94.87 %, 72.86 % respectively.

Conclusion: ACR TI-RADS has high sensitivity and accuracy in differentiating benign and malignant thyroid nodules.

Keywords: Biopsy; FNAC; Thyroid Nodule

Correspondence to: Dr. Subita Lalchan
Department of Radiology and Imaging
Manipal Teaching Hospital, Pokhara, Nepal
Email: subita.lalchan@manipal.edu.np



Licensed under CC BY 4.0 International License which permits use, distribution and reproduction in any medium, provided the original work is properly cited

INTRODUCTION

A thyroid nodule is a distinct lesion within the thyroid gland that is palpable or radiologically distinct from the surrounding thyroid parenchyma. Thyroid nodules are detected in approximately 8% of adults by palpation, 41% by USG and 50% at autopsy.[1] In 10% of thyroid nodules, malignancy was detected. [2,3,4] Thyroid carcinoma is the commonest endocrine malignancy, accounting for 1.9% of all new cancers diagnosed annually in the United States.[5] The main concern while assessing thyroid nodules is to rule out malignant nodules. Ultrasonography is the simple, non-invasive, less costly and easily available imaging technique for the evaluation of thyroid nodules. Fine needle aspiration cytology is the standard procedure available to differentiate benign and malignant nodules. In few patients, an excisional biopsy may be needed for a definite diagnosis. FNAC is a painful and invasive procedure. It can sometimes lead to complications likely bleeding and infection. Repeat FNAC may be required in some cases. There are no appropriate guidelines for which nodules to undergo fine needle aspiration and which can be followed up. Most of the nodules in the thyroid are benign and do not require FNAC and/or surgery. Therefore, it is essential to have an authentic ultrasound classification system and guidelines for the assessment of the thyroid nodules and to differentiate between benign and malignant lesions with a good level of confidence, thereby reducing the unnecessary invasive procedures like FNAC and biopsy.

Horvath first proposed the Thyroid Imaging Reporting and Data System (TI-RADS) in 2009 based on ultrasound findings.[3] Since then, many classifications have been modified and revised for the evaluation and management of thyroid nodules. In 2017 AD, the American College of Radiology (ACR) TI-RADS was proposed by Tessler et al.[6] This classification helps in selecting thyroid nodules which require undergoing

FNAC and others which can be followed up. However, its application in daily practice requires further evaluation.

This study was done to determine the sensitivity, specificity, positive predictive value, negative predictive value and accuracy of ACR TI-RADS in differentiating benign from malignant nodules.

METHODS

This was a prospective cross-sectional study conducted at the radiology department of Manipal Teaching Hospital, Pokhara. The study was conducted from November 2020 to June 2021. The approval of the study was taken from the ethical review board of Manipal Teaching Hospital, Fulbari, Pokhara. Informed consent was taken from the patients before the study. Patients above 16 years of age sent to the radiology department for USG-guided FNAC of thyroid nodules were included in the study. Patients with a history of surgery on the thyroid gland and patients with known thyroid malignancy were excluded from the study. Patients who refused to give consent for the study and patients with inconclusive FNAC reports were also excluded. The patient was asked to lie supine on the bed with a pillow under the shoulder making neck hyperextended. USG was done on LOGIQ P7 GE machine using a high-frequency probe (12 Hz). Both lobes of the thyroid and isthmus were evaluated in detail. A total number of thyroid nodules were noted. The size of the nodule was recorded. Each thyroid nodule was described under the following features: echogenicity, composition, shape, margins and echogenic foci. The composition of the thyroid nodule was described as solid, cystic, spongiform, and mixed (nodule with solid and cystic components). Echotexture of the nodule was described as anechoic, hyperechoic (echotexture of the nodule is more than thyroid parenchyma), isoechoic (nodule is isoechoic to adjacent thyroid parenchyma), hypoechoic (echotexture of the nodule is less than that of thyroid parenchyma but more

than that of neck muscles) or very hypoechoic (echotexture of the nodule is less than that of neck muscles). Thyroid nodule was classified into two groups according to their shape - wider than tall (transverse diameter greater than anteroposterior diameter) or taller than wide (anteroposterior diameter greater than transverse diameter). The margin of the thyroid nodule was noted as smooth, irregular/lobulated, with extra-thyroidal extension. Calcifications/ echogenic foci within the nodule were described as having comet tail artefact, peripheral or rim calcifications, macrocalcifications (larger than 1mm) or microcalcifications (punctate echogenic foci). Ultrasound findings of the nodule were noted and a score was given according to its features. Total scoring was done for each nodule and subsequently, the nodule was assigned an ACR TI-RADS score (1 to 5) as described in figure 3. Thyroid nodules with ACR TI-RADS 4 and 5 were considered malignant and nodules with a score of 1-3 were designated as benign nodules. If more than one nodule were present in a patient, a thyroid nodule with a higher score was taken into consideration.

Under USG guidance; FNA was performed by using a 22 G needle with standard technique and sent for cytological evaluation. The final diagnosis for each nodule was confirmed by the FNAC report and histopathology report when the excisional biopsy was done. Statistical analysis was performed using Statistical Package for Social Sciences version 21. Sensitivity, specificity, negative predictive

value (NPV), positive predictive value (PPV) and accuracy were calculated. ROC (receiver operating characteristic curve) curve was drawn.

RESULTS

A total of 80 patients were included in the study. One had a history of surgery on the thyroid and one was a known case of thyroid malignancy. Eight patients had inconclusive FNAC reports. Hence, ten patients were excluded from the study and a total of 70 patients were enrolled for statistical analysis. The mean age was 52.16 years. The youngest patient in the study was 18 years and the oldest was 89 years old female. Female patients (59) were more in number than male patients (11) as shown in Figure 1. Maximum patients were in the age group of 41-60 years (50 %) as shown in Figure 2.

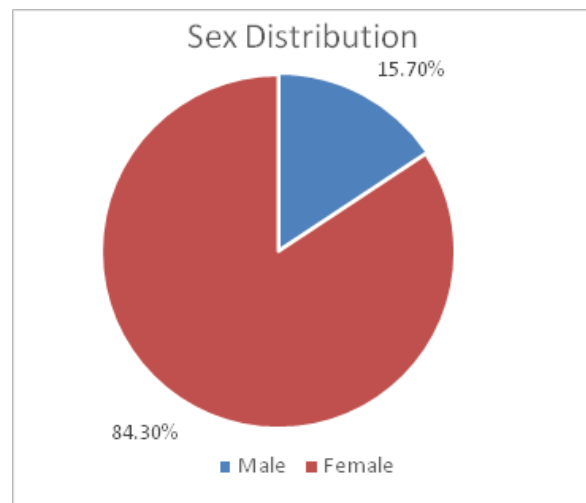


Figure1: Sex distribution

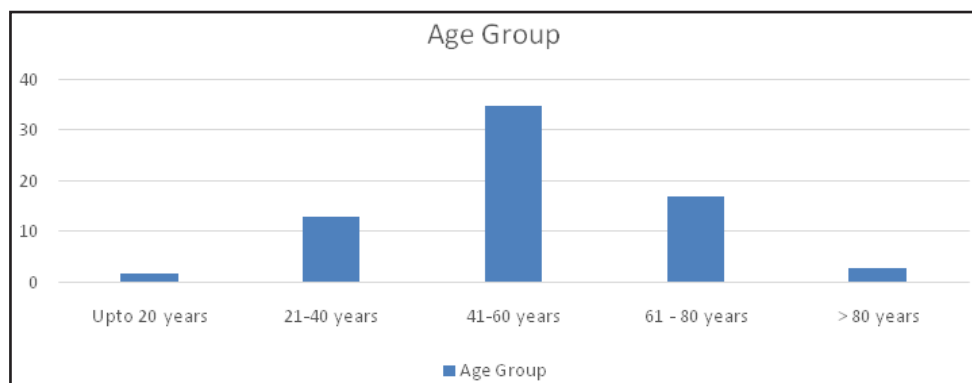


Figure2: Age group

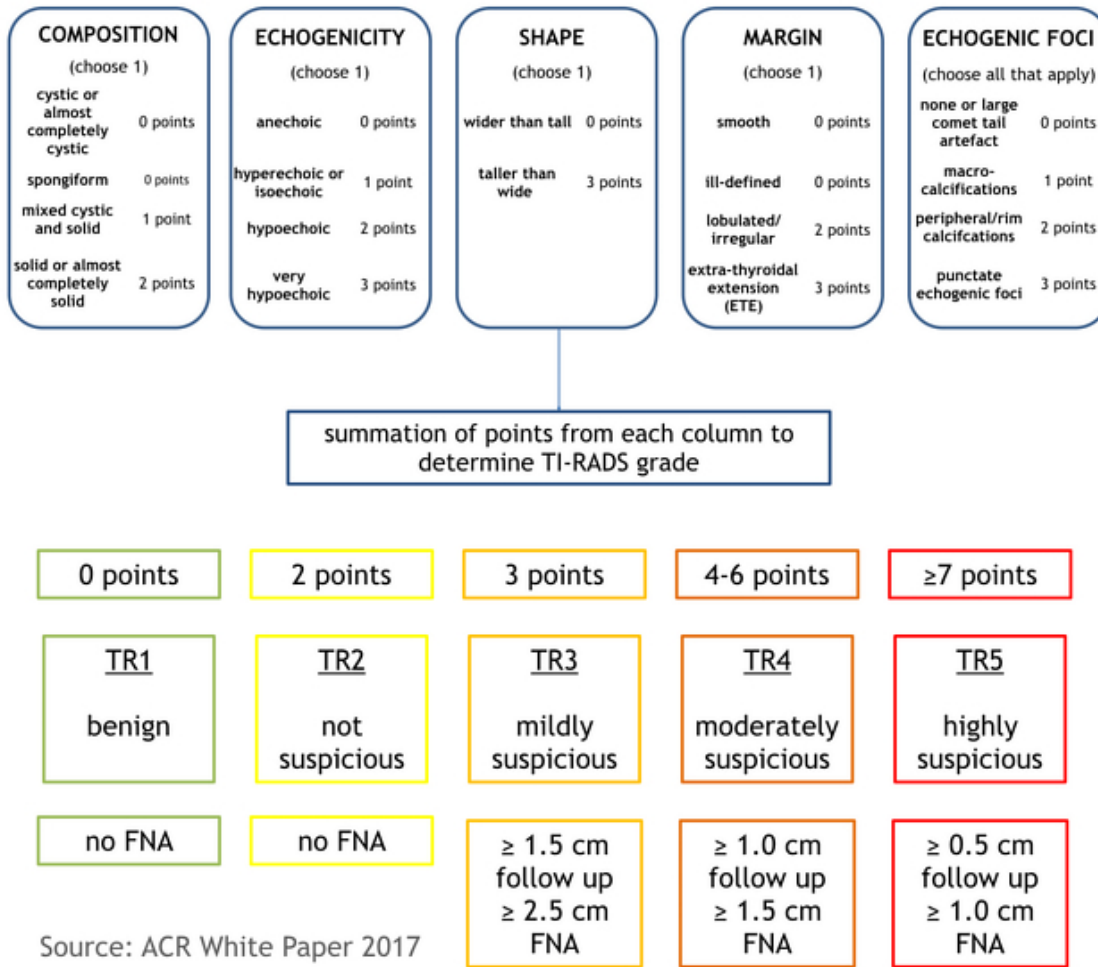


Figure 3: ACR-TIRADS scoring system

Out of 70 cases studied; 54 nodules (77.1 %) were found to be benign and 16 nodules (22.9 %) were found to be malignant based on cytology/histopathology reports. Colloid nodules with or without cystic degeneration were the most common benign nodules (94.4%). Papillary carcinoma was the commonest malignant nodule (75 %) detected in the present study. The mean age of patient diagnosed with benign and malignant nodules was 52.37 years and 51.44 years respectively. There was no statistical relationship between the age of the patient and malignancy. There was no statistical relationship between the sex of the patient and malignancy (p-value is 0.245). Benign nodule in our study was 12-72mm (mean size - 28.06mm) in size and the malignant nodule was 11-54mm (mean size -

28.94mm). According to ultrasound findings; 1.4% of thyroid nodules were classified as ACR TI-RADS 1; 21.4% as ACR TI-RADS 2; 32.85% as ACR TI-RADS 3; 28.6 % as ACR TI-RADS 4 and 15.7 % as ACR TI-RADS 5. All the ACR TI-RADS 1 and 2 nodules were benign. Two nodules out of 23 nodules classified as ACR TI-RADS 3 turned out to be malignant. Twenty nodules were classified as ACR TI-RADS 4. Among them; only three nodules were malignant and 17 were benign nodules. Total of 11 nodules were classified as ACR TI-RADS 5 nodules, all of which turned out to be malignant nodules. The risk of malignancy in ACR TI-RADS categories 1 and 2 was 0%; 8.69 % in category 3, 15% in category 4 and 100 % in category 5 as shown in table 2. The sensitivity, specificity

and diagnostic accuracy of ACR TI-RADS in differentiating benign and malignant nodules were 87.5 %, 68.5 %, and 72.86 % respectively. The positive predictive value and negative predictive values were 45.16 % and 94.87 % respectively. The ROC curve of diagnostic performance of ACR TI-RADS compared with cytology/histopathology drawn showed an area under the curve (AUC) of 0.78 (95% confidence interval: 0.661-0.911).

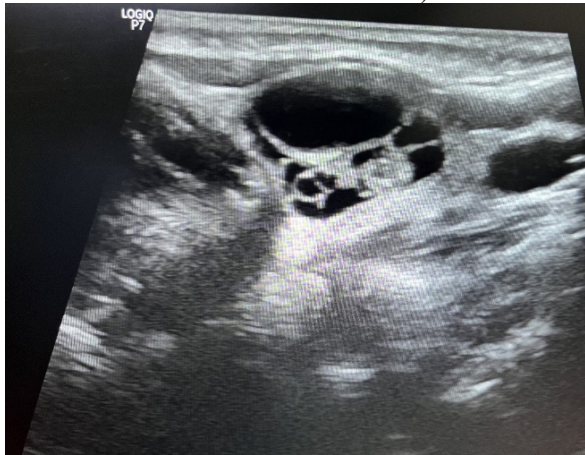


Figure 4: USG showing cystic thyroid nodule with solid component (TIRADS 2)

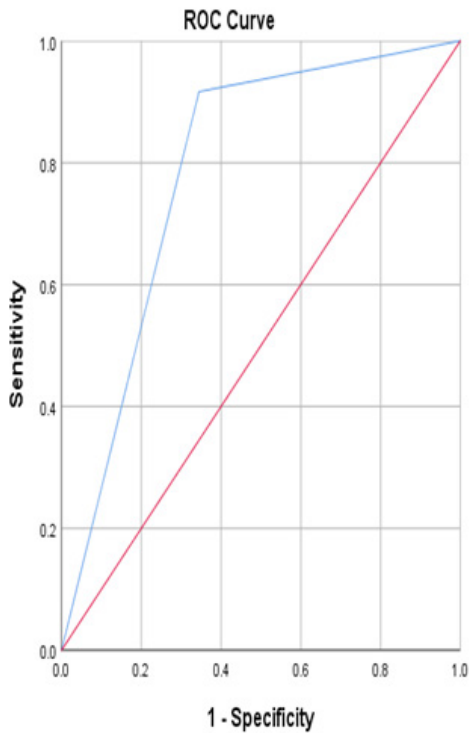


Figure 5: ROC curve

Table 1: ACR TI-RADS findings and cytology /histopathology findings

ACR TI-RADS	Histopathology		Total
	Malignant	Benign	
Malignant	14	17	31
Benign	2	37	39
Total	16	54	70

Table 2: Risk stratification by ACR- TIRADS

TIRADS category	Number of benign lesions	Number of malignant lesions	Total	Risk of malignancy (%)
1	1	0	1	0
2	15	0	15	0
3	21	2	23	8.69
4	17	3	20	15
5	0	11	11	100

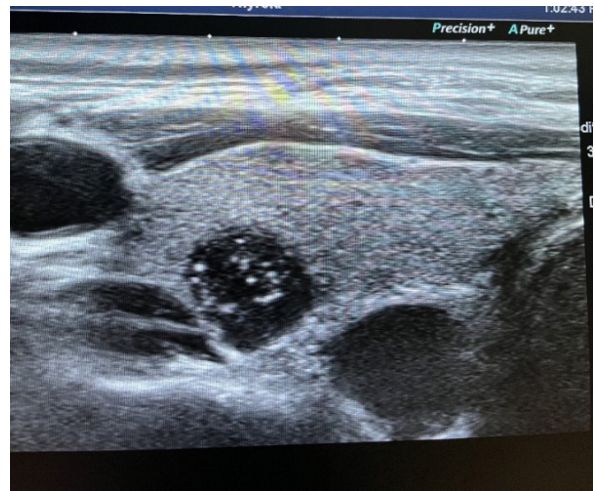

Figure 6: USG showing hypoechoic solid thyroid nodule with punctate echogenic foci (TIRADS-5)

DISCUSSION

In recent years, there has been an increase in the detection of thyroid nodules by ultrasound, thereby increasing number of FNAC. Malignancy was detected in 3-7 % of thyroid FNAC and the benign finding was found in 60-70 % of thyroid FNAC in a study

by Cibas et al.[7] Hence, there is a need for an appropriate classification system to guide in evaluation and management of thyroid nodules to avoid unnecessary FNAC and biopsy. Many ultrasonography based scoring systems have been used to differentiate the benign and suspicious nodules with the risk of malignancy. Among them; ACR TI-RADS is the one followed in our hospital. More females (84.3 %) were found in our study similar to other studies.[8,9,10] Higher malignancy rate (22.9 %) was found in our study while other studies showed a lower prevalence rate of malignant nodules of 9.2-13%.[11,12,13] The mean age of a patient with benign and malignant nodules was 52.37 years and 51.44 years respectively. There was no significant statistical relationship between age and sex of patient and malignancy. The youngest patient with papillary carcinoma in our study was 19 years old female. The mean size of benign thyroid nodules was 28.06mm and that of malignant thyroid nodules was 28.94 mm. There was no statistical relationship between the size of the lesion and malignancy. The colloid nodule was the most common benign nodule and papillary carcinoma was the most common malignant nodule as found in another study.[12] Three patients with papillary carcinoma had nodal metastasis at presentation. Similar to a study by Ewid et al. more nodules were classified as ACR TI-RADS 3 (32.85%) and ACR TI-RADS 4 (28.6%).[8] Similar to studies by M. Ewid et al. and Sharma et al; the risk of the nodule being malignant in ACR TI-RADS categories 1 and 2 was found to be 0%.[8,13] Similar to other studies, the risk of malignancy increased as TI-RADS number increased in the present study. Our study found the risk of malignancy to be 8.69 % in category 3, 15% in category 4 and 100 % in category 5. The risk of malignancy for ACR TI-RADS in a study by Sharma P et al[13] was 3.1% for TR3, 14.3% for TR4 and 41.7% for TR5. Ewid et al. found the risk of malignancy to be 3.7% for TI-RADS 3, 6.6% for TI-RADS 4 and 22.7% for TI-RADS 5 nodules.[8] Our study showed

a higher risk of malignancy in TIRADS 3 nodules in comparison to other studies.

All the ACR TI-RADS 1 and 2 nodules in our study were benign nodules similar to other studies.[8,13] All the 11 nodules classified as TI-RADS 5 nodules were diagnosed as malignant nodules. Most of the nodules (21/23) labelled as ACR TI-RADS 3 were benign nodules and only two of them were malignant. Twenty nodules were labelled as ACR TIRADS 4. A higher percentage of nodules were found to be benign in ACR TI-RADS 4 category [Benign – 17 (85%), Malignant – 3 (15 %)]. ACR TI-RADS classification recommends FNAC for ACR TI-RADS 4 nodule with size > 1.5cm and ACR TI-RADS 3 nodule with > 2.5cm. In our opinion, there is a need for further sub-classification of ACR TI-RADS 4 as 4a, 4b, and 4c based on the absence and presence of one or more suspicious features respectively. Suspicious features are - solid nodule; hypo and very hypoechoic echotexture; taller than wider shape; irregular margins; extrathyroid extension and presence of microcalcifications. Similarly; we feel it would be better to classify ACR TI-RADS 3 as 3a and 3b based on the absence or presence of suspicious features respectively. We would like to recommend FNAC for 3b, 4b and 4c category lesions more than 1cm in size and follow up for category 3a and 4a lesions. By doing so, we may be able to reduce the number of unnecessary FNAC without missing malignant nodules.

The sensitivity, specificity and diagnostic accuracy of ACR TI-RADS in differentiating benign and malignant nodules were 87.5 %, 68.5 %, and 72.86 % respectively in the present study. The positive predictive value and negative predictive values were 45.16 % and 94.87% respectively. A high negative predictive value suggests that those nodules categorized as benign by ACR TI-RADS classification need not undergo FNAC. M Ewid et al. found lower sensitivity than our study (75%) and comparable specificity and negative predictive value (specificity-62.35%, negative predictive value – 96.3%).[8] Our

findings were similar to the study by Tan et al. with sensitivity and specificity of 85.7% and 51.1% respectively.[14] Sharma et al. found high sensitivity (92.31 %) and low specificity (40.23 %) in comparison to our study.[13]

CONCLUSION

ACR TI-RADS classification has high sensitivity and accuracy in differentiating benign and malignant nodules. It can be considered a reliable and non-invasive technique for the evaluation and management of thyroid nodules. However, more studies with a large sample size in different populations are required for assessing the role of ACR TI-RADS in classifying benign and malignant nodules. Also, we feel this system of classification requires some modifications for better results.

CONFLICT OF INTEREST

None

SOURCES OF FUNDING

None

REFERENCES

1. Frates MC, Benson CB, Charboneau JW, Cibas ES, Clark OH, Coleman BG, et al. Management of thyroid nodules detected at US: Society of Radiologists in Ultrasound consensus conference statement. *Radiology*. 2005;237(3):794–800. <http://dx.doi.org/10.1148/radiol.2373050220>
2. Hoang JK, Lee WK, Lee M, Johnson D, Farrell S. US Features of thyroid malignancy: pearls and pitfalls. *Radiographics*. 2007;27(3):847–60; discussion 861-5. <http://dx.doi.org/10.1148/rg.273065038>
3. Horvath E, Majlis S, Rossi R, Franco C, Niedmann JP, Castro A, et al. An ultrasonogram reporting system for thyroid nodules stratifying cancer risk for clinical management. *J ClinEndocrinolMetab*. 2009;94(5):1748–51. <http://dx.doi.org/10.1210/jc.2008-1724>
4. Kwak JY, Han KH, Yoon JH, Moon HJ, Son EJ, Park SH, et al. Thyroid imaging reporting and data system for US features of nodules: a step in establishing better stratification of cancer risk. *Radiology*. 2011;260(3):892–9. <http://dx.doi.org/10.1148/radiol.11110206>
5. Jemal A, Murray T, Ward E, Samuels A, Tiwari RC, Ghafoor A, et al. Cancer statistics, 2005. *CA Cancer J Clin*. 2005;55(1):10–30. <http://dx.doi.org/10.3322/canjclin.55.1.10>
6. Tessler FN, Middleton WD, Grant EG, Hoang JK, Berland LL, Teefey SA, et al. ACR thyroid imaging, reporting and data system (TI-RADS): White paper of the ACR TI-RADS committee. *J Am CollRadiol*. 2017;14(5):587–95. <http://dx.doi.org/10.1016/j.jacr.2017.01.04>
7. Cibas ES, Ali SZ, NCI Thyroid FNA State of the Science Conference. The Bethesda System for Reporting Thyroid Cytopathology. *Am J ClinPathol*. 2009;132(5):658–65. <http://dx.doi.org/10.1309/AJCPPLWMI3JV4LA>
8. Ewid M, Naguib M, Alamer A, El Saka H, Alduraibi S, AlGoblan A, et al. Updated ACR Thyroid Imaging Reporting and Data Systems in risk stratification of thyroid nodules: 1-year experience at a Tertiary Care Hospital in Al-Qassim. *Egypt J Intern Med*. 2020;31(4):868–73.
9. Bhatta S, Makaju R, Mohammad A. Role of fine needle aspiration cytology in the diagnosis of thyroid lesions. *J Pathol Nepal*. 1970;2(3):186–8. <http://dx.doi.org/10.3126/jpn.v2i3.6018>
10. Choudhary PK, Nepal N, Mainali N, Meenakshi B. Implementation of Bethesda system in thyroid aspirate: A cyto-histopathological correlation study. *J Pathol Nepal*. 2016;6(11):902–5. <http://dx.doi.org/10.3126/jpn.v6i11.15648>
11. Papini E, Guglielmi R, Bianchini A, Crescenzi A, Taccogna S, Nardi F, et al. Risk of malignancy in nonpalpable thyroid nodules: predictive value of ultrasound and color-Doppler features. *J ClinEndocrinolMetab*. 2002; 87(5): 1941–6. <http://dx.doi.org/10.1210/jcem.87.5.8504>
12. Khadka H, Sharma S, Ghimire RK, Sayami G. Characterization of thyroid nodule by sonographic features. *Nepal J Radiol*. 2018;7(1–2):19–26. <http://dx.doi.org/10.3126/njr.v7i1-2.19365>
13. Sharma P, Elfatairy K, Gandhi D,

- Sawhney H, Osman M, Kochar PS, et al. Diagnostic performance of ACR-TIRADS in differentiating benign from malignant thyroid nodules in patients undergoing fine-needle aspiration biopsy: Comparative study based on five international guidelines for management of thyroid nodules. *J EndocrinolMetab.* 2021;11(3-4):69-75. <http://dx.doi.org/10.14740/jem735>
14. Tan L, Tan YS, Tan S. Diagnostic accuracy and ability to reduce unnecessary FNAC: A comparison between four Thyroid Imaging Reporting Data System (TI-RADS) versions. *Clin Imaging.* 2020;65:133-7. <http://dx.doi.org/10.1016/j.clinimag.2020.04.029>