

Diagnostic Accuracy of Ultrasonography in Detecting Ureteric Calculi in Patients with Renal Colic Taking Non-Contrast Multidetector Computerized Tomography of Kidney, Ureter, and Bladder (CT KUB) as the Gold Standard

Lalchan S¹, Sharma P², KC S¹, Gyawali M¹, Poudel A³

¹ Assistant Professor, ² Associate Professor, ³ Resident, Department of Radiology, Manipal Teaching Hospital, Pokhara, Nepal

Received: June 20, 2021

Accepted: August 29, 2021

Published: January 31, 2022

Cite this paper:

Lalchan S, Sharma P, KC S, Gyawali M, Poudel A. Diagnostic accuracy of Ultrasonography in detecting ureteric calculi in patients with renal colic taking Non-Contrast Multidetector Computerized Tomography of Kidney, Ureter, and Bladder (CT KUB) as the gold standard. *Nepal Journal of Medical Sciences*. 2022;7(1):56-61. <https://doi.org/10.3126/njms.v7i1.44589>

ABSTRACT

Introduction: The goal of this study is to find the sensitivity, specificity, and diagnostic accuracy of ultrasonography in detecting ureteric calculi in patients with renal colic taking NECT KUB as the gold standard.

Methods: All patients with acute renal colic presenting in the radiology department for ultrasonography and NECT KUB were enrolled in the study. Sensitivity, specificity, positive predictive value (PPV), negative predictive value (NPV), and diagnostic accuracy of ultrasonography in detecting ureteric calculi were calculated by taking NECT KUB as the gold standard test.

Results: A total of 88 patients were enrolled in the study. The mean age was 37 years. The sensitivity, specificity, positive predictive value, negative predictive value, and diagnostic accuracy of ultrasonography for the detection of ureteric calculi were found to be 85.8 %, 80 %, 97.1 %, 42.1 %, and 85.2 % respectively in the present study.

Conclusion: Ultrasonography shows high sensitivity and specificity for the diagnosis of ureteric calculi. It is a cheap, non-invasive, and easily available modality and there is no risk of radiation exposure. NECT KUB should be reserved for that patient for whom ultrasonography is not able to give a diagnosis.

Keywords: *Multidetector Computed Tomography; Renal Colic; Ultrasonography; Ureteral Calculi*

Correspondence to: Dr. Subita Lalchan
Department of Radiology
Manipal Teaching Hospital, Pokhara, Nepal
Email: dr.subitajwarchan@gmail.com



Licensed under CC BY 4.0 International License which permits use, distribution and reproduction in any medium, provided the original work is properly cited

INTRODUCTION

Patients with acute renal colic usually present in the emergency department with severe flank pain with radiation to the groin. Plain x-ray abdomen, ultrasonography, intravenous urography, and computerized tomography are the imaging modalities for evaluation of patients with renal colic. The commonest cause of renal colic is ureteric calculi. Plain radiographs of the abdomen are not sensitive to radiolucent calculi. Phleboliths, fecoliths, and mesenteric calcifications are not easily differentiated from urinary tract calculi in plain radiographs of the abdomen. Hence, plain radiography was slowly replaced by intravenous urography (IVU) for detecting urinary tract calculi. IVU requires an intravenous contrast medium, which has some risks. It also takes a long time to perform. Nowadays, IVU is being replaced by non-enhanced multidetector computerized tomography of the abdomen. The advantages of NECT KUB over IVU include shorter examination time, avoidance of intravenous contrast medium, greater sensitivity for stone detection, and usefulness for detecting abnormalities other than ureteral stones. Hence; non-enhanced multidetector computed tomography (MDCT) is the imaging modality of choice at present.¹⁻⁶ Major limitations of CT scans are radiation exposure and their high cost. It is also not available in many centers and cannot be used for pregnant patients. On the other hand; ultrasonography can be used for pregnant patients. USG is cheap and easily available in many centers. Many studies are now focusing on the use of ultrasonography in acute ureteric colic.^{7,8, 9} This study aims to find the sensitivity, specificity, positive predictive value, negative predictive value, and diagnostic accuracy of USG in diagnosing ureteric calculi taking NECT KUB as the gold standard.

METHODS

The study was conducted at the Radiology Department of Manipal Teaching Hospital,

Fulbari, Pokhara. The study was conducted from November 2020 to April 2021. The approval of the study was taken from the ethical review board of Manipal Teaching Hospital, Fulbari, Pokhara. Informed consent was taken from the patients before the study. All the adult patients above 16 years with symptoms of acute renal colic coming to the radiology department for ultrasonography of the abdomen and NECT KUB were included in the study. USG was done in the full bladder on the GE LOGIQ P7. Colour doppler was used when necessary. The size and location of calculi and degree of hydronephrosis were noted. The pelvicalyceal system and PUJ were better assessed in the oblique/lateral position. The proximal ureter was better visualized in the prone position. Mid and distal ureter and VUJ were assessed in the supine position. Calculus in the ureter was detected as echogenic focus with distal acoustic shadowing. Colour doppler was used to produce a twinkling artifact in the echogenic focus for further confirmation of calculus (Figure 2). The number and size of calculus in both kidneys were also noted. The number and size of calculus in the ureter were noted as: at PUJ, proximal ureter, mid ureter, distal ureter, and VUJ. The longest dimension of the calculus was noted. Those patients were followed up for NECT KUB. Plain CT KUB was done in the full bladder in 128 slice PHILIPS CT machine. The patient was kept in the supine position and a scan was taken to include the kidney, ureter, and urinary bladder. Axial sections with 3 mm slice thickness were obtained with a tube current of 200-250 mAs and tube voltage of 120 kV. All images were reconstructed with a 1mm slice thickness. Sagittal and coronal reformatted images were subsequently obtained. Contrast material was not used. Any hyper-dense focus in the urinary bladder, ureter, and kidney was taken as calculus. The size and location of the calculus were noted according to CT scan findings. Patients presenting with complaints of acute pain of

more than 3 days duration were excluded from the study. Patients who were not advised for CT KUB and patients with CT KUB done after 6 hours of ultrasonography were also excluded from the study. Patients not willing to participate and pregnant females were also excluded from the study. Data were recorded and analysis was done using SPSS version 21. A 2x2 table was constructed and specificity sensitivity, negative predictive value, positive predictive values, and diagnostic accuracy were calculated for ultrasonography in diagnosing ureteric calculi keeping NECT KUB as the Gold Standard.

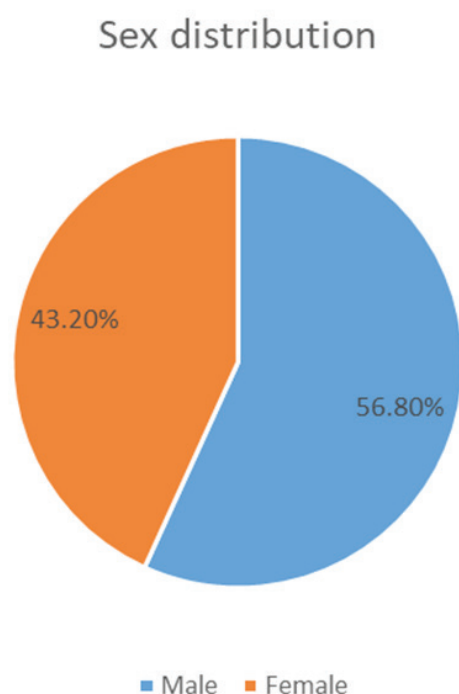


Figure 1: Sex distribution

RESULTS

A total of 88 patients were enrolled in the study. There were 50 males and 38 females. The mean age of the patients was 37 years. The youngest patient was 17 years old and the oldest was 71 years. More patients were found in the age group of 21-40 years as shown in Table 1. More calculi were noted on the right side. In 53.16 % of cases calculi were noted on the right side and in 46.83 % of cases calculi were noted on the left side.

Table 1: Age group distribution

Age group	Frequency	Percentage (%)
≤20 years	6	6.8 %
21-40 years	47	53.4 %
41-60 years	32	36.4 %
1-80 years	3	3.4 %

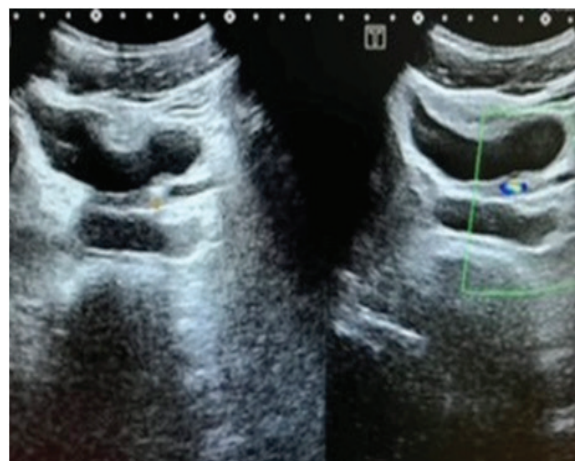


Figure 2: USG showing left VUJ calculus with twinkling artifact

VUJ was the commonest location of calculus in patients with renal colic in our study. It was found in 40.5 % of total cases followed by PUJ as shown in Figure 3. Analyzing the size of calculi; 52.56 % of calculi were of 5-10 mm in size, 31.17 % of calculi were < 5mm in size and 10.25 % of calculi were more than 10mm in size as shown in Table 2. Only two patients had two calculi in the ureters. Two calculi were noted at VUJ and distal ureter. The rest of the other patients had single calculus within the ureter. Hydronephrosis in the kidney was found in almost all cases. Only in four cases, hydronephrosis was absent. In those four patients, calculi less than 3mm were noted in the distal ureter. Ultrasound was not able to detect ureteric calculi in these patients without hydronephrosis. Renal calculi were noted in 38 % of cases. The sensitivity, specificity, positive predictive value, and negative predictive value for detection of ureteric calculi by ultrasound were found

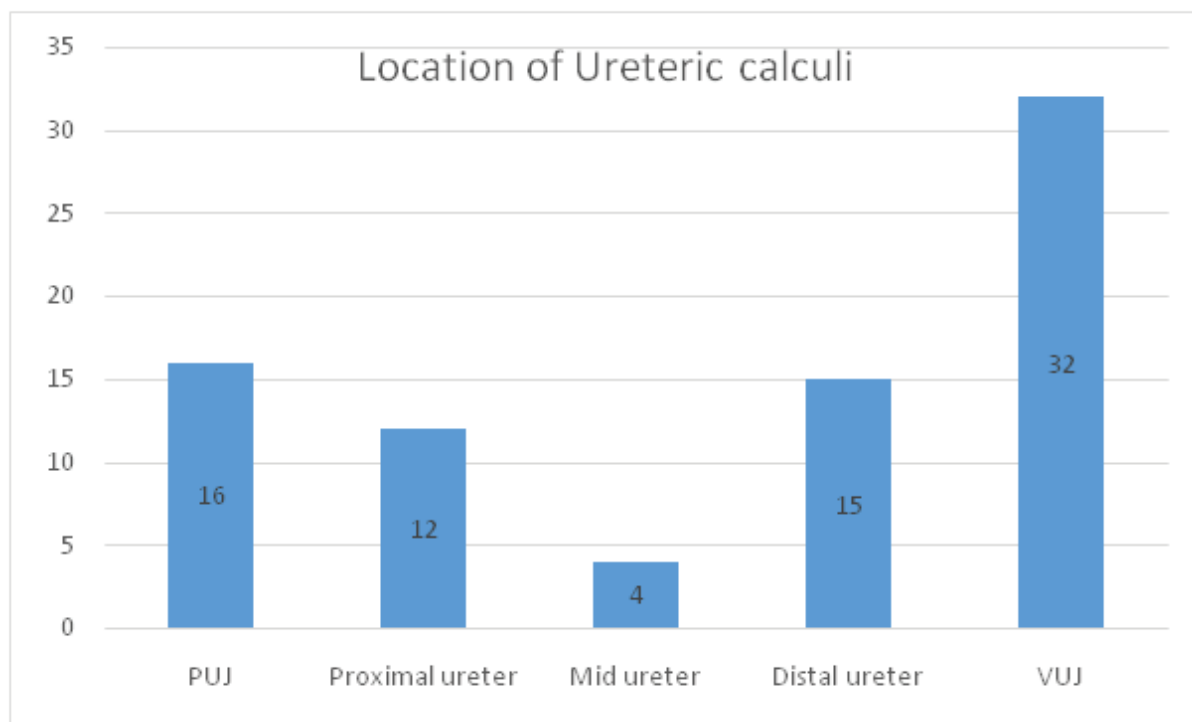


Figure 3: Location of ureteric calculi

to be 85.8 %, 80 %, 97.1 %, and 42.1 % respectively in the present study. The diagnostic accuracy of ultrasound in diagnosing ureteric calculi was found to be 85.2 %.

Table 2: Size of ureteric calculi

Size of calculus	Frequency	Percentage
< 5mm	29	31.17 %
5-10mm	41	52.56 %
>10mm	8	10.25 %

DISCUSSION

Ultrasonography is non-invasive, inexpensive, fast, and radiation-free imaging modality preferred for the evaluation of patients with renal colic. It does not require contrast media. Many studies done in past on the sensitivity of ultrasonography in the detection of ureteric calculi are quite frustrating and range between 12-37% only.¹⁰⁻¹² Our study showed far better results than previous studies. This may be due to advancements in ultrasound machines at present. The sensitivity, specificity, positive predictive value, and negative predictive value for detection of ureteric calculi by ultrasonography were found to be 85.8%, 80%,

97.1 %, and 42.1 % respectively in the present study. The diagnostic accuracy of ultrasound in diagnosing ureteric calculi was found to be 85.2 %. Our findings were comparable with results obtained by Joshi et al. who found an overall sensitivity and specificity of ultrasonography in detecting ureteric calculi to be 87.98% and 93.07% respectively.¹³ Higher sensitivity and specificity were found in other studies than the present study. The sensitivity, specificity, positive predictive value, and negative predictive value for detection of ureteric calculi by ultrasonography were found to be 92.5 %, 100 %, 100%, and 93% respectively in a study by Deepu et al.¹⁴ In the study done by Park et al., the sensitivity and specificity for diagnosing ureteric calculi were found to be 98.3% and 100%.⁹ The study done by Patlas et al. showed sensitivity and specificity of 93% and 95% for diagnosing ureteric calculi in ultrasound.⁸ The reason for lower sensitivity in our study in comparison to the study by Deepu et al. could be because more cases with distal ureteric calculus in our study.¹⁴ It is difficult to visualize distal ureteric calculus by ultrasound due to obscuration by

bowel gas in obese patients. Also in our study, more small size calculi (< 5mm) were found which are difficult to detect on ultrasound whereas in a study by Deepu et al. calculi less than 3mm were less common. Two patients presented with calculi within the distal ureter and VUJ.¹⁴ Ultrasound failed to detect distal ureteric calculus in both patients and was able to detect VUJ calculus only. In our study, the sensitivity and specificity of ultrasound in detecting VUJ calculus were 100 %. All the case of VUJ calculus was detected in ultrasound. However, ultrasonography was unable to detect distal ureteric calculus of size less than 5mm. In such cases when ultrasonography was not able to detect ureteric calculi, NECT KUB can be advised. Although non-contrast CT has higher sensitivity and specificity for diagnosing ureteral stones, it carries the risk of ionizing radiation. It is expensive and not easily available.¹⁵ NECT KUB can be reserved for patients when ultrasound is not able to detect ureteric calculi and when hydronephrosis is absent.

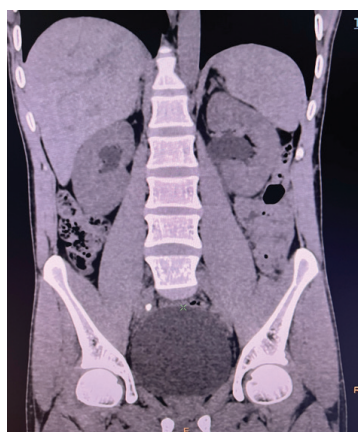


Figure 4: Plain CT KUB showing right mid ureteric calculus

CONCLUSION

Ultrasonography is very effective in the diagnosis and follow-up of patients with ureteric calculi. It should be used as a first-line imaging modality for patients with ureteric colic. NECT KUB should be reserved for those patients whose ultrasound does not give a diagnosis.

CONFLICT OF INTEREST

None

SOURCES OF FUNDING

None

REFERENCES

1. Boulay I, Holtz P, Foley WD, White B, Begun FP. Ureteral calculi: diagnostic efficacy of helical CT and implications for treatment of patients. *Am J Roentgenol.* 1999;172(6):1485–90. <http://dx.doi.org/10.2214/ajr.172.6.10350277>
2. Dorio PJ, Pozniak MA, Lee FT Jr, Kuhlman JE. Non-contrast-enhanced helical computed tomography for the evaluation of patients with acute flank pain. *WMJ.* 1999 ;98(6):30–4.
3. Chen MY, Zagoria RJ, Saunders HS, Dyer RB. Trends in the use of unenhanced helical CT for acute urinary colic. *Am J Roentgenol.* 1999;173(6):1447–50. <http://dx.doi.org/10.2214/ajr.173.6.10584780>
4. Vieweg J, Teh C, Freed K, et al. Unenhanced helical computerized tomography for the evaluation of patients with acute flank pain. *J Urol.* 1998;160(3 Pt 1):679–84. <http://dx.doi.org/10.1097/00005392-199809010-00010>
5. Fielding JR, Fox LA, Heller H, et al. Spiral CT in the evaluation of flank pain: overall accuracy and feature analysis. *J Comput Assist Tomogr.* 1997;21(4):635–8. <http://dx.doi.org/10.1097/00004728-199707000-00022>
6. Smith RC, Verga M, McCarthy S, Rosenfield AT. Diagnosis of acute flank pain: value of unenhanced helical CT. *Am J Roentgenol.* 1996;166(1):97–101. <http://dx.doi.org/10.2214/ajr.166.1.8571915>
7. Moore CL, Scutt L. Sonography first for acute flank pain? *J Ultrasound Med.* 2012;31(11):1703–11. <http://dx.doi.org/10.7863/jum.2012.31.11.1703>
8. Patlas M, Farkas A, Fisher D, Zaghaf

- I, Hadas-Halpern I. Ultrasound vs CT for the detection of ureteric stones in patients with renal colic. *Br J Radiol.* 2001;74(886):901–4. <http://dx.doi.org/10.1259/bjr.74.886.740901>
9. Park SJ, Yi BH, Lee HK, Kim YH, Kim GJ, Kim HC. Evaluation of patients with suspected ureteral calculi using sonography as an initial diagnostic tool: How can we improve diagnostic accuracy? *J Ultrasound Med.* 2008;27(10):1441–50. <http://dx.doi.org/10.7863/jum.2008.27.10.1441>
 10. Erwin BC, Carroll BA, Sommer FG. Renal colic: the role of ultrasound in initial evaluation. *Radiology.* 1984;152(1):147–50. <http://dx.doi.org/10.1148/radiology.152.1.6729105>
 11. Laing FC, Jeffrey RB Jr, Wing VW. Ultrasound versus excretory urography in evaluating acute flank pain. *Radiology.* 1985;154(3):613–6. <http://dx.doi.org/10.1148/radiology.154.3.3881790>
 12. Hill MC, Rich JI, Mardiat JG, Finder CA. Sonography vs. excretory urography in acute flank pain. *Am J Roentgenol.* 1985;144(6):1235–8. <http://dx.doi.org/10.2214/ajr.144.6.1235>
 13. Joshi KS, Karki S, Regmi S, Joshi HN, Adhikari SP. Sonography in acute ureteric colic: an experience in Dhulikhel Hospital. *Kathmandu Univ Med J.* 2014;12(45):9–15. <http://dx.doi.org/10.3126/kumj.v12i1.13626>
 14. Ramakanthan D, Aiyappan SK, Karpagam B, Shanmugam V. Present role of grey scale Ultrasound comined with Doppler in the evaluation of uretric calculi: Correlation with CT scan. *Int J Anat Radiol Surg.* 2016;5(4):06-10.
 15. Heidenreich A, Desgrandschamps F, Terrier F. Modern approach of diagnosis and management of acute flank pain: review of all imaging modalities. *Eur Urol.* 2002;41(4):351–62. [http://dx.doi.org/10.1016/s0302-2838\(02\)00064-7](http://dx.doi.org/10.1016/s0302-2838(02)00064-7)