

Ishwor Raj Devkota
Dipendra Shrestha
Subash Khadka

Department of Otorhinolaryngology &
Head and Neck Surgery, Bir Hospital,
NAMS, Kathmandu, Nepal

Corresponding Author:

Dr. Ishwor Raj Devkota
Department of Otorhinolaryngology &
Head and Neck Surgery, Bir Hospital,
NAMS, Kathmandu, Nepal¹

E-mail: ishwor_142@hotmail.com

PRIMARY SQUAMOUS CELL CARCINOMA OF THYROID: A CASE REPORT

Background:

The thyroid gland lacks the squamous cell and the primary squamous cell carcinoma (SCC) of the thyroid gland is an uncommon malignancy with less than 1% of all thyroid malignancy with a very poor prognosis. So far few cases are reported in the literature with very low survival rates.

Case report:

A 60 years female presented with a rapidly enlarging right lobe of the thyroid with pain, dysphagia and hoarseness of two months duration. She had hard fixed 4cm x 4cm right lobe of thyroid with right vocal cord paralysis. Ultrasound demonstrates 36mm x 36mm right lobe with mixed echogenicity with calcifications. Fine needle aspiration cytology suggested anaplastic carcinoma. Computed tomography showed heterogeneously enhancing soft tissue density in the right lobe of the thyroid gland measuring 51mm x 37mm x 53mm with shifting of the trachea towards the left side with no significant cervical lymph nodes. CT chest, ultrasonography abdomen and pelvis did not reveal any primary lesion or other metastatic disease and stage was made as T4N0M0. Patient underwent total thyroidectomy with center neck clearance with temporary tracheostomy. Histopathology came out to be squamous cell carcinoma and patient was send for chemo-radiotherapy.

Conclusion:

Primary squamous cell carcinoma of thyroid is a rare and aggressive entity with poor prognosis. Fine needle aspiration cytology is effective confirmatory tool but efforts shall be made to rule out metastatic SCC originating from other sites. Surgery, radiotherapy and chemotherapy alone are ineffective. Aggressive treatment with surgery followed by adjuvant radiotherapy with or without chemotherapy is recommended to achieve better outcome.

Keywords: Primary, Squamous cell carcinoma, Thyroid

INTRODUCTION:

Thyroid gland lacks squamous epithelium; for the same reason the primary squamous cell carcinoma (SCC) of thyroid is extremely rare entity, seen only in less than 1% of all thyroid malignancies and it has a very high fatal course.¹ Patient usually die due to the respiratory obstruction either due to the direct invasion or due to the compression of the trachea.² Overall survival usually does not exceed 6 months after the time of diagnosis. It was first reported by von Karst in 1958.³ Since the primary squamous cell carcinoma of the thyroid gland is rare, the diagnosis should be made only after excluding the possibilities of invasion from the neighbouring organs (larynx, pharynx and oesophagus) or the metastasis from the distant organ likes lungs. There are several theories regarding the histogenesis of the squamous cell in the thyroid. Some authors believe the embryonic nest theory which suggests that squamous cells are derived from the embryonic remnants such thyroglossal duct, thymic epithelium and ultimobronchial body.⁴ Some authors put forward the metaplasia theory which suggests that the environmental stimuli (inflammation and Hashimoto's thyroiditis) result in squamous metaplasia.⁵ The de-differentiation theory suggests that existing papillary, follicular, medullary and anaplastic thyroid carcinoma de-differentiate into SCC.^{6,7} It has been reported that the primary SCC has an aggressive course and a poor prognosis. It has no significant response to the chemotherapy and radiotherapy.

CASE REPORT:

A 60 years old female patient visited our clinic due to rapidly increasing neck swelling for the past two months. She had hoarseness of voice and dysphagia for same

duration. She had no significant medical and surgical history in past. Her weight was stable, she was non-smoker and did not consume alcohol. On physical examination, her vital signs were stable. A fixed hard neck mass of about 4cm x 4cm was palpable in the right thyroid lobe. There was no palpable cervical lymphadenopathy, and examination of chest, heart, nervous system and abdomen was normal. The right vocal cord was fixed on both indirect laryngoscopy and flexible nasopharyngolaryngoscopy. The biochemical parameters were within normal range and patient was in euthyroid state. The ultrasonography showed enlarged right lobe of 36 mm x 36 mm size with distorted outline. There were multiple mixed echogenic nodules with largest measuring 27mm x 24mm with no increased vascularity with small calcified areas. The other lobe and isthmus were normal with no detectable cervical lymph nodes.

Fine needle aspiration cytology (FNAC) showed multinucleated atypical cells with squamoid appearing cells on the inflammatory background and a diagnosis of anaplastic carcinoma with Bethesda category VI was made. Contrast Enhanced Computed Tomography (CECT)(fig.1) of the neck and chest showed heterogeneously enhancing soft tissue density in the right lobe of the thyroid gland measuring 51mm x 37mm x 53mm. Multiple popcorn calcifications were noted with shifting of the trachea towards the left side with no significant cervical lymph nodes. CT chest, ultrasonography abdomen and pelvis did not reveal any primary lesion or other metastatic disease. Radiological stage was made as T4N0M0. The patient was scheduled for operation and underwent total thyroidectomy with central compartment neck clearance. The recurrent nerve

on the right side was involved by the tumor where as on the left was identified and preserved. There was extensive local invasion of tumor into strap muscle, carotid artery was abutted and trachea was shifted towards left with tracheomalacia on the 3rd and 4th tracheal ring. Temporary tracheostomy was done. The patient's hospitalization was uneventful and was discharged on the 10th postoperative day with removable of the tracheostomy tube. The histopathology reports (fig.2) demonstrated atypical cells arranged in the lobules and the nests separated by the fibrous septa infiltrating into the stroma. The individual cells were moderately pleomorphic with moderate amount of the eosinophilic cytoplasm, increased cytoplasmic ratio and atypical mitotic figures. Extensive areas of necrosis was noted, however, keratin pearls were not seen. There was no lymphovascular invasion but perineural invasion was present and margin was positive for the tumor cells. The lymph nodes were negative for the tumor cells. Moderately differentiated squamous cell carcinoma was made, however, cytokeratin analysis could not be made. On the basis of the above results, the patient was referred for further treatment to an oncology clinic. Patient was submitted to chemoradiotherapy. Patient was followed for 3 months with no recurrence but after that patient was lost to follow up.

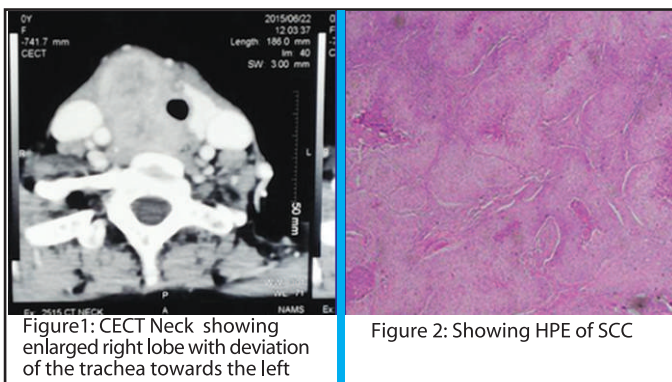


Figure 1: CECT Neck showing enlarged right lobe with deviation of the trachea towards the left

Figure 2: Showing HPE of SCC

DISCUSSION:

Primary SCC of the thyroid gland is an extremely rare and aggressive entity. It usually presents with a rapidly enlarging mass in the elderly individual mimicking the anaplastic carcinoma associated with the other thyroid swelling and histologically characterized by the intercellular bridges and keratin.^{8,10} It occurs with an advancing age and more common in females as in our case.¹¹ The tumor has a high rate of local infiltration and has a high incidence of the pressure symptoms like dysphagia and dyspnea. So surgical resection is less likely but can be carried out for debulking and obtaining tissue for the histological examination. In our case also, there was extensive local infiltration into the strap muscle and trachea. The primary SCC of thyroid presents as rapidly progressive mass as seen in our case but often it can be seen in long standing goiter as mentioned by Warren and Meissner.¹²

Carcinoma showing thymus-like elements (CASTLE) disease of the thyroid gland, anaplastic thyroid carcinoma and metastasis from adjacent organs should be considered in the differential diagnosis. Fine needle aspiration cytology (FNAC) is very useful tool for the diagnosis but the metastatic carcinoma should be ruled out before attributing the primary SCC of the thyroid gland. The differentiation can be further aided with the help of the cytokeratin (CK). The expression of the CK19 is high in the Primary SCC of the thyroid gland.¹³

Treatment of the SCC of thyroid is very challenging and single modality of treatment is not so efficacious. Multimodality treatment should be carried. Surgery alone with chemo-radiotherapy is usually carried out but often the tumor is surgically unresectable due to the local invasion. SCC of thyroid are radio-resistant and sole radiotherapy gives a poor prognosis.¹⁴ Chemotherapy with the anticancer drug has been explored but has a limited role. Harada et al found no impressive benefit from bleomycin nor with Adriamycin.¹⁵ Other chemotherapeutic agents like nitrogen mustard and vincristine were tried but shows no encouraging results.¹⁶ Post operative radiotherapy is usually given to prevent the recurrence but the results are still ambiguous. Since the primary SCC cases are less, the trials are not conclusive.

Recently Cho et al, performed a systematic review and individual participant data meta-analysis regarding primary SCC of the thyroid gland of 89 patients. The mean age of diagnosis was 63 years, a female preponderance (M:F=1:2) was noted and the anterior neck mass was the commonest complain. FNAC was accurate in less than one-third of the patients and more than half of cases had been diagnosed as papillary thyroid carcinoma. Complete surgical resection of the tumor was the only significant prognostic factor in multivariable analysis. The benefit of adjuvant treatment was not proved and the prognosis of these patients was very poor (only 20%, 3 year survival rate).¹⁷

CONCLUSION:

Primary squamous cell carcinoma of thyroid is a rare and aggressive entity with poor prognosis. FNAC is effective confirmatory tool, but efforts shall be made to rule out metastatic SCC originating from other sites. Aggressive treatment with surgery followed by adjuvant radiotherapy with or without chemotherapy is recommended to achieve better outcome.

REFERENCES:

1. Korovin GS, Cho HT, Kuriloff DB, Sobol SM. Squamous cell carcinoma of the thyroid: a diagnostic dilemma. *Ann Otol Rhinol Laryngol.* 1989;98: 59-65.
2. Simpson WJ, Carruthers TH. Squamous cell carcinoma of thyroid gland. *Am J Surg.* 1988;156: 44-6.
3. Sarda AK, Bal S, Arunabh, Singh MK, Kapur MM. Squamous Cell Carcinoma of the Thyroid. *Journal of Surgical Oncology.* 1988; 39: 175-178.
4. Goldberg HM, Harrey P. Squamous cell cysts of the thyroid with special reference to the etiology of squamous epithelium in the human thyroid. *Br J Surg.* 1956; 43:565-9.

5. Chaudhary RK, Barnes EL, Myers EN. Squamous cell carcinoma arising in Hashimoto's thyroiditis. *Head Neck*.1994; 16:582-5.
6. Bronner MP, LiVolsi VA. Spindle cell squamous carcinoma of the thyroid: an unusual anaplastic tumor associated with tall cell papillary carcinoma. *Mod Pathol*.1991; 4:630-43.
7. Kebapci N, Efe B, Kabukcuoglu S, Akalin A, Kebapci M: Diffuse sclerosing variant of papillary thyroid carcinoma with papillary squamous cell carcinoma. *J Endocr Invest*. 2002; 25:730-4.
8. Ko YS, Hwang TS, Han HS, Lim SD, Kim WS, Oh SY. Primary pure squamous cell carcinoma of the thyroid: report and histogenic consideration of a case involving a BRAF mutation. *Pathol Int*. 2012; 62:43-8.
9. Mercante G, Marchesi A, Covello R, Dainese L, Spiano G. Mixed squamous cell carcinoma and follicular carcinoma of the thyroid gland. *Auris Nasus Larynx*. 2011;8:1-5.
10. De Vos FY, Sewnaik A, de Witt JH, Smid EJ, den Bakker MA, van Meerten E. Combined therapy for thyroid squamous cell carcinoma. *Head Neck*. 2012;34:131-4.
11. Cook AM, Vini C, Harmer C. Squamous cell carcinoma of the thyroid: outcome of treatment in 16 patients. *Eur J Surg Oncol*.1999;25: 6069.
12. Warren S, Meissner WA. Tumors of the thyroid gland. *Atlas of Tumor Pathology*. Washington DC, Armed Forces Institute of Pathology, Sec. IV, Fasc.14.
13. Lam K-Y, Lo C-Y, Liu M-C. Primary squamous cell carcinoma of the thyroid gland: an entity with aggressive clinical behaviour and distinctive cytokeratin expression profiles. *Histopathology*.2001; 39:279-286.
14. Goldman RI. Primary squamous cell carcinoma of the thyroid gland: Report of a case and review of the literature. *Am Surg*. 1950;30: 247-52.
15. Harada T, Shimaoka K, Yakumaru K, Ito K. Squamous cell carcinoma of the thyroid gland: Transition from adenocarcinoma. *J Sur Oncol*. 1982; 19: 36-43.
16. Shimaoka K, Tsukada Y. Squamous cell carcinomas and adenosquamous carcinoma originating from the thyroid gland. *Cancer*. 1980; 46: 1833-42.
17. Cho JK, Woo SH, Park J, Kim MJ, Jeong HS. Primary squamous cell carcinomas in the thyroid gland: an individual participant data meta-analysis. *Cancer Med*. 2014;3(5):396-403.

