

# Pachydermoperiostosis (‘Touraine-Solente-Gole’ syndrome)

R. Sharma, S. Pandey, D. Choudhary<sup>1,2,3</sup> D.B. Pokhrel<sup>4</sup>

<sup>1,2,3</sup>Residents, Department of Dermatology, TUTH

<sup>4</sup>Professor and Head, Department of Dermatology, TUTH

Funding: None

Conflicts of interest: None

## Abstract

Inherited form of Pachydermoperiostosis (PDP), also known as ‘Touraine–Solente–Gole’ syndrome, is a familial disorder commonly inherited as an autosomal dominant trait with variable expression. It is manifested mainly by dermatological and rheumatological symptoms. The condition usually begins insidiously at puberty and is characterized by primary hypertrophic osteoarthropathy, cutis verticis gyrata, seborrhea, hyperhidrosis. There is also thickening of the ears, lips and the tongue. The distal lower extremities resemble those of an elephant, hence named as ‘Pachydermoperiostitis’. Non-steroidal anti-inflammatory drugs, steroids, colchicines, retinoids, plastic surgery have been utilized in case management.

**Keywords:** Pachydermia, primary hypertrophic osteoarthropathy, clubbing

Correspondence:

*Prof. D B Pokhrel*

Dept. of Dermatology, Institute of medicine

TUTH, Kathmandu, Nepal

E-mail: dbpokh@gmail.com

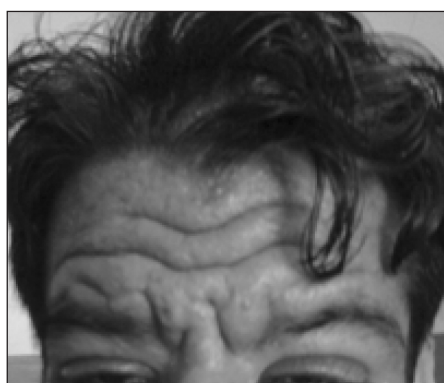
## Case Report

### Case Report:

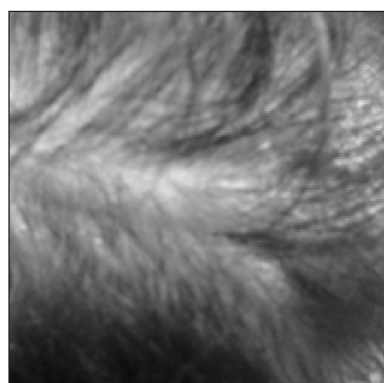A 24 years old male presented in the dermatology OPD with a 6 years history of thickening of skin over the face, scalp, hands, feet and legs. Furrowing of the skin over the face and scalp (Cutis verticis gyrata) (Figure 1 and 2). Painful swelling of hands, wrist, elbows, feet, ankles and knees associated with restriction of movement for the same duration. Swelling was initially noted over the ankles and feet with a gradual progression to involve the hands, wrists elbows and knees. Patient was a diagnosed case of hypothyroidism and was on oral thyroxine 0.1 mg daily which he had stopped taking for the past three months. Patient was also put on topical retinoic acid mixed

with clobetasol cream for local application for few months.

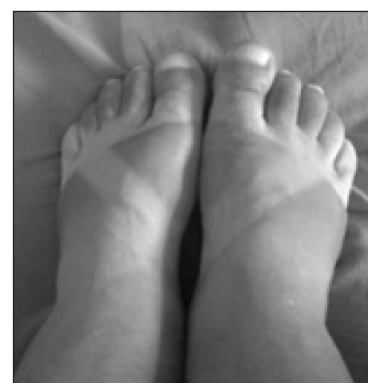There was no history of fever, weight loss, photosensitivity, oral ulcer, bleeding tendency. No history of cough, breathlessness, recurrent allergies, recurrent pneumonic infections, abdominal/ epigastric pain or urinary complaints. There was no history of genital discharge, genital ulcer and sexual contact. His father and grandfather suffered from chronic arthritis without a definite diagnosis. No other family members had similar illness. Family history of consanguinous marriage was not found. Patient was non alcoholic and non-smoker.



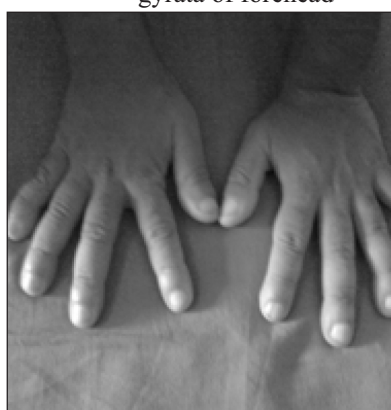**Figure 1:** Cutis verticis gyrata of forehead



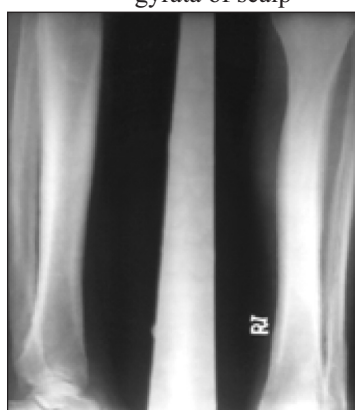**Figure 2:** Cutis verticis gyrata of scalp



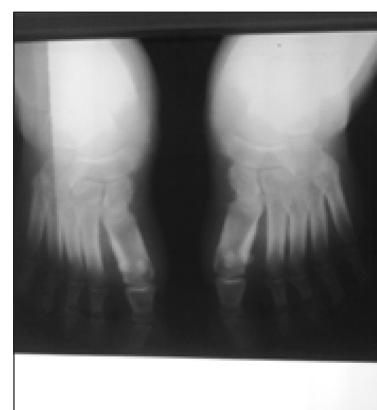**Figure 3:** Clubbing of toes



**Figure 4:** Clubbing of fingers



**Figure 5:** Subperiosteal ossification of long bones



**Figure 6:** Soft tissue swelling

On examination patient was 160 cms tall and 51 kg by weight with normal nutritional status. Lymph nodes were not enlarged. Clubbing was noted in all fingers and toes (Figure 3 and 4). Coarsening facial features due to thickened and furrowed greasy skin of the scalp and face was noted. Skin thickening was also prominent over

the hands, feet forearms and legs (Figure 3 and 4). Hypertrophy of eyelids with bilateral mechanical ptosis was present (Figure 1). Seborrhea was marked over scalp and face. Hyperhidrosis of palms and soles was seen. Musculoskeletal examination revealed 'spade' like hands and feet along with 'column' like

## Case Report

(cylindrical) forearm and legs. Other systemic examinations including ophthalmologic and neurologic systems were normal.

Initial laboratory examinations revealed; Hb-13.3 gm%, ESR -30mm in the 1<sup>st</sup> hour, total and differential counts were normal. Peripheral blood smear showed normal indices and morphology. Blood sugar levels (fasting and PP, HbA1c, GTT), serum sodium, potassium, calcium, phosphate were normal. Liver and renal function tests were normal. Growth hormone, T3, T4 and TSH were within normal limits. ANA and VDRL tests were negative. LH, FSH, Prolactin, Growth Hormone (HGH,ELISA), serum cortisol level were within normal limits. ACE level was normal. Skin biopsy revealed increased nonfibrous matrix in the dermis. Lymph node biopsy from left inguinal lymph nodes showed reactive lymphadenitis. X-ray of long bones, metatarsals, metacarpals and phalanges showed periostosis, subperiosteal ossification and soft tissue swelling (Figure 5 and 6). X-ray skull, lateral view showed a normal sella turcica. X-ray chest (PA) showed bifid right 3<sup>rd</sup> rib contour with normal lung fields. MRI (Brain) and USG (abdomen and pelvis) were normal.

Patient was on oral thyroxine 0.05 mg initially increasing to 0.1mg with regular TFT monitoring for the past 5 years and now has stopped taking the same. No other interventions regarding the skin manifestation were performed on the grounds that correction of the thyroid hormone levels might take care of the skin pathology. The definitive diagnosis of Pachydermoperiostosis was made on the basis of classical findings of arthralgia, finger clubbing and pachyderma. Patient was also sought orthopedic consultation for clubbing, arthralgia and osteoarthropathy and they also diagnosed it as Hypertrophic primary osteoarthropathy (HPOA) and advised for oral prednisolone in tapering doses. After making the definitive diagnosis in the department of Dermatology, the patient was put on oral Hydroxychloroquine 200mg BID, oral prednisolone 20mg OD, topical retinoid cream, topical sunscreen lotion, oral ranitidine 150mg

BID, oral calcium 500 mg OD and asked for regular follow-up.

## Discussion

Hypertrophic osteoarthropathy is divided into primary and secondary forms. Pachydermoperiostosis (PDP), the primary form, accounts for 5% of all cases of hypertrophic osteoarthropathy. It usually begins in late adolescence period after puberty. Skin and bone changes become progressively more severe for 5-10 years and then remain unchanged throughout life.

In contrast to the primary form, the acquired form is usually seen with Chronic pulmonary, mediastinal and cardiac diseases including malignancies and is associated with chronic hypoxia in peripheral tissues and is seen mostly in men over 40 years of age.

Three forms of pachydermoperiostosis (PDP) or primary hypertrophic osteoarthropathy have been described. They are: (a) Complete form with pachydermia and periostosis, (b) Incomplete form with evidence of bone abnormalities but lacking pachydermia, and (c) *Forme fruste* with prominent pachydermia and minimal-to-absent skeletal changes.<sup>1</sup>

More than 125 patients were described till 1988 and, at least, other 50 patients have been reported since 1990. Although the disease is not present with high frequency in the general population, the precise incidence and prevalence are still unknown. PDP occurs predominantly in men, who usually show a more severe phenotype.<sup>2</sup> PDP is often familial. It may affect several members of the same family. A familial history of PDP is found in 25-38% of patients. The genetic transmission is usually through a dominant autosomal gene with variable expression and penetrance. PDP has also been rarely described in consanguineous marriages with autosomal recessive transmission. Chromosomal abnormalities have been reported but no locus has been identified at this date. HLA-b12 has been found in 44% of 18 patients.<sup>3</sup>

## Case Report

Primary pachydermoperiostosis usually begins soon after puberty. The skin of the face, forehead and scalp becomes grossly thickened and thrown into folds. The folding of the scalp produces one of the forms of cutis verticis gyrata. Sebaceous activity is greatly increased on the face and scalp, and Hyperhidrosis of hands and feet may be troublesome. Eyelids (particularly upper), ears, lips are thickened and tongue is enlarged. Thickening of the phalanges and of the bones of the limbs produces spade-like hands and feet along the cylindrical arms and legs. The fingers and toes are clubbed. Skin and bone changes become progressively more severe for 5–10 years and then usually remain unchanged throughout life. Exceptionally, they may continue to progress and the degree of sebaceous hyperplasia may become extreme. Many patients are mentally retarded.<sup>4</sup> Rheumatologic features include arthritis, effusion, acro-osteolysis and periosteal ossification. Gynaecomastia, sparse facial and pubic hair may be present. Osteonecrosis of femoral head, carpal and tarsal tunnel syndrome, neurological symptoms due to compression of the spinal cord and the nerve roots can occur.<sup>3</sup> PDP may be associated with sacroiliitis, psoriasis, rheumatoid arthritis, duodenal ulcers, hypertrophic gastritis, gynecomastia, anemia, myelofibrosis, juvenile polyposis, gastric cancer, spondylolisthesis, and cutaneous squamous carcinomas.<sup>5</sup> Associations with Inflammatory bowel diseases esp. crohn's disease, papular mucinosis, pyoderma gangrenosum, multiple basal cell carcinomas, acromegaly have also been described.<sup>3</sup>

The pathogenesis of pachydermoperiostosis is still unclear. However, clubbing and hypertrophic osteoarthropathy are considered to be due to the peripheral impaction of megakaryocytes and platelet clumps in the tips of the digits. Several mediators are therefore released from platelets and megakaryocyte alpha granules, mainly platelet-derived growth factor (PDGF), but also transforming growth factor- $\beta$ , epidermal growth factor, prostaglandins and bradykinins. Interestingly, the release of PDGF results in activation of fibroblasts.<sup>6</sup> Proliferative periostitis

of the leg bones leads to diffuse irregular periosteal ossification, increasing the circumference of affected bones without increasing their length. The skin shows hypertrophy of collagen and of epidermis and epidermal appendages, and an increase of acid mucopolysaccharide.<sup>4</sup> Altered peripheral blood flow has been observed in patients with this disorder, producing capillary stasis, local hypoxia and collagen proliferation. The role of sex hormone steroid receptors and growth factor receptors has been studied in different proliferative and paraneoplastic syndromes. The presence of these receptors on different cell lines is well documented.<sup>7</sup> Differential diagnoses include variants of PDP, secondary hypertrophic osteoarthropathy, thyroid acropachy, acromegaly, van Buchem's disease (in which there is absence of clubbing and skin changes), diaphyseal dysplasia (endosteal and periosteal proliferation), and syphilitic periostosis. Variants of PDP include *Rosenfeld-Kloepfer syndrome*; *Currarino idiopathic osteoarthropathy* and a *localized form* with only the radiographic features of PDP in the lower extremities.<sup>8</sup> Basically the disease condition is a diagnosis of exclusion. Radiological and histopathological examination are important. In the greatest series of PDP there were no biological abnormalities. The osteocalcin blood level could be important to determine the degree of activity of the disease. Genetic counselling should be offered to patients with PDP and their families. Although no chromosomal abnormality has been identified, a radiologic survey of relatives may be completed.<sup>3</sup> NSAIDs (ibuprofen, indomethacin, celecoxib) may improve the joints symptoms, but not always. Colchicine in open cases and in a blind study improved the articular symptoms, the folliculitis and pachydermia after 15 days of treatment. It was supposed that colchicine inhibits the neutrophil chemotaxis, and reduces tissue oedema. Some joint effusions can be improved temporarily by intra-articular steroid injections. Rheumatologic symptoms have been improved by intra-venous treatment with Pamidronate. Isotretinoin at an initial dose of 0.5 mg/kg/day showed a dramatic improvement of the skin symptoms. Plastic surgery in the form of frontal rhytidectomy or

## Case Report

correction of ptosis may be helpful for complications on the face. Surgical reduction has been tried with some success in finger clubbing.<sup>3</sup>

### References:

1. Kudligi C, Bhagwat PV, Thirunavukkarasu A, Tophakhane RS. Incomplete pachydermoperiostosis. *Indian J Dermatol Venereol Leprol* 2010;76:307
2. Castori, M., Sinibaldi, L., Mingarelli, R., Lachman, R., Rimoin, D. and Dallapiccola, B. (2005), Pachydermoperiostosis: an update. *Clinical Genetics*, 68: 477–486.
3. Auger M, Stavrianeas N. pachydermoperiostosis. *Orphanet Encyclopedia*. April 2004: 1-8
4. Burns T, Breathnach S, Cox N, Griffiths C, editors. *Rook's Textbook of Dermatology*. 7th ed. London: Blackwell Science; 2004: 15.88-15.89
5. S. Ozmen, A. Tuzcu, C. Ozmen & M. Bahceci : A Case Of Pachydermoperiostosis And Overriding Forth Toes. *The Internet Journal of Rheumatology*. 2005; 2 (1): 1.
6. Bachmeyer, C., Blum, L., Cadranet, J.-F. and Delfraissy, J.-F. Myelofibrosis in a patient with pachydermoperiostosis. *Clinical and Experimental Dermatology*, 2005; 30: 646–48.
7. Bianchi L, Lubranoc, Carrozzo AM, Iraci S, Tomassoli M, Spera G et al. Pachydermoperiostosis: study of epidermal growth factor and steroid receptors, *British Journal of Dermatology* 1995; 132: 128-33.
8. Rastogi R, Suma GN et al. Pachydermoperiostosis or primary hypertrophic osteoarthropathy: A rare clinicoradiologic case, *Indian Journal of Radiology and Imaging* 2009;19(2): 123-26.