

# Tattoo Inoculated Cutaneous Tuberculosis: Case Report

Megha Tandon<sup>1</sup>

<sup>1</sup>Department of Dermatology, Jamuna Sewa Sadan Hospital and Research Centre, Varanasi, Uttar Pradesh, India

## Abstract

Tattooing is an ancient custom that has been popular for ornamental, religious and traditional purposes in various countries and cultures since time immemorial. The surge in cases of tattoo associated adverse reactions is an alarming situation especially with this increasing trend of tattooing for cosmetic purposes among the youth. Tattoo-associated tuberculous and nontuberculous mycobacterial skin infections have been reported uncommonly in literature. Here an occurrence of tattoo inoculated cutaneous tuberculosis presenting as lupus vulgaris developing to red ink tattoo in a young male is reported who responded to standard antitubercular therapy.

**Key words:** Inoculation; Lupus Vulgaris; Tattooing; Tuberculosis

## Introduction:

Tattooing is an ancient custom that has been popular for ornamental, religious and traditional purposes in various countries and cultures since time immemorial.<sup>1</sup> According to the placement, the tattoos can be professional or amateur.<sup>2</sup>

The surge in cases of tattoo associated adverse reactions is an alarming situation especially with this increasing trend of tattooing for cosmetic purposes among the youth. The metallic salts used in the preparation of the pigment of tattoo ink has been attributed to be the most common cause of cutaneous reactions to tattoos. Allergic reactions to a particular pigment can manifest in several ways including allergic contact dermatitis and photo-allergic dermatitis. Tattoo-associated tuberculous and nontuberculous mycobacterial skin infections have been reported uncommonly in literature.<sup>3-8</sup> Here an occurrence of tattoo inoculated cutaneous tuberculosis presenting as lupus vulgaris developing to red ink tattoo in a young male is reported who responded to standard antitubercular therapy.

## Case report:

A 29-year-old man reported complaints of reddish swelling over the tattoo site for 8 months. The tattoo was put about 12 months back in a local tattoo parlor and after 4 months he developed redness and swelling over the tattoo which gradually progressed

to involve the whole tattoo site. No other significant complaints in either the patient or in any other family members were found. On examination, a scaly, erythematous plaque confined to the pigment margins of the tattoo, over the ventral aspect of the right forearm was seen (Figure-1). The centre of the plaque showed atrophy and minimal scaling. There was no lymphadenopathy and his systemic examination was unremarkable. The possibilities of tattoo inoculated lupus vulgaris, tattoo sarcoidosis, tattoo granuloma and subcutaneous mycosis were considered. Chest X-Ray, serum angiotensin-converting enzyme (SACE) levels and ultrasonography of the abdomen were normal. Erythrocyte sedimentation rate (ESR) was found to be elevated and Mantoux test revealed an induration of 15 mm after 2 days. Histopathology showed mild thinning of epidermis and dermis showed diffuse infiltration of inflammatory cells comprising of lymphocytes, few polymorphs and histiocytes interspersed with thin walled blood vessels with plump endothelium (Figure-2a and b). No organisms were revealed on examination of Periodic acid-Schiff (PAS) stained slides. Based on clinical presentation and investigations, a presumptive diagnosis of lupus vulgaris was made. After 6 months

**Date of Submission:** 31<sup>st</sup> March 2023

**Date of Acceptance:** 25<sup>th</sup> August 2023

**Date of Publication:** 1<sup>st</sup> October 2023

## How to cite this article

Tandon M. Tattoo Inoculated Cutaneous Tuberculosis: Case Report. NJDVL 2023;21(2): 32-34. <https://doi.org/10.3126/njdvl.v21i2.53694>



Licensed under CC BY 4.0 International License which permits use, distribution and reproduction in any medium, provided the original work is properly cited.

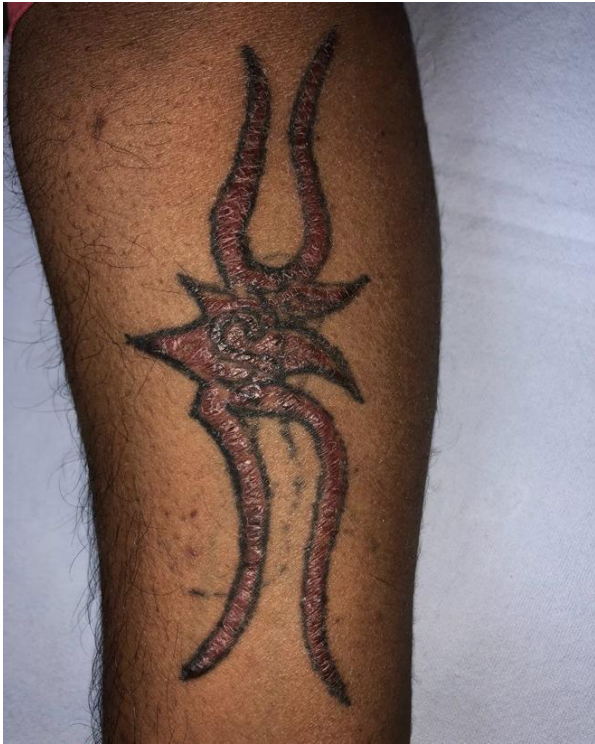**Funding:** None

**Conflict of Interest:** None

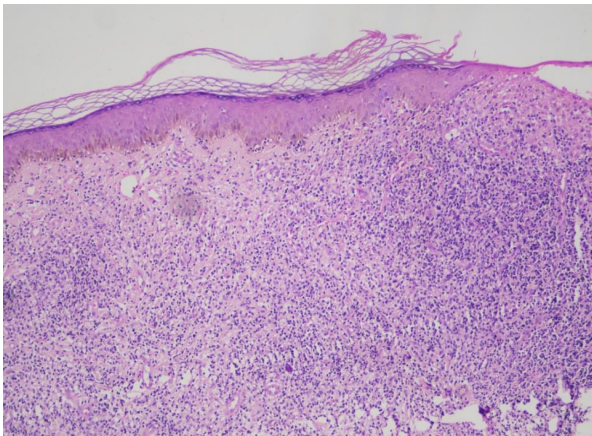
## Corresponding Author:

Dr. Megha Tandon  
Department of Dermatology, Jamuna Sewa Sadan Hospital and Research Centre, Varanasi, Uttar Pradesh, India  
ORCID ID: 0000-0002-0886-4730  
Email: [tan.megha1993@gmail.com](mailto:tan.megha1993@gmail.com)

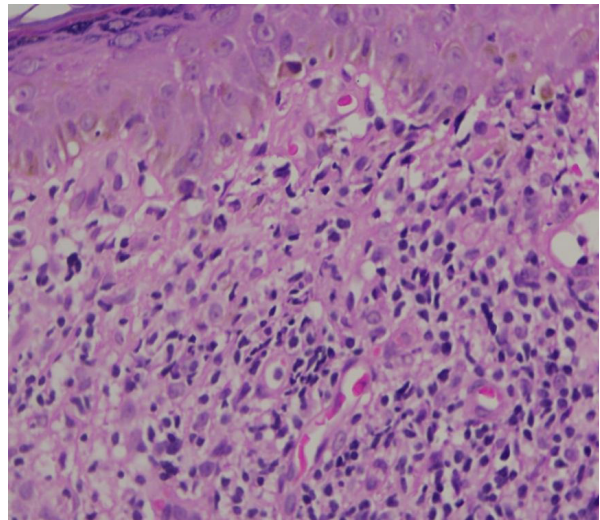
of starting antitubercular therapy category-I by the department of Revised National TB Control Programme (RNTCP) comprising rifampicin, isoniazid, ethambutol and pyrazinamide, clinical improvement was seen with resolution of the erythematous plaque (Figure-3). Rifampicin, isoniazid, ethambutol and pyrazinamide were given for the first 2 months followed by rifampicin and isoniazid for 4 months.



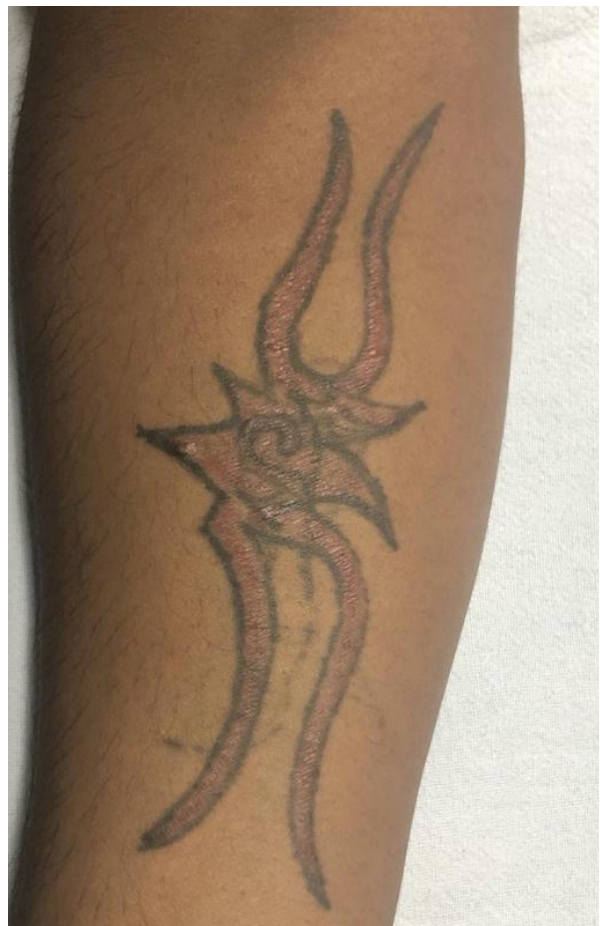**Figure-1:** Erythematous plaque with atrophy and scaling over the tattoo confined to margin



**Figure-2a:** Histopathology showing mild thinning of epidermis and dermis showed diffuse infiltration of inflammatory cells comprising of lymphocytes, few polymorphs and histiocytes interspersed with thin walled blood vessels with plump endothelium (H and E, x40)



**Figure-2b:** Inset showing widespread presence of inflammatory cells consisting of lymphocytes, a small number of polymorphs, and histiocytes scattered among delicate blood vessels that have swollen endothelial linings (H and E x400)



**Figure-3:** Clinical improvement of lesion after 6 months of anti-tubercular treatment

**Discussion:**

Various infective and non-infective dermatoses are being encountered in clinical dermatological practice due to unregulated practices and variability in ink composition. Three main categories of tattoo reactions are inflammatory, infectious, and neoplastic. Tattooing associated infective disorders include hepatitis B, hepatitis C, HIV, leprosy, molluscum contagiosum, syphilis, viral warts and those caused by methicillin-resistant *Staphylococcus aureus* (MRSA).<sup>9-11</sup> Unhygienic practices like sharing the same needle and ink and dilution of ink with mycobacteria harboring tap water or saliva and disruption of skin barrier are factors implicated in the pathogenesis of tattoo inoculation tuberculosis. The most common form of cutaneous tuberculosis in India is Lupus vulgaris. Lupus vulgaris may arise within old scars, at the site of BCG (*Bacillus Calmette–Guérin*) vaccination and it can also occur after exogenous inoculation. In 2015, tattoo inoculated lupus vulgaris was reported by Dhawan et al in two

brothers 3 months after tattooing.<sup>3</sup> Rai et al have reported lupus vulgaris over a tattoo mark in an 18 year old male after 4 months of tattooing.<sup>4</sup> Three cases of cutaneous tuberculosis wherein the patients developed multiple papules and plaques overlying and extending beyond the tattoo site have been reported by Ghorpade in 2006.<sup>5</sup> Recently, cases of cutaneous nontuberculous mycobacterial infections over the tattoo site by *Mycobacterium haemophilum*, *Mycobacterium fortuitum* and *Mycobacterium chelonae* have been reported in literature.<sup>6-8</sup> The diagnosis of lupus vulgaris is made on clinical and histopathological grounds. However, in the present case, the granulomas have been masked by the tattoo evoked dense inflammatory reaction comprising of lymphocytes, few polymorphs and histiocytes interspersed with thin walled blood vessels with plump endothelium.

There is a need to create awareness regarding risks and complications of invasive procedures associated with body art among the dermatologists, body art practitioners as well as their clients in order to prevent hazards of body art.

**References**

1. LeBlanc PM, Hollinger KA, Klontz KC. Tattoo ink-related infections--awareness, diagnosis, reporting, and prevention. *N Engl J Med*. 2012 Sep 13;367(11):985-7. <https://doi.org/10.1056/NEJMp1206063>
2. Goldstein N. Tattoos defined. *Clin Dermatol*. 2007 Jul-Aug;25(4):417-20. <https://doi.org/10.1016/j.clindermatol.2007.05.015>
3. Dhawan AK, Pandhi D, Wadhwa N, Singal A. Tattoo inoculation lupus vulgaris in two brothers. *Indian J Dermatol Venereol Leprol*. 2015 Sep-Oct;81(5):516-8. <https://doi.org/10.4103/0378-6323.158658>
4. Rai, Tulika & Meena, Rakesh. (2018). Tattoo: inoculating lupus vulgaris. *International Journal of Research in Dermatology*.4.453.10.18203/issn.2455-4529.IntJResDermatol20183177.
5. Ghorpade A. Tattoo inoculation lupus vulgaris in two Indian ladies. *J Eur Acad Dermatol Venereol*. 2006 Apr;20(4):476-7. <https://doi.org/10.1111/j.1468-3083.2006.01471.x>
6. Tattoo-associated nontuberculous mycobacterial skin infections-multiple states, 2011-2012. Centers for Disease Control and Prevention (CDC). *MMWR Morb Mortal Wkly Rep* 2012;61:653-6.
7. Giulieri S, Cavassini M, Jaton K. Mycobacterium chelonae illnesses associated with tattoo ink. *N Engl J Med*. 2012 Dec 13;367(24):2357; author reply 2357-8. <https://doi.org/10.1056/NEJMc1212350>
8. Philips RC, Hunter-Ellul LA, Martin JE, Wilkerson MG. Mycobacterium fortuitum infection arising in a new tattoo. *Dermatol Online J*. 2014 Jun 15;20(6):13030/qt6bs3q0h0.
9. Jacob CI. Tattoo-associated dermatoses: a case report and review of the literature. *Dermatol Surg*. 2002 Oct;28(10):962-5 <https://doi.org/10.1046/j.1524-4725.2002.02066.x>
10. Molina L, Romiti R. Molluscum contagiosum on tattoo. *An Bras Dermatol*. 2011 Mar-Apr;86(2):352-4. English, Portuguese. doi:10.1590/s0365-05962011000200022.
11. Horney DA, Gaither JM, Lauer R, Norins AL, Mathur PN. Cutaneous inoculation tuberculosis secondary to 'jailhouse tattooing'. *Arch Dermatol*. 1985 May;121(5):648-50.