

DOI: <https://doi.org/10.3126/njdvl.v20i1.39345>

Cutaneous Pili Migrans: A rare case from North India

Ipshta Bhattacharya¹, Tapan Dhali², Paschal Dsouza³, Vishnu Choudhary⁴

^{1,2,3}Department of Dermatology, Venereology, and Leprosy, PGIMSR & ESI Model Hospital, Basaidarapur, New Delhi, India; ⁴Department of Dermatology, Brijesh banger Memorial Hospital, Bhilwara, Rajasthan, India.

Abstract

Cutaneous Pili Migrans (CPM) is a rare creeping eruption with only 40 cases reported so far. CPM is defined as a condition where a hair shaft or fragments gets embedded in superficial skin. It is known to affect both adults and children. We report a 23-year-old male patient who presented with sudden sharp pain in the foot on walking. Cutaneous examination revealed a black linear thread-like lesion on the medial plantar aspect of the right great toe associated with mild to moderate tenderness. The particle was removed by superficial paring along with gentle forceps extraction. Microscopic examination confirmed it to be a hair shaft fragment. While the exact etiology of CPM is unclear, it is proposed to be an acquired condition. Since it can mimic other creeping eruptions like Larva migrans, it is important to be aware of this condition.

Key words: Creeping Eruption; Cutaneous Pili Migrans; Hair Splinter; Trichology

Introduction

Cutaneous Pili Migrans (CPM) is a creeping eruption due to hair shaft/fragment embedded in superficial skin or dermis which manifests as an actively linear or serpiginous cutaneous track with slightly elevated erythema.¹

Asians are predisposed as Asian hair has higher tensile strength and can be bent to great degrees without sustaining fractures.² This, coupled with the fact that CLM is a differential, makes it important to know about this condition, specifically in the Indian context.

Case Report

A 23-year-old male presented with sudden sharp pain in the right great toe on walking for 3 days. Recently he noticed a black, curved, thread-like mark on his toe, which appeared to be under the skin (Figure 1). There was no history of trauma.

Funding: None

Conflict of Interest: None

Address of Correspondence

Dr. Tapan Kumar Dhali

ORCID ID; 0000-0003-0378-9003

Professor, Department of Dermatology, Venereology, and Leprosy, PGIMSR & ESI Model Hospital, Basaidarapur, New Delhi

E-mail: tapan99@gmail.com

On examination, there was a black, semi-circular thread-like lesion on the medial border of the plantar aspect of the right great toe, associated with mild to moderate tenderness. An erythematous zone surrounded the advancing edge of the dark line.

The patient was subjected to superficial paring, and gentle extraction with forceps revealed a straight, linear, black strand, around 1.5cm in length. Microscopic examination of the extracted foreign body strand using Dinolite AMZT73915 showed a hair shaft with a sharp end lacking the hair follicle. The hair shaft diameter was 0.086mm (Figure 2). On follow-up after 1 month, the patient was asymptomatic and cutaneous examination was unremarkable

Submitted: 25th August, 2021

Accepted: 30th November, 2022

Published: 1st April 2022

How to cite this article

Bhattacharya I, Dhali T, Dsouza P, Choudhary V. Cutaneous Pili Migrans: A rare case from North India. NJDVL 2022;20(1):41-3. <https://doi.org/10.3126/njdvl.v20i1.39345>.



Licensed under CC BY 4.0 International License which permits use, distribution and reproduction in any medium, provided the original work is properly cited.

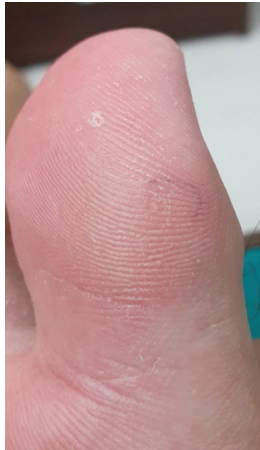

Figure 1: Black, semi-circular thread-like lesion on medial plantar aspect of right great toe




Figure 2: Microscopic examination (60x) showing naked hair shaft of 0.086mm diameter with sharp end

Discussion

The consequences of the embedded hair shaft in the form of reactive hyperkeratosis and interdigital pilonidal sinuses seen in hairdressers were first reported as far back as 1954.^{3,4} In 1957, Howard Yaffee reported the first case of CPM and likened the clinical presentation to larva migrans.⁵ In 2001, Thai and Sinclair reported case of a 37-year-old Indian-origin man having a 7-cm long submerged, migrating hair and formally called the entity 'Cutaneous Pili Migrans'.⁶

As noted by Luo et al., the absence of hair follicles implies an acquired etiology.¹ Disorders like Pseudofolliculitis barbae are known to be highly inflammatory owing to the presence of foreign body as well as secondary infection. When associated with infection, embedded hair is also known to trigger foreign body reaction and inflammation, consequently leading to sinus formation.⁵ Interdigital trichogranulomas or sinuses seen in hair dressers are one such form. However, CPM is also due to a foreign body, but demonstrates a relative lack of inflammation, which is postulated to be due to multiple factors like absence of secondary infection and lack of Langerhans cells in superficial layers of the epidermis.^{6,7}

Till date, less than 40 cases have been reported worldwide, possibly due to its rare occurrence and asymptomatic nature.⁸

Predisposing factors for CPM include friction, wet feet or walking in waterlogged areas, contact with pets, and walking over recently clipped hair (like after haircuts). Hairdressers, barbers, and dog groomers or handlers are more at risk.^{1,5,9}

CPM can affect people of all ages. Common sites include ankle, sole, toe, breast, cheek or neck, and abdomen.^{1,9} Histopathology is usually not required, but shows cross-sectioned hair fragment or compact keratin in a tiny empty space in the superficial dermis.^{9,10}

A close differential is cutaneous larva migrans (CLM), and the differences have been tabulated. (Table 1)

Table 1: Differentiating features between CPM) and CLM

	Cutis Pili Migrans (CPM)	Cutaneous Larva Migrans (CLM)
Movement	One direction (in linear fashion)	Any direction
Tracts	Less serpiginous or torturous	More serpiginous or torturous
Itching	± (usually asymptomatic, can be painful)	+++ (severely itchy)

As noted by Luo et al, the absence of hair follicle implies an acquired etiology.¹ The lack of inflammation is also attributable to the relatively short time that the hair has been embedded for and the lack of Langerhans cells in superficial layers of the epidermis.¹⁰

Embedded hair can trigger foreign body reaction, leading to the formation of epithelioid tracts around hair shaft, further leading to secondary infection, inflammation, and formation of branching sinuses.⁵ Interdigital trichogranulomas or sinuses, thus formed, were initially considered an occupational disorder more common among hairdressers.¹⁰

Conclusion

In conclusion, CPM is a rare, creeping eruption that occurs more commonly in Asians and people of ethnic background. It can be easily diagnosed based on a thorough history and examination. Extraction by forceps provides immediate relief. Differentiation from Cutaneous Larva Migrans is important, specially in the Indian setting.

References

1. Luo DQ, Liu JH, Huang YB, He DY, Zhang HY. Cutaneous pili migrans: a case report and review of the literature. *Int J Dermatol.* 2009;48(9):947-50. <https://doi.org/10.1111/j.1365-4632.2009.04118.x>
2. Franbourg A, Hallegot P, Baltenneck F, Toutaina C, Leroy F. Current research on ethnic hair. *J Am Acad Dermatol.* 2003;48:S115-9. <https://doi.org/10.1067/mjd.2003.277>
3. Pratt, A. G. Hyperkeratosis of Heel Caused by Foreign Body (Hair). *AMA Arch Derm.* 1956;74(5):469-70. <https://doi.org/10.1001/archderm.1956.01550110013005>
4. Joseph HL, Gifford H. Barber's Interdigital Pilonidal Sinus, *AMA Arch Derm Syph.* 1954;70(5):616-24. <https://doi.org/10.1001/archderm.1954.01540230066008>
5. Yaffee HS. Imbedded hair resembling larva migrans. *AMA Arch Derm.* 1957;76(2):254. <https://doi.org/10.1001/archderm.1957.01550200098027>
6. Thai KE, Sinclair RD. Cutaneous pili migrans. *Br J Dermatol.* 2001;144(1):219. <https://doi.org/10.1111/j.1365-2133.2001.03998.x>
7. Neri I, Bianchi F, Medri M, Bardazzi F. Cutaneous pili migrans in a 3-year-old child. *Pediatr Dermatol.* 2004;21(5):612-3. <https://doi.org/10.1111/j.0736-8046.2004.21522>
8. Ingkapiroj K, Triwongwaranat D, Jiamton S, Varothai S. Cutaneous Pili Migrans: A Case Report. *Skin Appendage Disord.* 2020;6(1):52-4. <https://doi.org/10.1159/000504234>
9. Kim YH, Kim JI, Hwang SH, Min JH, Chae SW, Lee SJ et al. Cutaneous pili migrans. *Ann Dermatol.* 2014;26(4):534. <https://doi.org/10.5021/ad.2014.26.4.534>
10. Nagar R, Khare S. Cutaneous pili migrans over the scalp of an infant. *Indian J Paediatr Dermatol.* 2016;17(1):27. <https://doi.org/10.4103/2319-7250.173156>