

Cutaneous Leukocytoclastic Vasculitis in Jose R. Reyes Memorial Medical Center: A 12 year Retrospective Study

Bajracharya S¹, Ismael DK², Venida MLA²

¹Resident, Department of Dermatology, Jose R. Reyes Memorial Medical Center,² Consultant staff, Department of Dermatology, Jose R. Reyes Memorial Medical Center

Abstract

Introduction: Leukocytoclastic vasculitis (LCV) is the commonest vasculitis of skin affecting small vessels.

Objectives: To study epidemiology, etiology, clinical and laboratory features and treatment outcomes in LCV patients.

Material and methods: This is a Hospital based retrospective analytical study where cases with histological evidence of LCV were collected from pathology database since January 2000 to December 2011. Records were analyzed for variables, clinical features, etiological factors, laboratory results, and treatment outcome.

Results: Of total 98 cases, 70 (71.43%) were Female and 28(28.57%) Male. Mean age was 28.35 years (range 1 to 71 years). Palpable purpura was commonest presentation (74.49%) involving mostly lower limbs (91.84%). Commonest symptom was abdominal pain (27.55%), followed by arthralgia (25.51%) and pruritus (24.49%). Majority of cases had unknown etiology (69.07%). Those with documented etiology included infection (25.51%) and drugs (5.10%). Leukocytosis was commonest laboratory abnormality. Forty one percentage of patients had complete remission, 33% improved, 2 % deteriorated and 24% were lost to follow up.

Conclusion: Females were more affected. Palpable purpura in lower limb was commonest presentation. Majority were idiopathic LCV. Amoxicillin and UTI were commonest among causes of drugs and infection, respectively. Commonest abnormality was leukocytosis. The majority of the cases improved with therapy.

Key words: Leukocytoclastic vasculitis, Palpable purpura, Henoch-Schönlein purpura, Hypersensitivity vasculitis

Introduction

Vasculitis is defined as an inflammation of the blood vessel wall, which may occur in association with a wide spectrum of systemic inflammatory conditions, malignancies, precipitated by infections, drugs or may be idiopathic.¹⁻³ Vasculitis has been classified based on vessel size (large, medium and small-sized vessels), severity of disease (cutaneous or systemic), clinical signs and symptoms in conjunction with histopathologic features (American College of Rheumatology criteria), histopathologic features only (Chapel Hill Consensus Conference), and primary (idiopathic) versus secondary disease.²

Leukocytoclastic vasculitis (LCV) is a reaction pattern of small dermal vessels, almost exclusively postcapillary venules, characterized by a combination

of vascular damage and an infiltrate composed largely of neutrophils, as well as fragmentation of nuclei (karyorrhexis or leukocytoclasia). The pathophysiology of vascular injury may involve

- the deposition of immune complexes,
- direct binding of antibodies to antigens in vessel walls, and
- activation of leukocytes by antibodies with specificity for leukocyte antigens (ANCA).⁴

Deposition is facilitated when the vessels are dilated and flow velocity is reduced. This explains the predilection of LCV for the dependent parts of the body (e.g. the lower leg).⁵

If IgA is primarily involved, there is often systemic involvement and the illness is referred to as Henoch-Schönlein purpura (HSP), which mainly affects children. Renal involvement is one of the main causes of morbidity in HSP.⁵ Hypersensitivity vasculitis (HV) describes patients with small vessel vasculitis resulting from drug exposure.¹ *Erythema elevatum diutinum* (EED) is a chronic, recurrent cutaneous vasculitis that usually occurs in connection with

Address for correspondence

Dr. Shirapa Bajracharya
Consultant Dermatologist
Capital Hospital Pvt.Ltd, Putalisadak, Kathmandu, Nepal
Ph. No: 9851199958
E-mail: shirapa@gmail.com

autoimmune illnesses, infections (e.g., HIV), or hematological diseases. The reason for the chronicity of the lesions, which often last for 10 to 30 years, has not been explained precisely and its pathogenesis is also unknown.⁵ In urticarial vasculitis, the duration of lesions is longer than 24 hours, there is presence of purpura and post inflammatory pigmentation, and symptoms of burning rather than itching as in urticaria.¹

LCV most often manifests clinically as dependent palpable purpura distributed symmetrically. They may occur anywhere, but are most commonly found on dependent areas such as the lower legs.^{2,6} It is associated with the following conditions: idiopathic (45%-55%), infection (15%-20%), inflammatory disease (15%-20%), drug intake (10%-15%), and malignancy (<5%).²

The first line of therapy for LCV is to eliminate eliciting infectious agents, drugs or food or treat the underlying diseases. Medications include antihistamines, corticosteroids, colchicines, dapsone and pentoxifylline.⁴

To date, there is no study investigating cutaneous vasculitis at length in our institution. Therefore, a retrospective study was conducted to determine the demographics, incidence, clinical features, possible underlying etiologies, laboratory abnormalities, management and outcomes of histologically diagnosed cases of LCV at the department of Dermatology, Jose R. Reyes Memorial Medical Center (JRRMMC).

Objectives

General Objective

This study aims to determine the incidence and clinical profiles of patients diagnosed with LCV in a 12 year retrospective review at the department of Dermatology of JRRMMC from January 2000 to December 2012.

Specific Objectives

1. To determine the demographic profiles of patients histologically diagnosed with LCV.
2. To determine the incidence, common clinical features, possible underlying etiologies and common laboratory abnormalities of patients with LCV.
3. To determine the management and outcome of these patients.

Material and methods

All histopathologically diagnosed cases of LCV from January 2000 to December 2012 in department of

Dermatology, JRRMMC were included. All patients with incomplete or missing charts and those without histologic confirmation were excluded.

Records or charts of all patients histologically diagnosed with LCV from January 2000 to December 2012 were retrieved and reviewed. Only the patients with confirmed biopsies were included. As stated in the chart, demographic profile, medical data such as clinical diagnosis, accompanying symptoms, location and distribution of lesions, duration of disease, laboratory results if any, possible etiologies, treatments and outcomes were recorded in the data sheet. Patients were considered as having extracutaneous end organ involvement based on evidence from clinical assessment, biochemistry or radiology. Renal involvement was defined as presence of persistent glomerular hematuria and/or proteinuria. Patients were considered to have renal impairment if their serum creatinine level was more than the upper limit of normal. Clinical course was divided into acute (less than 3 months) and chronic (prolonged course of at least 3 months or at least two recurrent episodes) at the time of consultation.⁹ Overall cumulative incidence was also computed. The statistical analysis was done by calculation of mean and standard deviation.

Results

One hundred fifty-seven cases of LCV were documented in the pathology database at the JRRMMC department of Dermatology from January 2000 to December 2011. Histopathological diagnosis of LCV was made based on the following characteristics: fibrinoid necrosis of vessels, neutrophilic infiltration of vessel walls, perivascular neutrophils, leukocytoclasia, red blood cell extravasation and fibrin thrombus.⁴ Only 98 charts fit the inclusion criteria. The unavailable charts were not included in this study.

Demographic data

The mean age of patients histologically diagnosed with LCV was 28.35 ± 16.79 years, with ages ranging from 1 to 74 years old. Majority of the patients were at the second decade of life (Table 1). Seventy (71.43%) of the patients were females and 28 (28.57%) were males. Females were more affected than males in all age groups (Table 1).

Clinical presentation

Palpable purpura was the most common presenting lesion (73/98, 74.49%) (Figure 1). The lesions most commonly affected the lower limbs (90/98, 91.84%),

with 60 patients (61.22%) having lesions isolated exclusively to the lower limbs. (Table 2). Sixty-eight patients (69.39%) had accompanying systemic symptoms, the most common of which was abdominal pain (27.55%) (Table 3).

The average duration of the LCV when patients were first seen was 12.26 ± 23.28 weeks, ranging from 2 to 192 weeks. Most cases (75/98, 76.53%) presented acutely (< 3 months) (Figure 2).

Incidence

The cumulative incidence rate in 12 years was 0.024% (98 new histologically diagnosed cases of LCV / 399,295 new cases seen at the department of Dermatology).

Clinical diagnosis and etiologies

The majority of patients (53/98, 54.08%) were clinically diagnosed simply as vasculitis (Table 4). Majority of the cases 67/98 (69.07%) were idiopathic. Infection was the next most common cause 25/98 (25.51%), and UTI (15/98, 15.30%) was the most frequent infection. Other possible etiologies of LCV in our patient population are presented in Table 5.

Laboratory workups

Laboratory tests were done by 59% (58/98) of the total patient population. The most common laboratory abnormality was leukocytosis (21.43%) (Figure 3). In cases with abnormal urinalysis (19/98, 19.39%), UTI was the most common documented finding (17/98, 17.35%).

Based on the criteria for systemic involvement² abovementioned in the Methodology section, systemic involvement was detected in eight patients (8.16%), four each in cases diagnosed with Henoch–Schönlein purpura and hypersensitivity vasculitis. Renal involvement was the most common (4/98, 4.08%).

One of the patients with deranged renal function also had abnormal creatinine levels, gastrointestinal and neurological manifestations.

Treatment

Oral prednisone was the most commonly used first-line medication (42/98, 42.86%), followed by topical steroids and colchicine (Figure 4). Fluoroquinolones were the most commonly used antibiotics (11/98, 11.22%), followed by amoxicillin-clavulanate (4/98, 4.08%), macrolides and cephalosporins (2/98, 2.04%), and penicillin V (1/98, 1.02%). Adjunctive medications included antihistamines (51/98, 52.04%), vitamin C (22, 22.45%) and NSAIDs (12/98, 12.24%).

Outcomes

Majority of the patients improved with therapy (64%), and 10% of the patients resolving spontaneously without any treatment. There were no deaths (Figure 5).

Four (4.08%) patients were admitted. The mean hospital duration among admitted in the group is 6.25 ± 4.57 days, ranging from 3 to 13 days. Of the admitted cases, 3 resolved upon discharge and one patient's condition had deteriorated and had left against medical advice. This patient was diagnosed with acute renal failure probably secondary to intra-renal toxic injury, hepatic encephalopathy stage I, alcoholic liver disease, congestive heart failure and was considered to have hepatorenal syndrome.

Even though treatment with oral steroids produced the highest cure rate, it also had an equivalent high failure rate. Topical steroids had the highest rate of non-improvement (Table 6).

There is no correlation between surface area involvement and outcome. All five cases with a generalized presentation had an acute course and 4 cases subsequently resolved with treatment.

Table 1: Distribution of age and gender in cases histologically diagnosed with LCV

Age range in years	Female (n, %)	Male (n, %)	Total (n, %)
0-10	6 (6.12%)	5 (5.10%)	11 (11.22%)
11-20	17 (17.34%)	13 (13.27%)	30 (30.16%)
21-30	18 (18.37%)	2 (2.04%)	20 (20.41%)
31-40	9 (9.18%)	4 (4.8%)	13 (13.27%)
41-50	10 (10.20%)	3 (3.06%)	13 (13.27%)
51-60	6 (6.12%)	1 (1.02%)	7 (7.14%)
61-70	2 (2.04%)	0 (0%)	2 (2.04%)
71-80	2 (2.04%)	0 (0%)	2 (2.04%)
Total	70 (71.43%)	28 (28.57%)	98 (100%)

Table 2: Distribution of lesions in cases histologically diagnosed with LCV

Distribution	Number	Percent (%)
Generalized	5	5.10
Lower Limbs	60	61.22
Lower Limbs/Gluteal	2	2.04
Lower Limbs/Trunk	2	2.04
Lower Limbs/Upper limbs	16	16.33
Lower Limbs/Upper limbs/Gluteal	2	2.04
Lower Limbs/Upper limbs/Trunk	7	7.14
Lower Limbs/Upper limbs/Trunk/Gluteal	1	1.02
Upper limbs	3	3.06
Total	98	100.00

Table 3: Accompanying symptoms seen in cases histologically diagnosed with LCV

Accompanying symptoms	Number	Frequency
Abdominal pain	27	27.55%
Arthritis/Arthralgias	25	25.51%
Pruritus	24	24.49%
Cough	17	17.35%
Fever	11	11.22%
Myalgias	10	10.20%
Vomiting	7	7.14%
Hematuria	6	6.12%
Edema	5	5.10%
Weakness	3	3.06%
Diarrhea	3	3.06%
Burning sensation	2	2.04%
Burning micturation	2	2.04%
Weight loss	0	

Table 4: Clinical diagnoses of cases histologically diagnosed with LCV from January 2000 – December 2012

Clinical diagnosis	Number (%)
Vasculitis	53 (54.08%)
Henoch-Schonlein purpura	25 (25.51%)
Hypersensitivity Vasculitis	11 (11.22%)
LCV	6 (6.12%)
Urticarial Vasculitis	2 (2.04%)
<i>Erythema elevatum diutinum</i>	1 (1.02%)
Total	98 (100.00%)

Table 5: Possible etiologies of cases histologically diagnosed with LCV

Possible etiologies	Number of patients (%)
Idiopathic	67 (69.07%)
Infection	25 (25.51%)
URTI	4 (4.08%)
UTI	15 (15.30%)
Others (unknown)	6 (6.12%)
Drug-induced	5 (5.10%)
Amoxicillin	2 (2.04%)
Paracetamol	1 (1.02%)

Paracetamol+Ibuprofen	1 (1.02%)
Herbal medicine	1 (1.02%)
Drug and infection	1 (1.02%)
Penicillin and URTI	1 (1.02%)

Table 6: Outcomes of histologically diagnosed cases of LCV from January 2000 – December 2012

Drugs	Total patients (n, %)	Outcome (n, %)		
		Resolved	Improved	Not Improved
Oral prednisone	42 (42.86%)	15 (15.31%)	13 (13.27%)	14 (14.29%)
Topical steroids	36 (36.70%)	5 (5.15%)	15 (15.46%)	16 (16.49%)
Colchicine	28 (28.57%)	12 (12.24%)	10 (10.20%)	6 (6.12%)
Antibiotics	17 (17.35%)	4 (4.08%)	8 (8.16%)	5 (5.10%)
Dapsone	2 (2.04%)	N/A	2 (2.04%)	N/A
Pentoxifylline	2 (2.04%)	1 (1.02%)	1 (1.02%)	N/A
Indomethacin	1 (1.02%)	N/A	1 (1.02%)	N/A
Azathioprine	1 (1.02%)	N/A	1 (1.02%)	N/A

*N/A: Not applicable

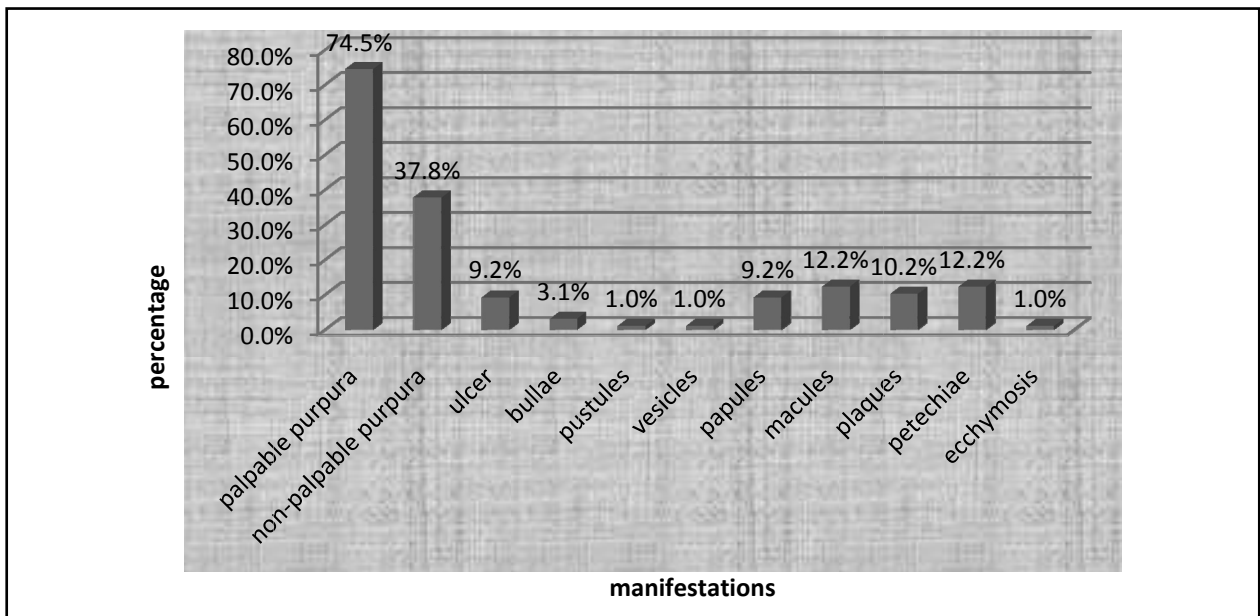


Figure 1: Clinical presentations of cases histologically diagnosed with LCV

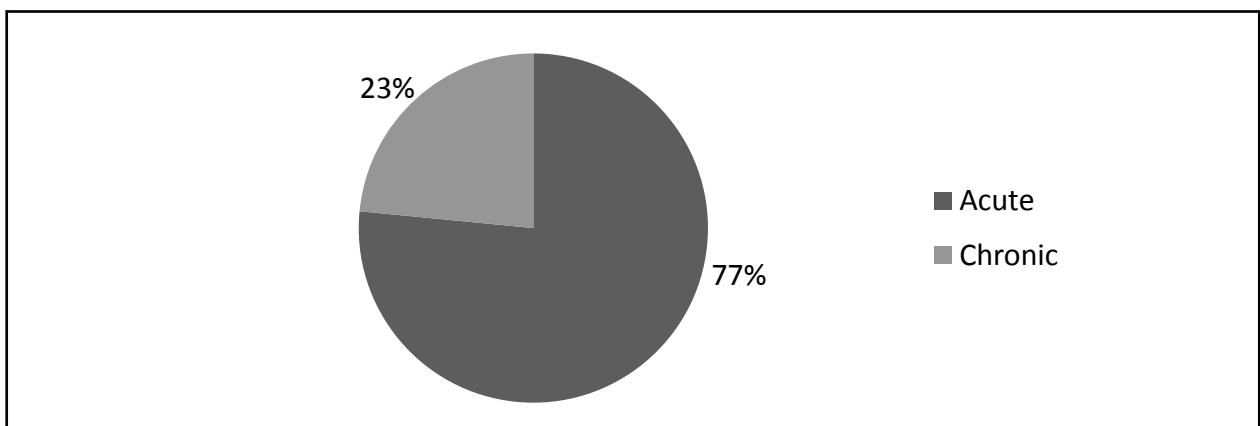


Figure 2: Chronicity of disease in cases histologically diagnosed with LCV

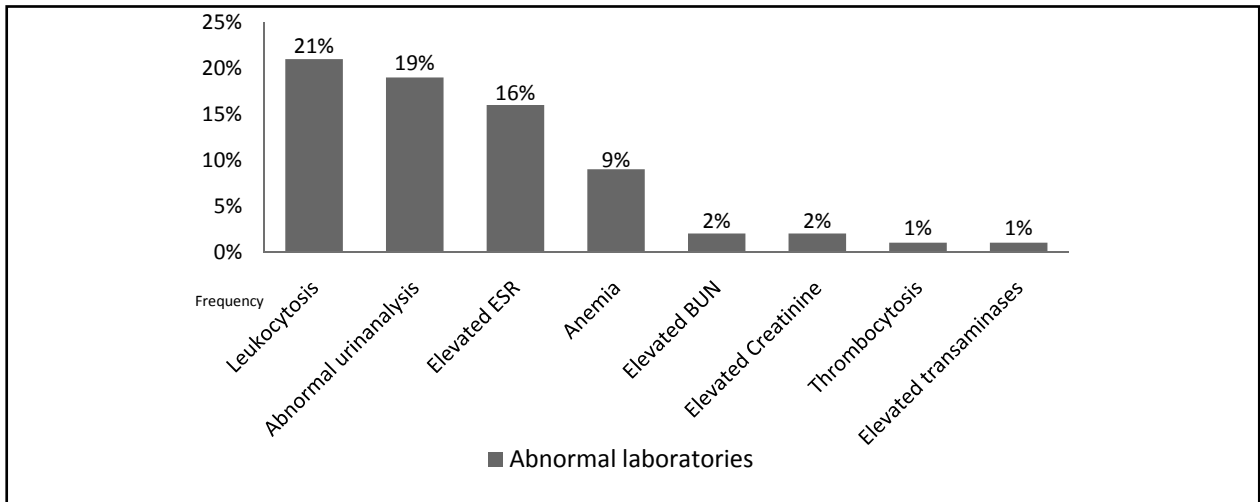


Figure 3: Abnormal laboratories in histologically diagnosed cases of LCV

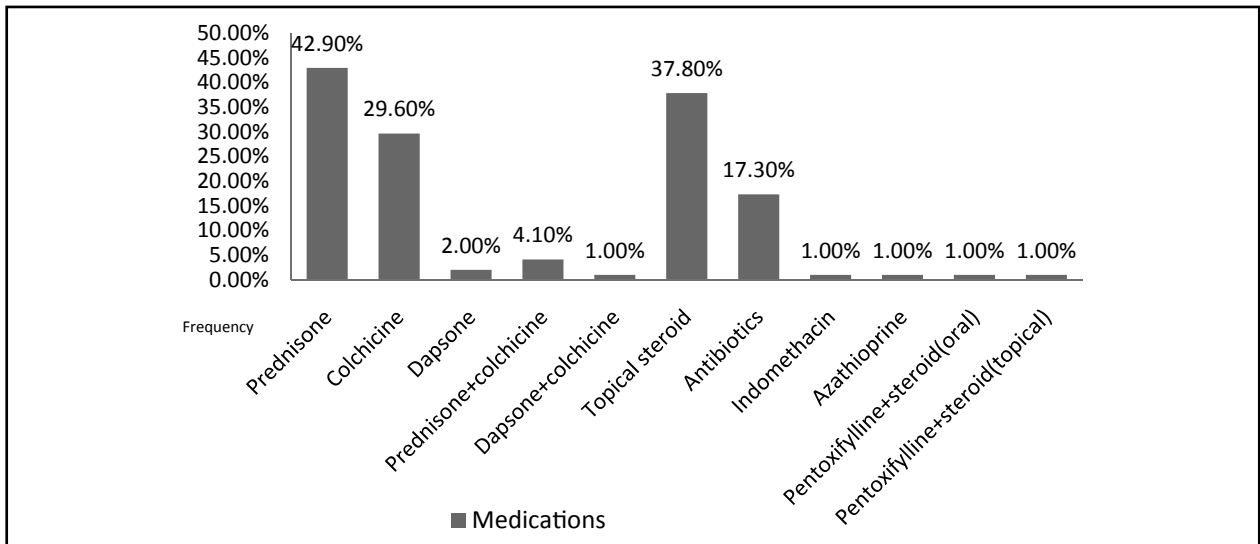


Figure 4: Medications given to histologically diagnosed cases of LCV

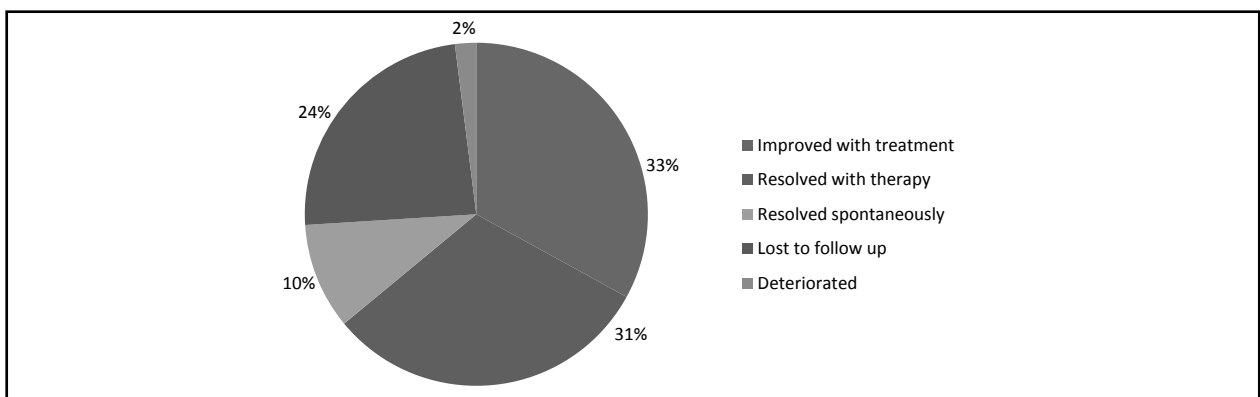


Figure 5: Outcomes of histologically diagnosed cases of LCV from January 2000 – December 2012

Discussion

The results of our study have shown that patients histologically diagnosed with LCV at the JRRMMC department of Dermatology are most commonly

at the 2nd decade of life. This is contrary to other published studies in Asia such as Malaysia⁷ and Singapore⁸ (mean age 36 years old) and in Australia⁹ (mean age 56 years old). There are conflicting studies

regarding sex distribution, with some reporting male⁹ (Australia), female⁸ (Singapore) or equal distribution⁷ (Malaysia). Our data is in accordance with the data of Singapore⁸. The clinical presentations and site of predilection of our patients are similar to other published reviews.^{7-9,11} As is expected, all patients diagnosed with hypersensitivity vasculitis (HV) (all 11 cases) and majority of HSP patients (23 out of 25 cases) were acute, while cases of urticarial vasculitis (2 cases) and EED (1 case) had a chronic presentation.

The majority of the cases in our study have an unknown etiology. Common etiologies were infections and drugs. This is also in accordance to studies done in Singapore⁸ and Australia.⁹ However, unlike in these countries where the most common infection is an URTI, our most common infection is UTI. Amoxicillin and analgesics were the most commonly associated drugs, similar to a retrospective study in Spain.¹¹

Complete blood count and urinalysis were the most commonly done laboratory work-ups by the patients, despite the more complete panel that the dermatologists request (liver and renal profile, chest radiograph, ESR, CRP). However, these workups seem to be enough to diagnose concomitant infections

and may even reveal renal impairment in some of the patients. Anti-nuclear factor, ANCA, cryoglobulins were not done at our institution since our patients cannot afford such investigations. These workups are reportedly unhelpful in the clinical diagnosis.¹⁰

There were neither organ malignancies nor association of connective tissue diseases found in any of the cases reviewed in this study. Other countries report the association of these conditions with LCV but this may be due to more specialized centers in their institutions.

Conclusion

Our retrospective study revealed that in JRRMMC, LCV commonly affects young adults (second decade of life). A female predominance was noted. Presenting symptom and site of predilection are in accordance with previous studies. The most common laboratory abnormality was leukocytosis, but majority had idiopathic LCV. Infections and drugs were common offending agents, usually caused by UTI and amoxicillin, respectively. Most of the patients were managed with steroids and colchicine. The majority of the cases improved with therapy, and some patients resolved spontaneously.

References

1. Fiorentino DF. Cutaneous vasculitis. *J Am Acad Dermatol* 2003; 48: 311-40. <http://dx.doi.org/10.1067/mjd.2003.212>
2. Russell JP, Gibson LE. Primary cutaneous small vessel vasculitis: approach to diagnosis and treatment. *International Journal of Dermatology* 2006; 45: 3-13. <http://dx.doi.org/10.1111/j.1365-4632.2005.02898.x>
3. Soter SA, Diaz-Perez JL. Cutaneous Necrotizing Vasculitis. Wolf K, Goldsmith LA, Katz SI, Gilchrist BA, Paller AS, Leffell DJ, editors. *Fitzpatrick's Dermatology in general medicine*, 7th ed. The McGraw Hill; 2008: p1599-606.
4. Barnhill RL, Nousari CH, Xu X, Barksdale SK. Vascular disease. Elder DE, Elenitsas R, Johnson BL, Murphy GE, Xiaowei X, editors. *Lever's Histopathology of the Skin*. 10th ed. Lippincott Williams & Wilkins; 2008: p206-34.
5. Sunderkötter C. Leukocytoclastic vasculitis. *CME Dermatol* 2008; 3: 32-50.
6. Lotti T, Comacchi C, Ghersetich I. Cutaneous Necrotizing Vasculitis. *Int J Dermatol* 1996; 35: 457-74. <http://dx.doi.org/10.1111/j.1365-4362.1996.tb01656.x>
7. Leelavathi M, Aziz SA, Gangaram HB, Hussein SH. Cutaneous Vasculitis: A Review of Etiology and Clinical Manifestations in 85 Patients in Malaysia. *Med J Malaysia* 2009; 64: 210-2.
8. Chua SH, Lim JT, Ang CB. Cutaneous Vasculitis Seen at a Skin Referral Centre in Singapore. *Singapore Med J* 1999; 40: 147-50.
9. Tai YJ, Chong AH, Williams RA, Cumming S, Kelly RI. Retrospective analysis of adult patients with cutaneous leukocytoclastic vasculitis. *Australasian Journal of Dermatology* 2006; 47: 92-6. <http://dx.doi.org/10.1111/j.1440-0960.2006.00239.x>
10. Asad S, Smith AG. Cutaneous vasculitis: a retrospective study. *J Am Acad Dermatol* 2004; 50: 113. <http://dx.doi.org/10.1016/j.jaad.2003.10.377>
11. Garcia-Porrúa C, Gonzalez-Gay MA, Lopez-Lazaro L. Drug associated cutaneous vasculitis in adults in northwestern Spain. *J Rheumatol* 1999; 26: 1942-4.