

# Henoch-Scholein Purpura (HSP): A Clinico-etiological Study

Kareem NS<sup>1</sup>, Riyaz N<sup>2</sup>

<sup>1</sup>Assistant Professor, Department of Dermatology, Venereology and Leprology, Sree Narayana Institute of Medical Sciences, Chalakka 683 594, Kochi, Kerala, India

<sup>2</sup>Professor & HOD, Department of Dermatology, Venereology and Leprology, Government Medical College, Calicut 673 008, Kerala, India

## Address for correspondence

Dr. Semeena N. K.

Department of Dermatology, Venereology and Leprology  
Sree Narayana Institute of Medical Sciences  
Chalakka - 683 594, Ernakulam (Dt)  
Kerala, India  
Mobile: +91 8289 866 399  
Email: sameenahabeeb@ymail.com

## Citation

Kareem NS, Riyaz N. Henoch-schonlein purpura (HSP): a clinic-etiological study. NJDVL 2014; 12(1): 28 - 33.

## Abstract

**Background:** Henoch-Schönlein (HSP) is a small vessel vasculitis affecting skin and internal organs.

**Objectives:** To determine the age group affected, etiological factors, clinical features, complications and association with other diseases.

**Methods:** The study included 50 patients over a period of 3 years selected on the modified criteria by American College of Rheumatology. Clinical assessment was done and investigated for any focus of hidden infections especially Dental and ENT by respective departments. Associated conditions, complications and recurrence were also observed.

**Results:** All patients had palpable purpura (pruritic in 58% and with hemorrhagic bullae in 6%) with upper respiratory tract prodrome (44%), joint involvement (94%) and gastrointestinal symptoms (90%). Precipitating factors were sore throat (74%), caries tooth (44%), drugs (30%) and food (16%) in varying combinations. On investigation 56% had raised ESR and 22% were with abnormal peripheral smears. All biopsies showed leucocytoclastic vasculitis. Occult blood in stool was detected in 10% and 2% showed Streptococci in throat swab culture. Renal involvement was 54% (RBC and albumin-42%, RBC alone-12%). One patient had intestinal perforation. Bleeding time, clotting time, platelet count, cryoglobulin, ANA, rheumatoid factor, HBs Ag, VDRL and X-ray chest were within normal limits. LE cell test was negative. Follow up study showed recurrence in 98%.

**Conclusion:** HSP is a small vessel vasculitis in response to any unknown foreign or endogenous antigen. The age of onset varied from below 7 to 58 years, with most of them below 20. The most important clinical presentation was palpable purpura in lower extremities. GIT and joint involvement were more. Renal involvement found to be the most common complication.

**Key Words:** Abdominal Pain, Arthritis, Melena, Palpable Purpura, Renal Complications

## Introduction

Henoch-Schönlein Purpura (HSP) is an IgA mediated systemic small vessel vasculitis commonly affecting joints, gastrointestinal tract (GIT) and kidneys.<sup>1</sup>This was first reported by

Heberden in 1801.<sup>2</sup> In 1837 Schönlein described association of purpura and joint pain and termed this as “peliosis rheumatica”. In 1874 and 1899, Henoch added GIT and renal manifestations to that description respectively.<sup>3</sup>

## Original Article

The disease can occur in all age groups.<sup>2</sup> Most commonly incriminated organism is Streptococcus<sup>4</sup>, other responsible factors are bacteria,<sup>5</sup> virus,<sup>6</sup> food<sup>7</sup> and drugs.<sup>8</sup> Exact etiology is not known. The HLA associations mentioned are HLA DQA1, DRB1, HLAB35 and HLA B18.<sup>9</sup> It has association with diseases like lymphoma, leukemia, solid tumors<sup>10</sup> and guttate psoriasis.<sup>11</sup>

### Material and Methods

This study was conducted in department of Dermatology, Government Medical College, Calicut, India over a period of 3 years. The study population included 50 patients fitting into clinical presentation of HSP. All of them consented for study, and it was approved by Institutional Ethical Committee. Diagnosis of HSP was based on modified American College of Rheumatology Criteria (ARC criteria 1990) put forward by Helander, De Castro and Gibson (more than 90% sensitivity and specificity).<sup>12</sup> Palpable purpura, age of onset, GIT symptoms and histopathological evidence of vasculitis were taken into account. Immunofluorescence was done only in patients above age 30 (13 patients) due to socio-economical reasons, to satisfy the criteria. (Diagnostic Criteria - Table 1)

**Table 1:** Criteria for diagnosis of HSP in patients with skin lesions of vasculitis or histologic evidence of leukocytoclastic vasculitis, or both (any three out of the following should be present)

1	Direct immunofluorescence study suggesting vasculitis with IgA vascular deposits
2	Age <30 years at the onset of symptoms
3	Gastro intestinal involvement
4	Upper respiratory tract infection prodrome
5	Mesangioproliferative glomerulonephritis on renal biopsy with or without IgA deposition

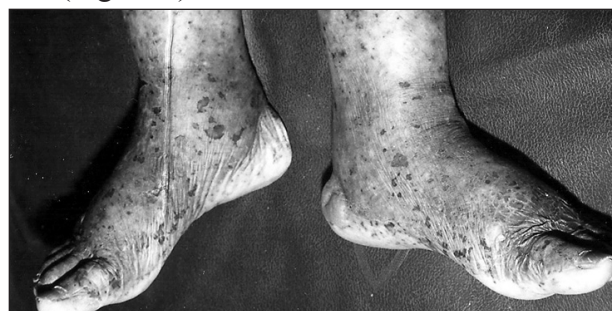(The American College of Rheumatology 1990 criteria – modified by Helander, De Castro and Gibson-with aspecificity and sensitivity >90%) Particular emphasis was given to age of patients, sex, onset of lesions, site, spread and associated pruritus. Abdominal symptoms, arthralgia and renal symptoms were recorded. Precipitating factors like food, drugs and infections were noted. Familial occurrence was documented. A thorough physical examination for associated diseases was made and findings recorded. Dental and ENT check up for hidden infections were carried out by respective departments. Patients were advised to maintain a food diary to observe if any food item was the responsible cause.

Laboratory investigations included routine blood and urine, bleeding time, clotting time, platelet count, LE cell, random blood sugar, ASO titre, serum electrolytes, cryoglobulins, ANA, RA factor, HBs Ag, VDRL, benzidine test for stool occult blood, renal function test, liver function test, peripheral smear, throat swab culture and sensitivity, X-ray chest and skin biopsy.

### Results

Age of the affected patients varied from 7 to 58 years (Mean  $23.1 \pm 14.6$  years, Median: 18.5). Fifty four percentage of the patients were below 20 years. As age advanced, occurrence of the lesion also decreased. The study revealed male to female ratio as 1:1.9.

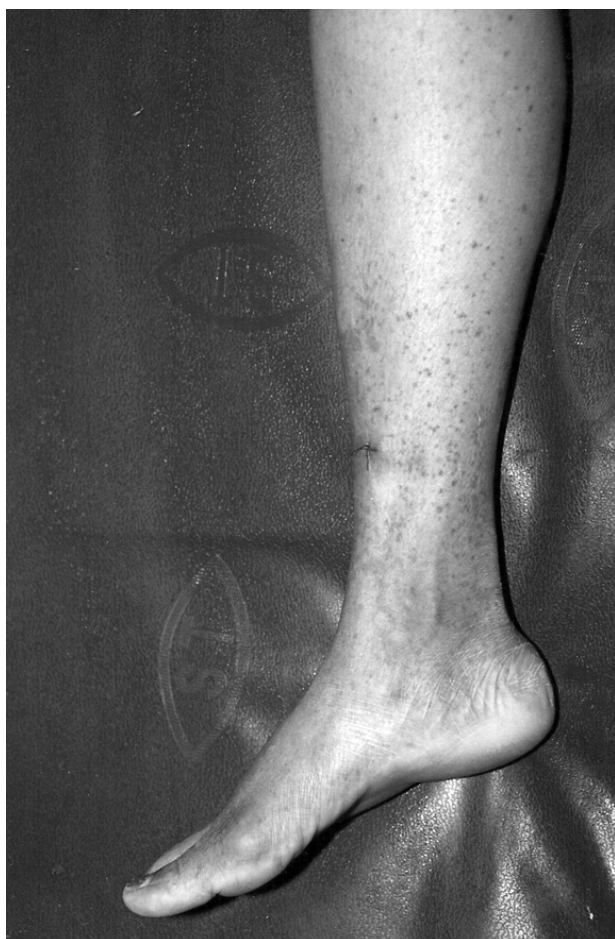Palpable purpuric lesions were the main clinical presentation of the disease (100%). Palpable purpura with hemorrhagic bullae were present in 6% (Figure 1).



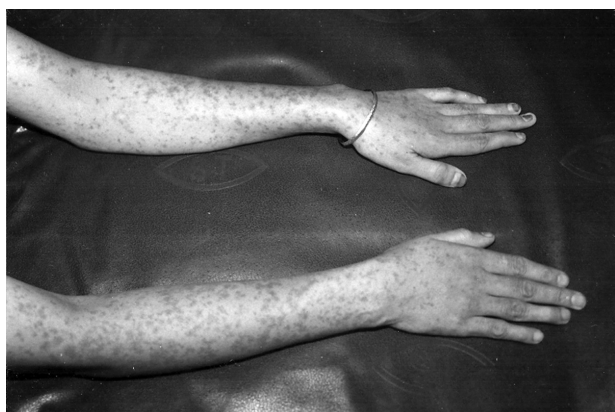**Figure 1:** HSP with haemorrhagic bullae

## Original Article

The lesions were pruritic in 58% and pain along with pruritus noted in 2%. Lesions were mostly concentrated on extensor aspect of the extremities. Fifty two percentage were on the extensor aspect of the lower limb (Figure 2 ) and 12% on extensor aspect of the upper limb (Figure 3) and lower limb. Truncal involvement was minimal (2%).



**Figure 2:** Palpable purpura on lower limb



**Figure 3:** Palpable purpura on upper limbs

Seventy Four percentage of the patients had upper respiratory tract infections. Pain during micturation was also noted in 8%.

Patients with gastrointestinal tract involvement showing abdominal pain were 44%. Rest of the patients had abdominal pain, melena, haematemesis and vomiting in combinations (Table 2). Ninety four percentage of the patients had joint involvement. The arthritis varied from mono (4%), oligo (22%) to polyarthritis (68%). Ankle was the most commonly affected joint (64%). Nature of the joint involvement varied from non-fleeting (56%) to fleeting (38%).

**Table 2:** Details of gastrointestinal symptoms reported by patients

S.N.	Symptoms	% of patients
1	Abdominal pain	44
2	Abdominal pain, melena, vomiting	6
3	Abdominal pain, hematemesis	6
4	Abdominal pain, melena, vomiting, diarrhoea	10
5	Abdominal pain, diarrhoea	6
6	Abdominal pain, melena	6
7	Abdominal pain, vomiting	8
8	Abdominal pain, vomiting, diarrhoea	4
9	Vomiting	2
10	No symptoms	10
	Total	100

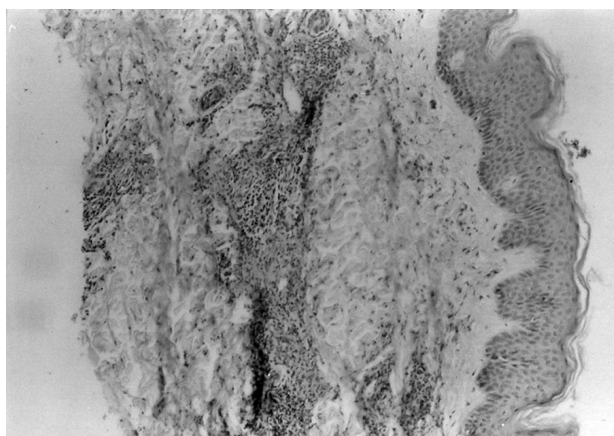
Precipitating factors detected were sore throat (66%), caries tooth (40%), food (16%) and Drugs (30%) in multiple combinations. (Patients were rechallenged with food but not with drugs due to ethical reasons). Leg ulcer, pyoderma, diabetes mellitus, hypertension, tuberculosis, psoriasis and infected wounds were other factors found in association with this disorder.

## Original Article

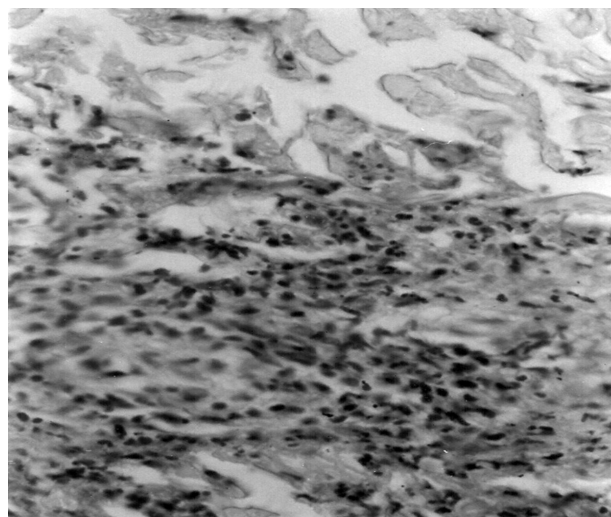
Forty four percent of the patients had normal laboratory investigation report. Rest on blood routine examination showed raised ESR in 40%, raised ESR with neutrophilia in 10%, raised ESR with neutrophilia and eosinophilia 4% and raised ESR with lymphocytosis 2%.

Bleeding time and clotting time were within normal range in all patients. Twenty two percentages showed higher values for random blood sugar and 6% revealed raised ASO titre. On urine examination, 42% showed albuminuria with hematuria and 12% showed only hematuria.

Out of 50 peripheral smears 22% showed abnormalities which included presence of toxic granules (8%), neutrophilia (12%) and neutrophilia with eosinophilia (2%). Renal function test and liver function test were normal in all patients. None of them showed LE cell positivity. Skin biopsy was done in all 50 patients and results showed leukocytoclastic vasculitis (Figure 4 & Figure 5). Immunofluorescence done in 26% showed IgA vascular deposits.



**Figure 4:** Leukocytoclastic vasculitis (H&E x10)



**Figure 5:** Leukocytoclastic vasculitis (H&E x40)

Two percentages of the patients showed streptococci on throat swab culture and sensitivity and others revealed normal flora. Stool benzidine test for occult blood was positive in 10%. All chest X-rays were within normal limits. To exclude other causes of systemic vasculitis; cryoglobulins, ANA, rheumatoid factor, Hbs Ag and VDRL were done and these found to be negative in all patients.

Ninety eight percentage of the patients showed recurrence out of which 82% had 1 to 5 times and 16% had 6 to 10 times. The most susceptible age group was between 20 and 40 years. Renal involvement was the most common complication found among this age group (28%).

### Discussion

HSP is a small vessel vasculitis affecting skin and other internal organs<sup>1</sup>. It can occur at any age<sup>2</sup> (2). In this study 54% of patients were under 20 years, out of this 14% were under 10 years and 40% were between 10 and 20years.

The present study revealed a female predominance (male/female ratio - 1:1.9) where as others reported male predominance<sup>1</sup>. There was increased incidence in June to December like other studies which showed increased incidence in winter and spring.<sup>13</sup>

**Original Article**

According to epidemiological studies, the etiological factor may be an infectious agent and 50-75% of patients had history of preceding upper respiratory tract infection,<sup>14</sup> but we also found that in 74%. Other diseases associated with this entity observed were leg ulcer (6%), pyoderma (8%), diabetes mellitus (6%), hypertension (6%), tuberculosis (4%), otitis (2%) and psoriasis (2%). A case of guttate psoriasis associated with HSP has been reported in literature.<sup>11</sup>

Drugs like ampicillin, penicillin, quinine, chlorpromazine, ranitidine, cefuroxime, diclofenac, enalapril and captopril and food containing salicylates and azodyes have been implicated as etiological factors.<sup>13</sup> Present study revealed drugs like antibiotics (ampicillin-4%), anti-inflammatory drugs (ibuprofen-4%, diclophenac-2%), antidiabetics-4%, antacid-2% and ayurvedic drugs-14% as responsible factors mainly in adults. Food items such as beef (4%), green gram (4%), fish (6%) and banana (2%) were also revealed as etiological factors.

We did not observe familial incidence in this study which was documented by others in rare instances.<sup>15</sup> People in the same family had disease at the same time, but they were not blood relatives (sister-in-laws), indicating possible viral etiology.

Bilateral palpable purpura was present in all patients in which 58% were pruritic, only 6% showed hemorrhagic bullae, which was reported in literature.<sup>16</sup> Lesions mainly seen in lower limb (52%) which explains the effect of gravity. Trunkal involvement was only in 2%, that too in bed ridden patients which also explained the effect of gravity. The purpuric lesions flattened and became nonpalpable in one or two days.

Ninety four percent of patients, included in this study exhibited joint involvement. Literature revealed joint involvement only in 60-84% of cases.<sup>3</sup> Sixty eight percentage of our patients had polyarticular type of arthritis mainly involving

knee and ankle joints. The joint involvement left no deformity.

Gastrointestinal symptoms were noted in 90% of cases. It was found to be 35-80% in literature.<sup>17</sup> Abdominal pain was the most predominant (44%) symptom. Others included melena, vomiting, diarrhoea and haematemesis (Table 2). Fourteen percentage had melena and 6% haematemesis compared to 15% and 50% respectively in other studies.<sup>13, 17</sup>

Positive ASO titre indicates upper respiratory tract infection with streptococcal species which was reported as a predisposing factor in as 50% of patients,<sup>18</sup> but in our study throat swab culture and sensitivity revealed streptococci infection in 2% of cases only.

Histopathological results of all patients showed leucocytoclastic vasculitis which was also observed by others.<sup>19</sup> Raised ESR (56%) and presence of toxic granules (8%), neutrophilia (12%) in peripheral smear points to an infective etiology.

Occult gastrointestinal bleeding was reported in HSP.<sup>20</sup> Ten percentage of our patients showed gastrointestinal bleeding.

Most important complication reported was renal involvement (10% to 63%).<sup>21</sup> In our study we observed 54% with renal involvement. Out of these 42% had RBC's in urine along with albuminuria and 12% had haematuria alone. Only 8% showed symptoms of renal involvement (dysuria) where as 46% of cases neither show any abnormality on routine urine examination nor any symptoms. We had one patient with intestinal perforation which was also reported in literature.<sup>17</sup>

Relapse reported in 1/3<sup>rd</sup> of patients.<sup>5, 11</sup> In this study, except one patient all the others had exhibited recurrent nature of the disease.

## Original Article

Recurrence was noted in adults between the age group 20 and 40.

### Conclusion

HSP is a small vessel vasculitis in response to any unknown foreign or endogenous antigen. The age of onset varied from below 7 to 58 years, with most of them below 20. The most important clinical presentation was palpable purpura in lower extremities. GIT and joint involvement were more prominent in our study conducted at

the South Indian State of Kerala than mentioned in literatures. Recurrent nature of disease, seasonal variations and occurrence in same family members (not in blood relatives) at same time pointed to viral etiology. Though 54% patients showed renal involvement on investigation, none had progressed to renal failure. Complications (renal involvement, and perforation) developed only in adults. Recurrences were noted in almost all patients (98%). So, long term follow up is necessary.

### References

1. Tizard EJ. Henoch-Schönlein purpura. *Arch Dis Child* 1999; 80: 380-3.
2. Tizard EJ, Hamilton-Ayres MJJ. Henoch-Schönlein purpura. *Arch Dis Child Educ Pract Ed* 2008; 93: 1-8.
3. Iian Y, Naparstek Y. Schönlein Henoch Syndrome in adults and children. *Semin Arthritis Rheum* 1991; 21: 103-9.
4. Al-SheyyabM, Batiah A, El-Shanti H. *Ann Trop Pediatr* 1999; 19: 253-5.
5. Kaneki T, Kawashima A, Hayashida M, Yamaguchi S, Ogasawara H, Tsushima K et al.. A case of Henoch-Schönlein purpura after *Staphylococcus aureus* enterocolitis. *Nippon Shokakibyō Gakkai Zasshi* 2000; 97: 1278-82.
6. Costa MM, Lisbov M, Romeu JC, Caldeira J, De Queiroz V. Henoch-Schönlein Purpura associated with coxsackie-virus infection. *Clin Rheumatol* 1995; 14: 488-90.
7. Robinson BW. Henoch-Schönlein purpura due to food sensitivity. *Br Med J* 1977; 1: 510-11.
8. Szer IS. Henoch-Schönlein purpura. *Curr Opin Rheumatol* 1994; 6: 25-31.
9. Amoroso A, Berrino M, Canale L, Coppo R, Cornaglia M, Guarrera S et al.. Immunogenetics of Henoch-Schönlein disease. *Eur J Immunogenet* 1997; 24: 323-33.
10. Rai A, Nast C, Adler S. Henoch-Schönleinpurpura nephritis. *J Am Soc Nephrol* 1999; 10: 2637- 44.
11. Pavithran K. Henoch-Schönlein purpuraevolving into acute guttate psoriasis. *Indicator J Dermatol Venerol Leprol* 1990; 56: 147-8.
12. Mills JA, Micheal BA, Bloch DA, Calabrese LH, Hunder GG, Arend WP et al. The American College of Rheumatology 1990 criteria for the classification of Henoch-Schönleinpurpura. *Arth Rheum* 1990; 33: 1114-21.
13. Allen DM, Diamond LK, Howell DA. Anaphylactoid Purpura in Children (Schönlein-Henoch Syndrome). *AMA J Dis Child* 1960; 99: 833-54.
14. Nielsen HE. Epidemiology of Schönlein-Henoch Purpura. *Acta Pediatr Scand* 1988; 77: 125-31.
15. Golstein AR, White RH, Akuse R, Chantler C. Long term follow up of childhood Henoch-Schönlein nephritis. *Lancet* 1992; 339: 280-2.
16. Trapani S, Mariotti P, Resti M, Nappini L, De Martino M, Falcini F. Severe hemorrhagic bullous lesions in Henoch Schonlein purpura: three pediatric cases and review of the literature. *Rheumatol Int* 2010; 30: 1355-9.
17. Choong CK, Beasley SW. Intra-abdominal manifestations of Henoch-Schönlein purpura. *J Pediatr Child Health* 1998; 34: 405-9.
18. Mattoo TK, A I-Mutair A, Al-Khatib Y, Ali A, Al-Shoaibani MO. Group A beta-hemolytic streptococcal infection and Henoch-Schönlein purpura with cardiac and neurological complication. *Ann Trop Pediatr* 1997; 17: 381-6.
19. Veraldi S, Mancuso R, Rizitelli G, Gianotti R, Ferrante P. Henoch-Schönlein syndrome associated with human Parvovirus B19 primary infection. *Eur J Dermatol* 1999; 9: 232-3.
20. Jensen B. Schönlein-Henoch's Purpura. *Internal Medicine* 1955; 152: 61-70.
21. Rieu P, Noel LH. Henoch-Schönlein nephritis in children and adults: Morphological features and clinicopathological correlations. *Ann Med Interne* 1999; 150: 151-9.