

Multivessel primary PCI in patient with peripheral arterial disease

Bishal KC,¹ Chandra Mani Adhikari,² Binay Kumar Rauniyar,² Deepak Limbu,² Rabi Malla²

¹ Department of Cardiology, National Academy of Medical Sciences, Bir Hospital, Kathmandu

² Department of Cardiology, Shahid Gangalal National Heart Centre, Bansbari, Kathmandu

Corresponding author: Bishal KC

Department of Cardiology,

National Academy of Medical Sciences, Bir Hospital, Kathmandu

Email Address: bishalk@gmail.com

Abstract

Thrombosis of multiple coronary arteries is extremely rare finding in the setting of acute myocardial infarction. This often leads to cardiogenic shock and sudden cardiac death. We report a case of 61 years old gentleman who presented with complaints of sudden onset of chest pain of 4 hours duration and dizziness with near syncope 2 hours prior to presentation and ST segment elevation in anterior and inferior leads with complete heart block. Coronary angiogram revealed total occlusion of left anterior descending (LAD) and right coronary arteries (RCA). After the PCI to RCA followed by LAD, patient went into Pulse less electrical activity. Cardiopulmonary resuscitation, immediate percutaneous coronary intervention of the LAD and RCA, temporary pacing, immediate intubation and mechanical ventilation was carried out. The patient was eventually discharged with a New York Heart Association functional class II heart failure.

Keywords : Acute myocardial infarction, complete heart block, coronary thrombosis, primary percutaneous coronary intervention

Introduction

Acute myocardial infarction (AMI) is caused by the rupture of vulnerable plaque with thrombus formation and subsequent occlusion of the vessel. The culprit vessel is single in most of the time.¹ Simultaneous occlusion of multiple coronary arteries at the time of acute MI is extremely uncommon and is often fatal.² Multiple plaque rupture as a cause of multivessel involvement in the setting of Acute MI has been reported in more than 10% of autopsied cases, but clinically it is difficult to identify because most of them has rapid and fatal outcomes.^{3,4,5,6} Most

patient with multivessel myocardial infarction are sick at the time of presentation. Cardiogenic shock and sudden cardiac death are common mode of presentation in ER.⁷ Peripheral arterial disease is one of the independent risk factors for acute coronary syndrome.^{8,9,10}

We report a case of a patient with severe diffuse atherosclerotic peripheral arterial disease. Patient presented ST segment elevation in anterior and inferior leads with complete heart block. He underwent successful angioplasty of RCA and LAD.

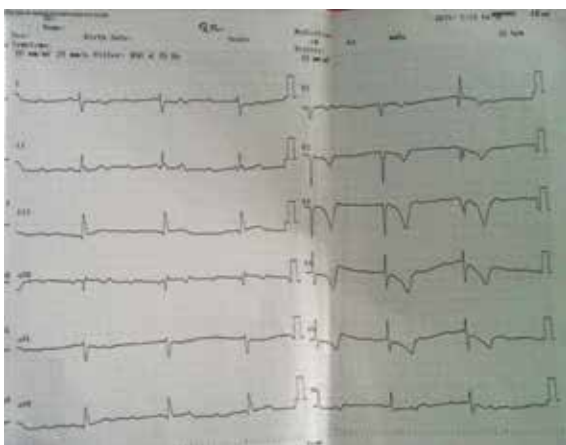


Fig. 1. ECG Showed Complete Heart Block

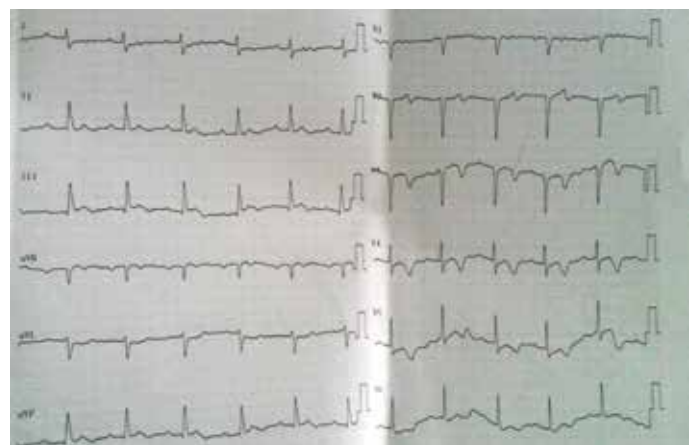


Fig. 2. ECG Showed ST elevation in inferior and anterior leads

Case Report

A 61years old gentleman presented in ER with the complaints of chest discomfort of 4 hours duration, dizziness with near syncope 2 hours prior to presentation. On examination he was conscious. His vitals were BP 110/80mmHg, Pulse rate of 42 beats per minute regular palpable on the left radial artery only. Other physical findings were unremarkable. He was a known diabetic under medications and a chronic smoker. The initial ECG revealed complete heart block (CHB) as shown in Fig 1. Subsequent ECG after restoration of sinus rhythm showed ST elevation over the inferior and anterior leads as shown in Fig 2. Cardiac enzymes were elevated with CPK MB 90U/L and Troponin I was positive. He was treated in the line of Acute Coronary Syndrome (STEMI) with Aspirin 300mg and Clopidogrel 600mg loading dose. He was then taken to cardiac catheterization lab immediately for

revascularization and pacemaker insertion. We inserted temporary pacemaker via right femoral vein. We thought of inserting IABP but bilateral femoral artery was not accessible. The right radial artery was also not palpable. We did manage to access the left radial artery. Subsequent coronary angiogram revealed total occlusion of Mid RCA and proximal LAD as shown in Fig. 3 and Fig. 4. We went for RCA revascularization first and then for LAD as shown in Fig. 5 and Fig. 6. After PCI to LAD patient went into Pulse less electrical activity. Cardio Pulmonary Resuscitation (CPR) was initiated and he was intubated. He was then shifted to ICU and was kept in mechanical ventilation. His Chest X-ray was suggestive of pulmonary edema. His total count was high and had fever. He was managed with intravenous diuretics and antibiotics. He was gradually weaned off the ventilation. His temporary pacemaker lead was removed. Finally he was discharged with NYHA II heart failure.

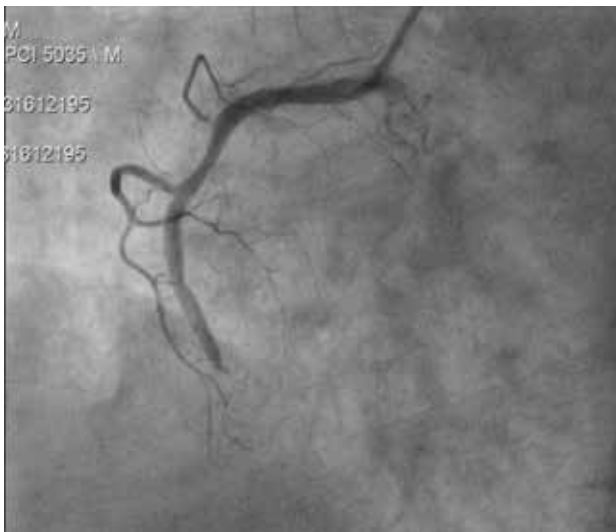

Fig. 3. Coronary angiogram showed total occlusion of mid RCA

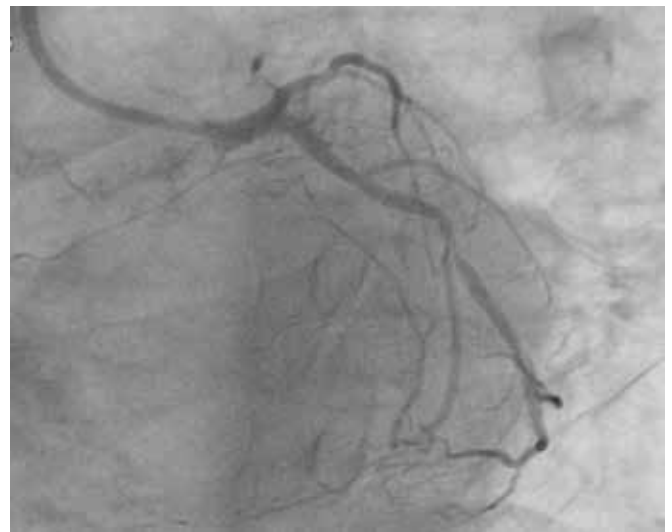


Fig. 4. Coronary angiogram showed total occlusion of proximal LAD

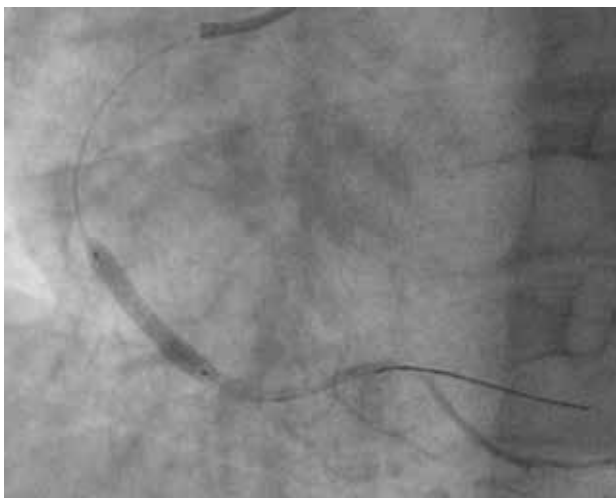

Fig. 5. Stenting of RCA

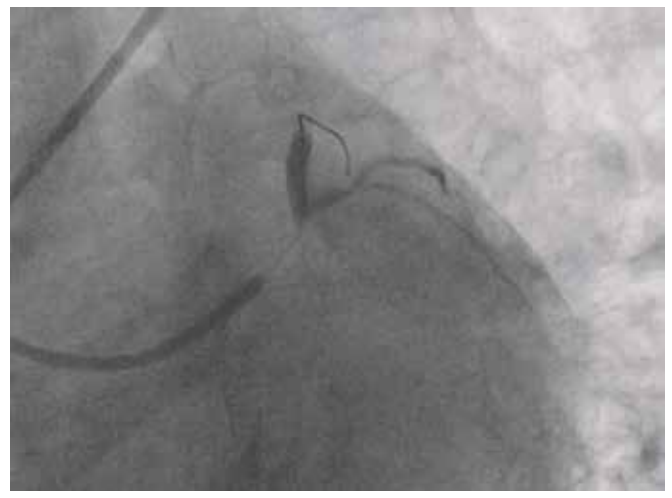


Fig. 6. Stenting of LAD

Discussion:

In myocardial infarction, the common finding is the rupture of unstable plaque with subsequent thrombotic occlusion. Simultaneous double vessel acute myocardial infarction (AMI) is extremely rare and usually has poor clinical outcomes.¹¹ The current American College of cardiology/American heart association guidelines for the management of patients with ST-elevation myocardial infarction (STEMI) recommends primary percutaneous coronary intervention (PCI) as the treatment of choice.^{12,13} Those patients who has multivessel disease during primary PCI, culprit vessel revascularization is the priority and the remaining vessel is addressed later as an elective procedure. For those with hemodynamic compromise at presentation multivessel PCI is recommended as we did in our case.¹⁴ Multi vessel coronary artery thrombosis has a catastrophic outcome. The main risk factors include essential thrombocytosis, intravenous cocaine abuse, diabetes, and smoking. The vessels involved being LAD (78%) and the RCA (87%) and our case had also involvement of LAD and RCA.¹⁵ Acute myocardial infarction is believed to be caused by rupture of an unstable coronary-artery plaque that appears as a single lesion on angiography. However in cases of multiple lesions additional pathophysiological processes such as inflammation plays role.¹⁶ In our case the initial ECG showed ST elevation in both inferior and anterior leads but the presence of complete heart block made us think that the culprit lesion might be RCA. It is fascinating to observe that there was RCA and LAD lesion in the initial coronary angiogram, cardiogenic shock did not occur at first but developed only after reperfusion of LAD with patient going into PEA. CHB in AMI can occur in both anterior as well as inferior involvement. High (second or third) degree AV block occurs in approximately 9.8 percent of patients with an inferior MI and 3.2 percent of patients with an anterior MI who receive thrombolytic therapy.¹⁷ Mortality among patient with CHB is still high and has not declined within last decade. The AMI patients who develop CHB in the thrombolytic era have significantly worse prognosis than do patients without CHB.¹⁸ Peripheral arterial disease (PAD) affects 12%–14% of the general population and its prevalence increases with age affecting up to 20% of patients over the age of 75.¹⁹ Patients with PAD are at increased risk of coronary, carotid and cerebrovascular atherosclerosis disease, and all-cause mortality.^{20,21,22,23} PAD was documented in 2.6% of the total patient presented with acute coronary syndrome in an study done by Hassan A. Al-Thani et al.²⁴ In our case he was a documented case of severe PAD which we came to know later when we reviewed his past documents shown by the family members later. This precluded us from using IABP at first and finding the vascular access for the PCI was difficult.

Conclusion

This is a rare case of simultaneous occlusion of multiple coronary arteries presenting with multiple complications. Although this has high mortality we report a successful revascularization and survival following judicious use of medical treatment and efficient multivessel primary PCI.

Conflicts of interest

The authors have no conflicts of interest to declare

References

1. Lanaro E, Júnior EC, Falcão FJ, et al. Simultaneous Thrombosis in Two Epicardial Coronary Arteries During

- Acute Myocardial Infarction. *Rev Bras Cardiol Invasiva*. 2012;20(4):431-4.
2. Lee WH, Hsu PC, Lin TH, et al. Acute myocardial infarction with simultaneous involvement of right coronary artery and left anterior descending artery: A case report. *Kaohsiung J Med Sci* 2010; 26(7):384-8.
3. Garbo R, Steffenino G, Dellavalle A, et al. Myocardial infarction with acute thrombosis in multiple major coronary vessels. *Ital Heart J* 2000; 12: 824 – 31.
4. Boztosun B, Gurel E, Gunes Y, et al. Myocardial infarction associated with thrombus formation in non-culprit coronary arteries. *J Thromb Thrombolysis* 2007; 23: 73 – 5.
5. Davies MJ, Thomas A. Thrombosis and acute coronary artery lesions in sudden cardiac ischemic death. *N Engl J Med* 1984; 310: 1137–40.
6. Arbustini E, Dal Bello B, Morbini P, et al. Plaque erosion is a major substrate for coronary thrombosis in acute myocardial infarction. *Heart* 1999; 82: 269–72.
7. Lee CW, Lai CH, Lu TM. Double coronary artery thrombosis presenting as acute anterior ST-segment elevation myocardial infarction. *J Chin Med Assoc*. 2013;76(7):407-10.
8. Criqui MH, Langer RD, Fronek A, et al. Mortality over a period of 10 years in patients with peripheral arterial disease. *N Engl J Med*. 1992; 326: 381–6.
9. Hertzner NR, Beven EG, Young JE, et al. Coronary artery disease in peripheral vascular patients: a classification of 1000 coronary angiograms and results of surgical management. *Ann Surg*. 1984; 199: 223–33.
10. Hertzner NR. Basic data concerning associated coronary disease in peripheral vascular patients. *Ann Vasc Surg*. 1987; 1: 616–20.
11. Sia SK, Huang CN, Ueng KC, et al. Double vessel acute myocardial infarction showing simultaneous total occlusion of left anterior descending artery and right coronary artery. *Circ J*. 2008 ;72(6):1034-6.
12. Antman E.M., Anbe D.T., Armstrong P.W.; ACC/AHA guidelines for the management of patients with ST-elevation myocardial infarction: a report of the American College of Cardiology/American Heart Association Task Force on Practice Guidelines (Committee to Revise the 1999 Guidelines for the management of Patients With Acute Myocardial Infarction). *J Am Coll Cardiol*. 44 2004;44:E1-E211.
13. Antman E.M., Hand M., Armstrong P.W.; 2007 focused update of the ACC/AHA 2004 guidelines for the management of patients with ST-elevation myocardial infarction: a report of the American college of Cardiology/ American Heart Association task Force on Practice Guidelines. *J Am Coll Cardiol*. 2008;51:210-247.
14. Smith S.C. Jr., Feldman T.E., Hirshfield J.W. Jr. ACC/AHA/SCAI 2005 guideline update for percutaneous coronary intervention: a report of the American College of Cardiology/American Heart Association Task force on Practice guidelines (ACC/AHA/SCAI Writing Committee to Update the 2001 Guidelines for Percutaneous Coronary Intervention). *J. Am Coll Cardiol*. 47 2006:e1-e121.
15. Kanei T, Janardhanan R, Fox JT, et al. Multivessel coronary artery thrombosis. *J Invasive Cardiol* 2009;21:66-8.
16. Goldstein JA, Demetriou D, Grines CL, et al. Multiple complex coronary plaques in patients with acute myocardial infarction. *N Engl J Med* 2000;28:915-22.
17. Meine TJ, Al-Khatib SM, Alexander JH, et al. Incidence, predictors, and outcomes of high-degree atrioventricular block complicating acute myocardial infarction treated with thrombolytic therapy. *Am Heart J* 2005; 149:670.

18. Harpaz D, Behar S, Gottlieb S, et al. Complete atrioventricular block complicating acute myocardial infarction in the thrombolytic era. SPRINT Study Group and the Israeli Thrombolytic Survey Group. Secondary Prevention Reinfarction Israeli Nifedipine Trial. *J Am Coll Cardiol.* 1999 Nov 15;34(6):1721-8.
19. Hiatt WR, Hoag S, Hamman RF. Effect of diagnostic criteria on the prevalence of peripheral arterial disease. The San Luis Valley Diabetes Study. *Circulation.* 1995;91:1472-9. Bhatt DL, Peterson ED, Harrington RA, et al. for CRUSADE Investigators. Prior polyvascular disease: risk factor for adverse ischaemic outcomes in acute coronary syndromes. *Eur Heart J.* 2009;30(10):1195-202.
20. Sabouret P, Cacoub P, Dallongeville J, et al. for REACH Registry investigators. REACH: international prospective observational registry in patients at risk of atherothrombotic events. Results for the French arm at baseline and one year. *Arch Cardiovasc Dis.* 2008 ;101(2):81-8.
21. Criqui MH, Ninomiya JK, Wingard DL, et al. Progression of peripheral arterial disease predicts cardiovascular disease morbidity and mortality. *J Am Coll Cardiol.* 2008 Nov 18;52(21):1736-42.
22. Shah AM, Banerjee T, Mukherjee D. Coronary, peripheral and cerebrovascular disease: a complex relationship. *J Indian Med Assoc.* 2010;108(5):292-4, 296.
23. Shah AM, Banerjee T, Mukherjee D. Coronary, Peripheral and Cerebrovascular disease a complex relationship. *J Indian Med Assoc.* 2010;108(5):292-4, 296
24. Al-Thani HA, El-Menyar A, Zubaid M, et al. Peripheral Arterial Disease in Patients presenting with Acute Coronary Syndrome in Six Middle Eastern Countries. *Int J Vasc Med.* 2011;Volume 2011, Article ID 815902, 8 pages doi:10.1155/2011/815902

Cite this article as: Bishal KC, Chandra Mani Adhikari, Binay Kumar Rauniyar, et al. Multivessel primary PCI in patient with peripheral arterial disease) *Nepalese Heart Journal* 2017;14(1): 35-38