

Case report

Ocular myocysticercosis: an unusual case of ptosis

Agrawal S, Ranjan S, Mishra A
Santosh Medical College, Ghaziabad, India

Abstract

Background: Cysticercosis is common in endemic countries like India. It can have various clinical manifestations depending on the tissue involved. It refers to a parasitic infestation by *Cysticercus cellulosae*, the larval form of the pork tapeworm or *Taenia solium*. **Objective:** To report an unusual case of ocular cysticercosis involving the levator palpebrae superioris and superior rectus muscle of the right eye. **Case description:** A young, male adult was diagnosed by Magnetic Resonance Imaging (MRI) scan of the skull and orbit to have right-sided ocular cysticercosis. The patient was treated with oral prednisolone and albendazole, to which he showed a significant improvement. **Conclusion:** Ocular myocysticercosis can be diagnosed by MRI and be treated medically with steroid and albendazole.

Keywords: Cysticercosis, levator palpebrae superioris, superior rectus

Introduction

Cysticercosis, a parasitic infestation by *Cysticercus cellulosae*, the larval form of the pork tapeworm -*Taenia Solium*, is common in India, where it is endemic, and has a variety of clinical presentations. It often infests humans due to drinking of contaminated water, eating uncooked meat or vegetables infested with the eggs of the worm, or due to auto-infestation.

The cyst is endemic in developing countries of Latin America, Asia and Africa, especially in areas of poor hygiene (Pushker et al, 2001). About 40 % of the infested subjects develop ocular Cysticercosis (Mukherjee and Agrawal, 1975). The extra ocular muscles are the most common site of involvement of orbital cysticercosis. However, the lateral rectus, medial rectus and superior oblique muscles have been found to be affected to a greater extent (Sundaram et al, 2004). In our case, the cyst was located in the levator palpebrae superioris (LPS) and

superior rectus (SR) muscles of the right eye, the less common sites to be located in.

History

A 24-year-old man and a driver by profession and a non-vegetarian presented with right sided blepharoptosis since the last five months. He gave a history of fever five months before, after which he noticed the drooping of the right upper eyelid two days later. He was treated with oral steroids for three months and had temporary relief.

Examination

There was a ptosis of the right upper eyelid associated with some swelling. The extraocular movements were within the normal range in all positions of gaze. The sclera and anterior segment were normal and the pupils were bilaterally similar, being equal in shape, size and reaction to light. A dilated fundus examination revealed no abnormality. The remainder of the findings of the neurological and general physical examination revealed no abnormalities.

Received on: 23.09.2012

Accepted on: 05.05.2013

Address for correspondence: Dr Somesh Ranjan B2/302, Lotus Pond Apartment, Vaibhav Khand, Indirapuram, Ghaziabad-201010, Uttar Pradesh, India

Tel: 9958899639

Email: ranjan.somesh@gmail.com

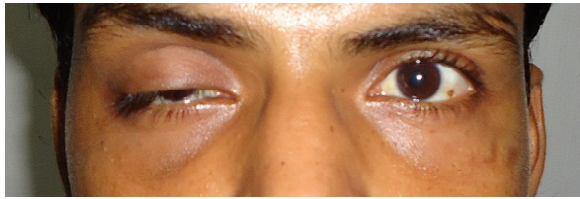

Figure 1

Investigations

The complete blood count was normal. The MRI of the skull and of the right orbit showed bulky and edematous levator palpebrae superioris (LPS) and superior rectus (SR) muscles along with a small and rounded peripheral ring enhancing the cystic lesion. The findings were suggestive of inflammatory granuloma, and of myocysticercosis involving the LPS and SR in the right orbit. The enzyme linked immunosorbent assay for serum antibodies against cysticercosis was positive.

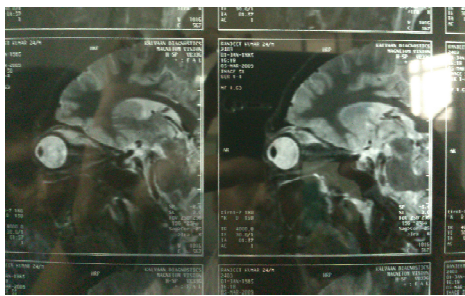


Figure 2 (A)

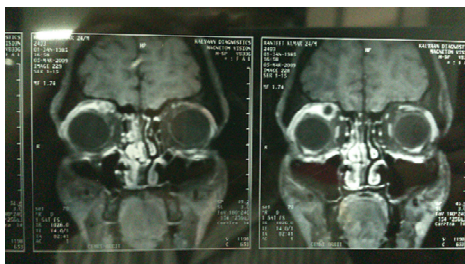


Figure 2(B)

Diagnosis and treatment

The patient was diagnosed as a case of ocular myocysticercosis and treated with oral prednisolone and albendazole.

Discussion

Ocular manifestations may be devastating as the cysticercus enlarges. In the eye, the cysticerci may involve the intra-ocular or the extra-ocular tissues. The cysticerci have been reported to

involve the vitreous body and the sub-retinal space (Lech, 1949; Reddy et al, 1980) as well as the anterior chamber and the sub-conjunctival space (Mehrotra and Sofat, 1975; Shea et al, 1973).

Ocular cysticercosis can be diagnosed by orbital imaging. The CT scan and MRI are helpful in diagnosing orbital and intra-ocular cysticercosis as well as to rule out neuro-cysticercosis.

In our patient, the cyst was present in the SR and LPS muscles complex and the patient responded well to systemic albendazole and steroid therapy.

Conclusion

Cysticercosis should be considered in patients with acquired blepharoptosis. It can be treated medically with oral steroid and albendazole.

References

- Kaliaprumal S, Rao VA, Parija SC (2005). Cysticercosis of eye in South India-a case series. *Indian J Med Microbiol*; 23:227-30.
- Lech Junior (1949). Ocular cysticercosis. *Am J Ophthalmol*; 32:523-548.
- Mukherjee PK, Agrawal S (1975). Sub-conjunctival twin cysticercosis. *Indian J Ophthalmol*; 23:28-9.
- Mehrotra SK, Sofat BK (1975). Ocular cysticercosis. *Indian J Ophthalmol* ; 23:39-40.
- Pushker N, Bajaj MS, Chandra M et al (2001). Ocular and orbital cysticercosis. *Acta Ophthalmol Scand*; 79:408-13.
- Reddy CC, Gupta VP, Sarada P, et al (1980): Ocular cysticercosis. *Indian J Ophthalmol*; 28:69-72.
- Sundaram PM, Jayakumar N, Noronha V (2004). Extraocular muscle cysticercosis - a clinical challenge to the ophthalmologists. *Orbit*; 23:255-62.
- Shea M, Maberley AL, Walters J, et al (1973). Intraocular *Taenia crassiceps* (Cestode). *Trans Am Acad Ophthalmol Otolaryngol*; 77:778-838.

Source of support: nil. Conflict of interest: none