

Original article

Outcome of the patients with post-operative cluster endophthalmitis referred to a tertiary level eye care center in Nepal

Gautam P, Joshi SN, Thapa M, Sharma AK, Shah DN
BP Koirala Lion's Center for Ophthalmic Studies, Institute of Medicine, Kathmandu, Nepal

Abstract

Introduction: The causative organism and treatment outcomes of post operative endophthalmitis may vary depending on several factors. **Objective:** To find out the causative organisms and visual outcome after an outbreak of post-operative endophthalmitis. **Materials and methods:** An interventional prospective series of cases of clinically suspected endophthalmitis was studied. Eleven patients who presented within 48 hours after manual cataract surgery on the same day, by a one surgeon in a single center were enrolled in the study. They underwent both anterior chamber and vitreous aspiration and all of them received intravitreal Vancomycin, Amikacin and Dexamethasone. Samples were subjected to microbiological evaluation. All patients were followed up till 8 weeks for clinical and visual outcome. **Results:** Of the 11 eyes of suspected endophthalmitis, only one vitreous aspiration showed Gram negative bacilli on Gram stain and 3 vitreous aspirates showed Gram positive cocci. Of the 11 eyes, 3(42.85%) had culture positive on vitreous aspirate. In 2 cases E Coli was isolated and in 1 Staphylococcus aureus was isolated. After 48 hours of intravitreal injection, 10 out of 11 eyes improved and in one, intravitreal injection of vancomycin, amikacin and dexamethasone was repeated. The best corrected visual acuity of 6/9 was achieved in 2 patients, 5 had 6/18, 2 had 6/60 and 2 had 5/60 at the end of eight weeks. **Conclusion:** Staphylococcus aureus and E coli can cause endophthalmitis immediately on the first day post-operatively. Clinically suspected endophthalmitis treated with antibiotics and steroid intravitreal injection can result in better visual outcome.

Keywords: cataract surgery, endophthalmitis, postoperative

Introduction

Cataract surgery is one of the most frequently performed intraocular surgeries in the world. 90% of postoperative endophthalmitis is seen following cataract surgery (Verbraeken 1995). Post-operative endophthalmitis after cataract surgery, though rare, is still reported (Kehdi et al, 2005). The incidence of postcataract surgery endophthalmitis varies, ranging from <math><0.05\%</math> to >math>0.3\%</math> (Al-Mezaine et al,

2009; West et al 2005; Ravindran et al, 2009). Postoperative endophthalmitis after cataract surgery is damaging, because it can lead to permanent vision loss and loss of the eye (Aaberg et al, 1998; Choi et al, 2011). Cluster endophthalmitis can be defined as five or more cases of endophthalmitis occurring on a particular day in a single operating room in one centre (Bajimaya et al, 2010). The present study was carried out to determine the outcome of promptly diagnosed and treated cases of cluster endophthalmitis.

Materials and methods

A prospective interventional study with the intention to treat was carried out on cluster endophthalmitis patients. These patients were referred to BP Koirala Lions Centre of Ophthalmic Studies (BPKLCOS) from a collaborative eye clinic on May 2012. Total of 11 patients, operated on the same day by a single surgeon from one center were enrolled. A detailed history including the findings of clinical examination at presentation was recorded. The types of surgical procedure performed and events during surgery if any were reviewed from the clinical case sheets from the collaborative eye clinic. Communication with the involved surgeon and the staff was done. Predisposing factors attributed to the patient like high blood sugar, poor lid hygiene and to the surgeon like irregular wound construction and wound leak if present were also recorded. Acute post cataract surgery endophthalmitis was diagnosed clinically and based on posterior-segment ultrasonography. Diagnosis of endophthalmitis was made on the basis of symptoms of profound pain, redness and decreased visual acuity, and signs of hypopyon and/or vitreous clouding and absence of severe corneal edema on slit lamp bio-microscopy. Intraocular pressure (IOP) was also recorded. Ultrasonography of the eye was done in all cases to assess the extent and location of vitreous involvement and rule out retinal detachment and choroidal detachment. On ultrasonography, all of the eyes had echo dense opacities persisting on low gain in anterior and mid vitreous. Toxic anterior segment syndrome was considered as differential diagnosis as presentation was within 48 hours of surgery. However, a remote possibility cannot be completely ruled out. The test for Endotoxins was not possible in our set up. All the cases were managed as per Endophthalmitis Vitrectomy Study (EVS) 1995. They received intravitreal antibiotics and steroid since the all patients presented within 48 hours with clinical signs and symptoms of acute postoperative endophthalmitis and visual acuity of hand movement or better. Both aqueous and vitreous samples for microbiological evaluation were collected at the beginning, before injection of intravitreal

antibiotics in all cases. With full aseptic precautions, under peribulbar anesthesia, vitreous tap was performed in the isolated community operation room. A vitreous sample (0.2 to 0.3 ml) was obtained by a 25 gauge needle aspiration 3.5 mm posterior to limbus at the superior-temporal pars plana area. Intravitreal antibiotics and steroid were injected empirically at the end of anterior chamber and vitreous aspiration sampling. The vitreous samples were sent to microbiology laboratory at BPKLCOS and were subjected for Gram staining, Giemsa staining, KOH wet preparation, and culture and sensitivity test using the culture media: chocolate agar, brain heart infusion and Sabouraud's dextrose agar. Anterior and posterior segment evaluations were done by a general ophthalmologist and a vitreo-retinal surgeon as well. Intravitreal antibiotics were a combination of Vancomycin (1 mg/0.1 ml), Amikacin (0.4 mg/0.1 ml) and Dexamethasone (0.4 mg/0.1 ml). Six hours after intravitreal injection, all patients received topical medication. Prednisolone acetate 1% one hourly which was tapered off weekly along with Ofloxacin 0.3% 2 hourly and Tropicamide 1% 8 hourly were given. Oral Ciprofloxacin 750 mg 12 hourly for 5 days, as it is a beneficial adjunctive therapy (Morlet et al, 2000), and Prednisolone 40 mg for 7 days after intravitreal aspirate and antibiotics were also added. Visual acuity testing, anterior segment biomicroscopy and fundus examinations were performed on the next day in the morning. Good visual outcome was defined as visual acuity of 6/60 or better at the final follow-up (Carrim et al, 2009).

Results

Of the eleven eyes in the study, 8 eyes were right eye (73%) and 3(27%) were left. There were 6 male and 5 female patients. Ages ranged from 35 to 79 years. The mean age was 57 years (SD \pm 12.19). The median age was also 57 years and the mode age was 60 years. All the patients had a normal

blood sugar level preoperatively and were put on Ofloxacin eye drops 8 hourly on the eye undergoing operation 3 days prior to surgery.

Manual Small incision cataract surgery (SICS) with posterior chamber IOL was done in 10 and conventional ECCE with IOL in 1 case on a single day. Of the eleven patients, ten patients had uneventful intra-operative period, and the conventional ECCE case had posterior capsule rent with no vitreous loss. The wound construction was regular. To ensure leak proof wound, the wound was checked with a dry swab for leakage. In two Manual SICS cases interrupted sutures were placed as there was wound leak. All patients developed the features of endophthalmitis (symptoms of profound pain and redness poor visual acuity and signs of cells and flare in anterior chamber, hypopyon, corneal edema, and absent red reflex) within 48 hours of surgery. Hypopyon of 0.5 to 1.5 mm were seen in all 11 eyes. Ten eyes had an average of 0.5mm hypopyon. One eye had 1mm and one eye had 1.5mm hypopyon. In two of them hypopyon was mixed with hyphema. The mean time of presentation was 36 hours (SD±9.29 hours). However these patients had no marked lid edema or chemosis. Corneal edema was minimal; none had limbus to limbus corneal edema. Severe pain was the single most common complaint of all these patients. Six patients presented with severe painful diminution of vision and five with severe painful diminution of vision as well as photophobia. Eight eyes had hypopyon on 1st post operative day (POD) with painful diminution of vision and absent red reflex. Diminution of vision was marked but none had less than HM. Three eyes had pain, marked reaction but good fundal glow on the 1st POD but they presented with painful diminution of vision and absent red reflex on the 2nd POD (1/60 and above vision).

Table 1: Visual Acuity at Presentation

Presenting Visual Acuity	No. of Patients (%)
Hand movement	5(46%)
1/60-3/60	4(36%)
6/60-6/36	2(18%)

On ocular ultrasonography, all of the 11 eyes had echo reflective vitreous opacities persisting on low gain in the anterior and mid vitreous. All of the eleven eyes had normal IOP. The mean IOP was 14 mmHg (SD ±2.58).

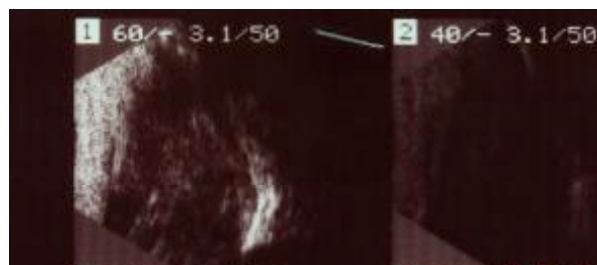


Figure 1: Clinical photograph of ultrasonography of one of the affected eyes which shows echodense opacities in the vitreous in both high and low gain.

All the patients were taken to operation theatre and painting was done with 10% betadine solution After peribular block, under full aseptic measures anterior chamber and vitreous aspirate samples were taken. Surgical wounds were inspected. None of the patients had wound dehiscence. Of the 11 eyes, vitreous aspiration was turbid in eight eyes and two had clear but straw colored aspirate. The samples were subjected to microbiological study.

Only one vitreous aspiration showed Gram negative bacilli on Gram stain. 3 vitreous aspirates showed Gram positive cocci. Of the 11 eyes, 3 were culture positive on vitreous aspiration and 8 were culture negative. In 2 cases E Coli and in 1 Staphylococcus aureus were isolated. The isolates were sensitive to vVancomycin, aAmikacin, oOfloxacin and cChloramphenicol only. Gram stain and culture from anterior chamber aspirates were negative for both Gram stain and growth in culture media. The collaborative eye clinic was contacted and asked to get the batch of trypan blue, viscoelastic substances and ringer lactates used at the time of surgery to the BPKLCOS laboratory. There was no growth of organisms on culture of these samples. Flushing from tubing and Simcoe irrigation aspiration cannula could not be retrieved to send for culture.

Table 2: Microbiology of anterior chamber and vitreous aspirates

Stain and Culture	Anterior chamber aspirate	Vitreous aspirate
Gram stain	No organism or pus cells	4 (1 Gram negative bacillus, 3 Gram positive cocci)
Culture	Culture sterile	3 had culture positive (2 E Coli, 1 Staphylococcus aureus)

As per the EVS 1995 injection regimen, all of them received intravitreal antibiotics and steroid. Eight patients presented on the first POD. Three patients presented within 24 hours of operation, five presented within 36 hours of operation and three presented on the 2nd POD, that is within 48 hours of operation. They were given intravitreal Vancomycin 1 mg, Amikacin 0.4 mg and Dexamethasone 1mg along with subconjunctival Vancomycin and Dexamethasone on the same day of presentation.

After 48 hours of intervention, 10 out of 11 eyes improved symptomatically as well as clinically and in 1 intravitreal injection of Vancomycin, Amikacin and Dexamethasone were repeated. Almost all of the patients felt marked decrease of intensity of pain after 24 hours of intravitreal antibiotics and steroid. They were reevaluated on slit lamp biomicroscope on the next day of the intravitreal injection and the hypopyon almost cleared in 9 and was present in trace amount in 2 cases. Good fundal reflex was present in all 11 eyes. They were started on topical antibiotic and steroid and tropicamide 1% after 6 hours of intravitreal injection.

Among the 11 eyes, 3 eyes developed posterior capsular opacification. Almost all of the eyes had a minimal anterior chamber reaction at the end of 8 weeks. 2 had significant opacities in the vitreous also. The best corrected visual acuity of 6/9 was present in 2 patients with minimal anterior chamber reaction and minimal vitreous opacities, 5 had 6/18 with mild to moderate vitreous opacities and early PCO, 2 had 6/60 with moderate vitreous

opacities and early PCO and 2 had 5/60 visual acuity with significant vitreous opacities and early PCO. Nine (81.81%) out of 11 eyes had good visual outcome.

Table 3: Visual outcome at the end of study period

Best corrected visual acuity	No. of Patients
6/9	2
6/18	5
6/60	2
5/60	2

The patients were followed up for 8 weeks. 2 patients were lost for follow up after 6 weeks as they were from distant places and when contacted declined to be followed up.

Discussion

This study attempted to look at the factors responsible for endophthalmitis like features on the first post-operative day. Those factors included uncontrolled blood sugar, poor lid hygiene, irregular wound, wound leak and contaminated batch of operative materials. The outcome was analyzed based mainly on clinical improvement as well as visual acuity at the end of study in a suspected cluster of endophthalmitis in our setup.

Postoperative endophthalmitis poses a significant public health issue as millions of people have cataract surgery each year (Javitt et al, 1995, Leaming 2003). Incidence of endophthalmitis has been declining in the past several decades due to improved surgical techniques, sterilization methods and better postoperative care and use of broad-spectrum antibiotics (Ram et al, 2001). Despite these measures, cluster of cases of endophthalmitis can occur after cataract surgery and has been reported (Zaluski et al, 1999).

Source of infection could not be evaluated in our series as the patients were referred from a distant collaborative eye clinic where microbiological facilities were not present. On communication with the collaborative eye clinic it was found that patients wore unsterile hospital gowns over their own clothes,

whereas feet and head were left uncovered. In the preoperative room, the periocular skin was cleaned with 10% povidone-iodine solution before giving retrobulbar block. Reusable, sterile cotton drape was used to cover the surgical field. The surgeon and assistant had scrubbed with povidone iodine (7.5%) for 8 minutes and wore sterile gown and gloves. The surgeon had changed fresh gloves after 5 cases and in between each case used 70% isopropyl alcohol. The batch of trypan blue, viscoelastics and ringer lactate used at time of surgery were brought to BPKLCOS laboratory. They were sent for culture. They yielded no organisms. Test for Endotoxins was not done due to unavailability.

Factors associated with cluster endophthalmitis in the medical literature are poor sterilization technique and operation room hygiene, contaminated irrigating solutions, viscoelastics, improper ventilation system (Hughes et al 1994, Hasan 1994, Egger et al, 1994). There are no definite data with regard to these factors. The infective agents could have been introduced into the eye at the time of intraocular surgery (Walker et al, 1986). It has been thought that the patient's own conjunctival flora could be the most common source of infection (Speaker et al, 1991).

A failure to achieve perfect sterility of the surgical field may, in all probability, have played a role in development of these infections (Swaddiwudhipong et al, 1995). It is necessary to find out the culprit organism as part of the management. In our study *E. coli* and *Staphylococcus aureus* were isolated on culture. Culture positive cases were only 3 in number. Ultra-sonographic findings of the affected eye supported the clinical suspicion of acute infective endophthalmitis. However, toxic anterior segment syndrome could not be completely ruled out in the remaining 8 cases as endotoxin test could not be done. However, the follow up findings of persistent vitreous opacities in all cases in minimal to significant amount also goes in favor of endophthalmitis of.

The right eye was affected in two-thirds of our cases. This finding was consistent with studies from Nepal (Bajimaya et al, 2010; Thapa et al, 2011). In our study, the mean age of our patients was 57 years which was similar to other studies (Bajimaya et al, 2010; Thapa et al, 2011). Male and female were almost equal (6 male, 5 female) in our study. This finding is contradicting with the findings of other studies (Bajimaya et al, 2010; Malhotra et al, 2008; Thapa et al, 2011). Mean time of presentation was 36 hours. Therefore, toxic anterior segment syndrome was also considered as a differential diagnosis. On the basis of typical clinical findings and judgment and ocular ultrasonography findings acute endophthalmitis was diagnosed which was supported by microbiological evidence. Fungal endophthalmitis was not suspected as it is less common in acute cases (Fox et al, 1991). Therefore, all the cases were treated empirically with vancomycin (1 mg/0.1 mL) owing to its broad coverage of Gram-positive bacteria and amikacin (0.4 mg/0.1 ml) owing to its Gram negative coverage and dexamethasone (0.4 mg/0.1 ml) intravitreal injection.

Only one vitreous aspiration shows Gram negative bacilli on Gram stain report and 3 vitreous aspirates showed Gram positive cocci. Of the 11 eyes, 3 had culture positive on vitreous aspiration. In 2 cases, *E. coli* was isolated and in 1 *Staphylococcus aureus* was isolated. In a study done in India to evaluate organisms in 3 clusters with total of 24 patients, smears were positive for Gram-negative bacteria in 14 (58%) vitreous samples and cultures grew *Pseudomonas aeruginosa* in 10 (42%) of 24 samples (Malhotra et al 2008). In another study done in India (Anand et al, 2000) among 170 cases, 71 (41.7%) were attributable to Gram-negative, 64 (37.6%) to Gram-positive bacteria, and 37 (21.8%) to fungi. *E. coli* and *Staphylococcus aureus* were the isolates in the vitreous culture of our patients, and we didn't find any multiple pathogens and a predominance of a pathogenic organism. This is on a par with study done by Thapa et al (2011).

Early diagnosis and timely management with intravitreal medications with or without Pars Plana Vitrectomy (PPV) is the treatment of choice for postoperative endophthalmitis depending on the severity (EVS 1995). Eight out of 11 presented to us on 1st post operative day and the rest presented on the 2nd and 3rd postoperative day. All received intravitreal antibiotics immediately after clinical evaluation and ocular ultrasonography.

All our patients responded to medical therapy without the need for vitrectomy. Only one patient who received repeat intravitreal antibiotics also improved over 72 hours both clinically as well as in terms of visual acuity.

Timely detection, communication with the collaborative clinic, evaluation and intervention were the crucial factors for the response. In a study done by Malhotra et al (2008), PPV with intraocular antibiotics and steroid was performed in all the patients of the three clusters. Good visual outcome (Better than or equal to 6/60) was seen in our case series, 9 (81.81%) out of 11 eyes had good visual outcome. This is due to early presentation within the same day of suspicion of endophthalmitis and our preparedness for a detailed examination and essential intervention. This is on par with the study done by Bajimaya et al (2010) and Carrim et al (2009). About 74% (14/19) of their patients had achieved best corrected visual acuity better than or equal to 6/60.

Limitation of our study was that the follow-up period was short. Long term outcome could not be determined as the patient did not turn up for follow up either as they were from distant places and many of them were farmers who were busy in rice planting at that time. We could not evaluate the collaborative eye clinic for focus of infection.

Conclusion

Staphylococcus aureus and E coli can cause endophthalmitis immediately on the first day post-operatively. Clinically suspected endophthalmitis treated with antibiotics and steroid intravitreal

injection can result in better visual outcome. Intravitreal antibiotics and steroid along with the sub-conjunctival vancomycin are effective in the treatment of an outbreak of endophthalmitis.

Acknowledgements: Mr Ravindra Adhikari, Dr Barsa Suwal, Dr Bijay Bhusal and Mr Suresh Sharma are acknowledged for their assistance in carrying out this study.

References

Aaberg TM, Flynn HW, Schiffman J, et al (1998). Nosocomial acute-onset postoperative endophthalmitis survey: A 10-year review of incidence and outcomes. *Ophthalmology*; 105:1004-10.

Al-Mezaine HS, Kangave D, Al-Assiri A et al (2009). Acute-onset nosocomial endophthalmitis after cataract surgery. Incidence, clinical features, causative organisms, and visual outcomes. *J Cataract Refract Surg*; 35:643-649.

Anand AR, Therese KL, Madhavan HN (2000). Spectrum of etiological agents of postoperative endophthalmitis and antibiotic susceptibility of bacterial isolates. *Indian J Ophthalmol*; 48:123.

Bajimaya S, Kansakar I, Sharma BR, Byanju R. (2010). Outcome of cluster endophthalmitis in western plain region of Nepal. *Kath Univ Med J*; 8:102-108.

Carrim ZI, Richardson J, Wykes WN (2009). Incidence and visual outcome of acute endophthalmitis after cataract surgery-the experience of an eye department in Scotland. *Br J Ophthalmol*; 93(6):721-725.

Choi Jin A and Chung Sung Kun (2011). Postoperative endophthalmitis following Cataract Surgery in Asia *ISRN Ophthalmology Volume 2011, Article ID 917265*.

Egger SF, HuberSpitz V, Scholda C, Schneider B, Grabner G (1994). Bacterial contamination during extra capsular cataract extraction: prospective study on 200 consecutive patients. *Ophthalmologica*; 208: 77-81.

Endophthalmitis Vitrectomy Study (EVS) group, (1995). A randomized trial of immediate vitrectomy and of intravenous antibiotics for the treatment of postoperative bacterial endophthalmitis. *Arch Ophthalmol*; 113:1479-1496.

Fox GM, Joondeph BC, Flynn HW Jr et al (1991). Delayed-onset pseudophakic endophthalmitis. *Am J Ophthalmol*; 111:163-173.

Hassan IJ (1994). Endophthalmitis – problems, progress and prospects. *J Antimicrob Chemother*; 33: 383-6.

Hughes DS, Hill RJ (1994). Infectious endophthalmitis after cataract surgery. *Br J Ophthalmol*; 78: 227-32.

Javitt JC, Kendix M, Tielsch JM (1995). Geographic variation in utilization of cataract surgery. *Med Care*; 33:90-105

Kehdi EE, Watson SL, Francis IC, Chong R, Bank A, Coroneo MT (2005). Spectrum of clear corneal incision cataract wound infection. *J Cataract Refract Surg*; 31: 1702-6.

Leaming DV (2003). Practice styles and preferences of ASCRS members 2002 survey. *J Cataract Refract Surg*; 29:1412-1420.

Malhotra S, Mandal P, Patanker G, Agrawal D (2008). Clinical profile and visual outcome in cluster endophthalmitis following cataract surgery in Central India. *Indian J Ophthalmol*; 56:157-8

Morlet N, Graham GG, Gatus B (2000). Pharmacokinetics of ciprofloxacin in the human Eye: a clinical study and population pharmacokinetic analysis. *Antimicrob Agents Chemother*; 44(6): 1674-1679.

Ram J, Kaushik S, Brar GS, Taneja N, Gupta A, Kaushik S, Brar GS, Taneja N (2001). Prevention of postoperative infections in ophthalmic surgery. *Indian J Ophthalmol*; 49:1-2.

Ravindran R D, Venkatesh R, Chang D F, Sengupta S, Gyatsho J, and Talwar B (2009). Incidence of post-cataract endophthalmitis at Aravind Eye Hospital. Outcomes of more than 42,000 consecutive cases using standardized sterilization and prophylaxis protocols. *J Cataract Refract Surg*; 35:629-636.

Speaker MG, Milch FA, Shah MK (1991). The role of external bacterial flora in the pathogenesis of acute postoperative endophthalmitis. *Ophthalmology*; 98:639-49.

Swaddiwudhipong W, Tangkitchot T, Silarug N. (1995). An outbreak of *Pseudomonas aeruginosa* postoperative endophthalmitis caused by contaminated intraocular irrigating solution. *Trans R Soc Trop Med Hyg*; 89:288.

Thapa R, Paudyal G (2011). Outcome of vitrectomy in post-operative endophthalmitis. *Nepal J Ophthalmol*; 3 (6):102-108.

Verbraeken H (1995). Treatment of postoperative endophthalmitis. *Ophthalmological*; 209:165-171.

Walker CB, Claoue CM (1996). Incidence of conjunctival colonization by bacteria capable of causing post-operative endophthalmitis. *JR Soc Med*; 79:520-1.

West ES, Behrens A, McDonnell PJ et al (2005). The incidence of endophthalmitis after cataract surgery among the US medicare population increased between 1994 and 2001. *Ophthalmology*; 112 :1388-1394.

Zaluski S, Clayman HM, Karsenti G, Bourzeix S, Tournemire A. Clayman HM, Karsenti G (1999). *Pseudomonas aeruginosa* endophthalmitis caused by contamination of the internal fluid pathways of a phacoemulsifier. *J Cataract Refract Surg*; 25:540-5.

Source of support: nil. Conflict of interest: none