

## Case report

### Subfoveal triamcinolone acetonide following macular hole surgery

Jindal A, Bhawdekar A, Pathengay A  
GMRV Campus, Visakhapatnam, L V Prasad Eye Institutes, India

#### Abstract

**Background:** Triamcinolone acetonide (TA) is commonly used in vitreous surgery to visualize the posterior hyaloid and internal limiting membrane. Some TA can accumulate in the macular hole during surgery which can persist postoperatively. **Case:** A 17-year-old boy underwent successful macular hole surgery with TA-assisted induction of posterior vitreous detachment. Sub-foveal deposit of TA was observed postoperatively, which got absorbed at 7 weeks with complete closure of the macular hole, and best corrected visual acuity improved from 20/100 preoperatively to 20/60. **Conclusion:** Residual TA after macular hole surgery may not hamper the anatomical and functional outcome. Similar cases have been reported in the literature and most of them show no harmful effect of TA on macular hole closure and visual recovery.

**Key-words:** macular hole, sub-foveal triamcetonolone

#### Introduction

Triamcinolone acetonide (TA) is a water insoluble steroid which facilitates visualization of the vitreous for induction of posterior vit reous detachment during vitrectomy. It is also being used for internal limiting membrane peeling (Kimura et al, 2004). In the presence of a full thickness macular hole, there is concern regarding TA getting accumulated in the hole. We present here a review of the previously published literature on the anatomical and functional outcomes of macular hole surgery due to residual TA and report a case of subfoveal TA after macular hole surgery.

#### Case report

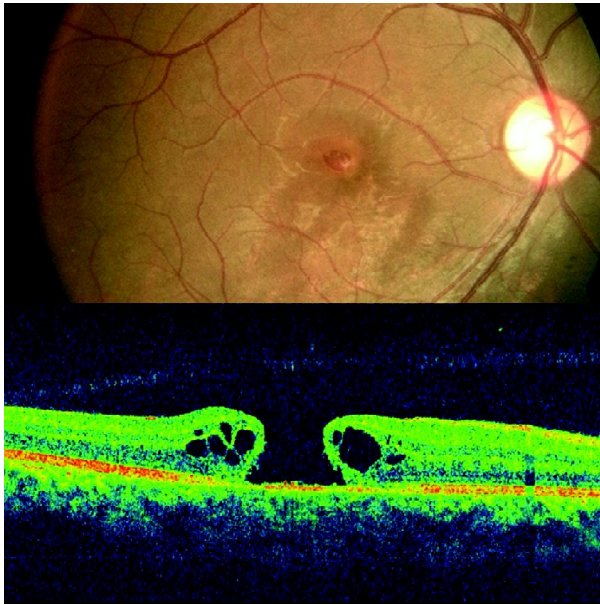
A 17-year-old boy presented to us with the complaint of a decrease of vision in the right eye since 2 months ago following blunt trauma with a rubber ball. He had a best corrected vision of 20/100 in the right eye and 20/20 in the left. Intraocular

pressure was 18 mm of Hg in the right eye and 14 mm of Hg in the left. On examination, a full thickness macular hole was observed in the right eye (Figure 1). Pars plana vitrectomy with TA-assisted PVD induction and brilliant blue G-assisted ILM peeling was performed. 14% C<sub>3</sub>F<sub>8</sub> was used for the internal tamponade and the the prone position 16 hours a day was advised. At two weeks after surgery, clinically, there was TA still present in the foveal region. OCT showed a closed macular hole with sub-foveal hyper -reflectivity casting a shadow over the deeper structures (Figure 2). The best corrected visual acuity had improved to 20/60 in the right eye. At seven weeks after surgery, there was no clinical evidence of residual TA and OCT showed a closed macular hole with a near-normal foveal contour (figure 3). The patient was maintaining a visual acuity of 20/60.

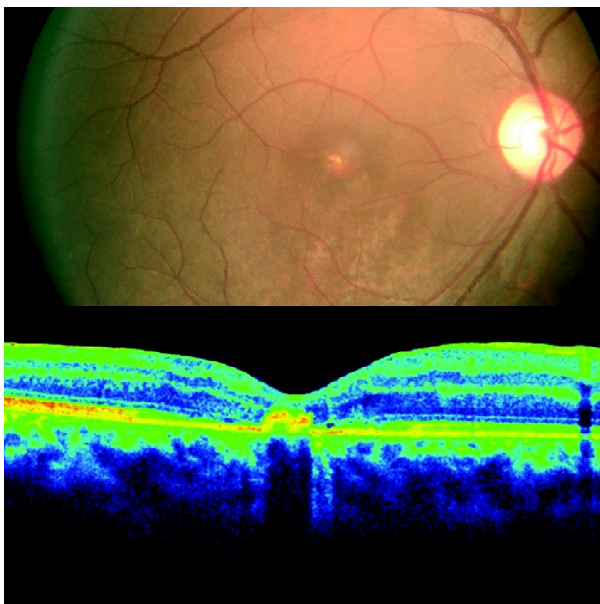
Received on: 08.01.2012

Accepted on: 12.07.2013

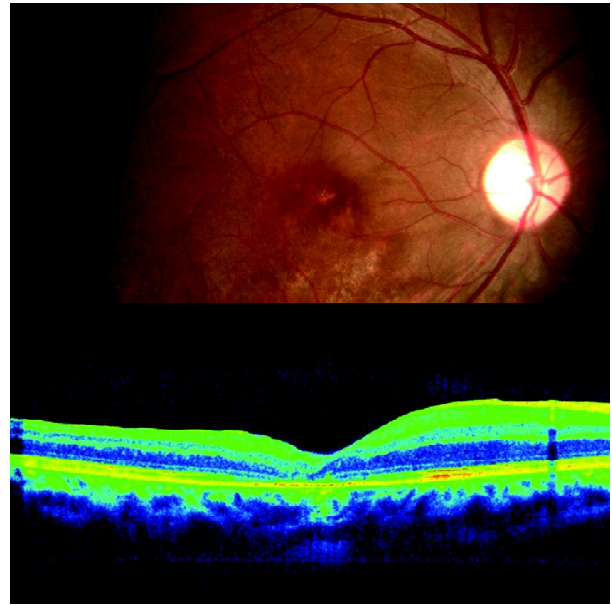
Address for correspondence: Dr Animesh Jindal, M.D, GMRV Campus, Visakhapatnam, L V Prasad Eye Institutes, India  
Tel: +91-89139892020  
E-mail: avinash@lvpei.org



**Figure 1:** Preoperative fundus photograph and OCT show a full thickness macular hole



**Figure 2:** Two weeks postoperative fundus photograph shows a yellow foveal deposit. OCT shows a closed macular hole and subfoveal hyper reflectivity corresponding to the yellow deposit on fundus photograph.



**Figure 3:** Seven weeks postoperative fundus photograph shows disappearance of the yellow deposit and OCT shows absence of the subfoveal hyper reflectivity noticed 5 weeks earlier.

### Discussion

Various studies have reported the toxic effect of triamcinolone on the retina. In an in vitro study, Narayanan et al (2006) concluded that TA could be toxic to proliferating cells of retinal origin. In an experimental study, Kozak et al (2006) found that subretinal TA did not cause any changes in the electroretinographic studies although histopathologically there was damage to the retinal pigment epithelium and outer retina. The same author reported that TA had no toxic effect when injected subretinally in 22 eyes of wet AMD (Kozak et al, 2007).

Hikichi et al (2008) did a comparative study in which they compared the anatomical and functional outcome in patients with and without residual TA. In their study, the macular hole closed in all the cases and there was no significant difference in the final visual outcome between the two groups.



Takeuchi et al (2003) reported that residual TA did not have any harmful effect in their patient on visual recovery and closure of the hole even though the final OCT of their patient did show an outer lamellar hole. Kumar et al (2010) and Yamauchi et al (2006) also showed that residual TA does not hamper macular hole closure and does not affect visual recovery. In contrast, Koto et al (2007) concluded that a macular hole may not close completely and could reopen if TA particles remain inside it. Our case shows that TA may not cause any hindrance in the macular hole closure.

Residual TA may hamper clinical judgement of the status of the macular hole closure because of the white reflex of the TA as observed in our patient. On OCT, TA causes a shadowing of the deeper structures. If it is present on the innermost layers of the retina, it may not be possible to comment on the closure of the macular hole till it disappears or the macular hole closes over it, as in our case.

### Conclusion

Residual triamcinolone acetonide after macular hole surgery may not hamper the anatomical and functional outcome.

### References

Hikichi T, Furukawa Y, Ohtsuka H et al (2008). Improvement of visual acuity one year after vitreous surgery in eyes with residual triamcinolone acetonide at the macular hole. *Am J Ophthalmol*; 145:267–272.

Kimura H, Kuroda S, Nagata M (2004). Triamcinolone acetonide – assisted peeling of the

internal limiting membrane. *Am J Ophthalmol*; 137:308-15.

Koto T, Inoue M, Shinoda K, Ishida S, Tsubota K (2007). Residual crystals of triamcinolone acetonide in macular hole may prevent complete closure. *Acta Ophthalmol Scand*; 85:913-4.

Kozak I, Cheng L, Falkenstein I, Tammewar AM, Freeman WR (2007). Evaluation of subretinal triamcinolone acetonide in patients with exudative age-related macular degeneration. *J Ocul Pharmacol Ther*; 23:46–53.

Kozak I, Cheng L, Mendez T, Davidson MC, Freeman WR (2006). Evaluation of the toxicity of subretinal triamcinolone acetonide in the rabbit. *Retina*; 26:811–817.

Kumar A, Sinha S, Gupta A (2010). Residual triamcinolone acetonide at macular hole after vitreous surgery. *Indian J Ophthalmol*; 58:232-4.

Narayanan R, Mungcal JK, Kenney MC, Seigel GM, Kuppermann BD (2006). Toxicity of triamcinolone acetonide on retinal neurosensory and pigment epithelial cells. *Invest Ophthalmol Vis Sci*; 47:722–728.

Takeuchi M, Katagiri Y, Usui M (2003). Residual triamcinolone acetonide in the macular hole after vitrectomy. *Am J Ophthalmol*; 136:1174 – 1176.

Yamauchi Y, Nakamura H, Hayakawa K and Sawaguchi S (2006). Persistence of triamcinolone acetonide following macular hole surgery. *Acta Ophthalmol Scand*; 84:711–712.

**Source of support: nil. Conflict of interest: none declared**