

Case report

Post LASIK progressive astigmatism in a child with partially accommodative esotropia

Suma G¹, Mathur U², Sethi S³, Arora P¹, Garg J²

¹Pediatric ophthalmology and strabismology services, Dr Shroff's Charity Eye Hospital, Daryaganj, New Delhi

²Cornea and refractive surgery services, Dr Shroff's Charity Eye Hospital, Daryaganj, New Delhi

³Department of Ophthalmology, BPS Government Medical College for Women, Sonapat, Haryana, India

Abstract

Introduction: Refractive surgery is considered a safe and effective method for correction of refractive errors in adults. **Objective:** To report an unusual case of a young child with partially accommodative esotropia presenting with deterioration of vision and worsening of esotropia following refractive surgery. **Case report:** Unanticipated and progressive irregular corneal astigmatism along with deterioration of visual acuity and loss of stereopsis developed post-LASIK in a seven-year-old Indian child with partially accommodative esotropia. **Conclusion:** Keratorefractive surgery in young children has to be undertaken with caution, especially in such cases where there is no medical indication for refractive surgery and waiting beyond teenage years is a viable option.

Key-words: keratorefractive surgery, partially accommodative esotropia, stereopsis, LASIK

Introduction

Esodeviations are the most common type of childhood strabismus. Accommodative esotropia occurs usually in young children and amblyopia is common in this group of patients. The conventional treatment for accommodative esotropia in children includes wearing the cycloplegic hyperopic correction in the form of spectacles or contact lens. In cases of partially accommodative esotropia, strabismus surgery is required for the non-accommodative component of esotropia. With this line of treatment, accommodative esotropes are able to maintain good visual acuity and stereopsis into adulthood, though the outcomes vary depending on individual factors. In certain conditions, refractive surgery is indicated, especially in children with

anisometropic amblyopia who are intolerant to spectacles and contact lenses; the final aim being reduction or elimination of refractive error thus facilitating treatment of amblyopia (Phillips et al, 2004). However, the appropriate age for surgery for accommodative esotropia is still a controversial issue (Luis Amaya, 2005).

We hereby report an unusual case of a seven-year-old child with partially accommodative esotropia presenting with deterioration of vision, and worsening of esotropia following laser-in-situ keratomileusis (LASIK). The purpose is to make the ophthalmologists aware of this rare but serious complication of refractive surgery in a child where treatment with glasses could have given good visual and sensory results.

Case report

A five-year-old girl child of Indian ethnicity presented to the pediatric ophthalmology and

Received on: 22.04.2012 Accepted on: 18.10.2012
Address for correspondence: Dr Ganesh Suma, Dr Shroff's Charity Eye Hospital, Kedarnath Road, Daryaganj, New Delhi -110002, India
Tel: 23251582, 9810688559, Fax: 23251589, E-mail: drsumaganesh@yahoo.com



strabismology services of our centre with complaint of inward deviation of the left eye (OS), as noticed by parents since the age of three years. The family history, treatment history and medical history were unremarkable. On examination, her unaided Snellen's visual acuity (USVA) was 6/9 in the right eye (OD) and 6/36 in the left (OS) and there was 45 prism dioptres (PD) of alternate esotropia both for distance and near with preferable fixation of the right eye (OD). Sensory examination done by Bagoloni's glasses under standard conditions revealed suppression in OS. Retinoscopy was performed under the standard recommended dosage of atropine and accordingly, the child was prescribed hypermetropic glasses of +4.5 sph OD and +3.5 sph OS with which the best corrected Snellen's visual acuity (BCSVA) was 6/9 OD, 6/18 OS. After three months of wearing glasses and part-time occlusion OD, the BCSVA improved to 6/9 OU with a residual esotropia of 20 PD OS both for distance and near; the stereo-acuity at this stage was 400 second of arc as measured by Titmus fly test. The case was diagnosed as a case of partially accommodative esotropia; the child was advised to continue the use of glasses and was planned for squint surgery for the residual esotropia component. The parents were counselled that the child would need to continue glasses after the squint surgery till the end of the first decade after which alternatives in the form of contact lenses or refractive surgery could be considered, if needed.

At the age of seven years, she was brought with decreased vision in both eyes (OU). She had undergone LASIK OU for removal of hypermetropic glasses two months back. Limited information was available from the records which indicated a normal corneal topography pre-operatively and that a LASIK surgery under general

anaesthesia had been undertaken; no other details about the intra-operative parameters or immediate post-operative corneal parameters were available. The patient had been on topical prednisolone drops which had been tapered over the last two months. On examination, her USVA was 6/24 OD and 6/18 OS and there was an esotropia of 35 PD OS with alternate suppression and absent stereopsis. Retinoscopy performed under the standard recommended dosage of atropine revealed +1.00 Sph/-2.00 cyl @170° OD and +1.00 Sph/-0.75 cyl @ 180° OS, with the BCSVA of 6/18 OU and a residual esotropia of 35 PD with glasses. Slit-lamp biomicroscopy showed a region of epithelial ingrowth under the flap contiguous with the flap edge OU, more in OD compared to OS; visual axis was spared in both eyes (Figure 2). The child was managed with appropriate glasses and for the residual esotropia, both eyes medial rectus recession was done. Post operatively, she was well-aligned with glasses, though with the same BCSVA and sensory status as pre-operative. Over a period of two years, ocular alignment was maintained (with glasses) and to our surprise, the epithelial in-growth OU cleared spontaneously without any treatment. However, progressive irregularity in corneal topography was noticed (Table 1, Figure 1); glasses were modified accordingly. Keratometry values at four years follow-up (January 2011) were noted as 42.00 D @170°; 49.25 D @ 80° OD and 40.75 @165°; 46.5@75° OS; KISA% index algorithm criteria on topography detected keratoconus pattern in both eyes, indicating presence of corneal ectasia post-LASIK procedure. The corneal parameter has stabilised thereafter and no further progression has been noticed. The eyes of the child, now 12 years old, are aligned with her astigmatic glasses (Figure 3) on the last follow-up undertaken one month back with BCSVA of 6/12 OD and 6/9 OS.

Table 1: Progressively increasing astigmatism and BCSVA of both the eyes over a follow up of 4 years

Month of examination	Refraction OD (atropine eye ointment)	BCSVA OD	Refraction OS (atropine eye ointment)	BCSVA OS
January 2007	+1.00/-2.00X170	6/18	+1.00/-2.00X170	6/18
July 2007	+1.25/-2.50 x170	6/12	+1.00/-2.00 x180	6/12
January 2008	+1.50/-3.50 X170	6/12	+1.25/-1.50X10	6/12
July 2008	+1.50/-3.50 X170	6/12	+1.25/-1.50X10	6/12
January 2009	+2.00/-7.00X 170	6/12	+1.50/-4.00X170	6/9
January 2010	+2.00/-7.75X 170	6/12	+1.50/-4.00X170	6/9
January 2011	+2.00/-7.50X 170	6/12	+1.50/-3.50X170	6/9

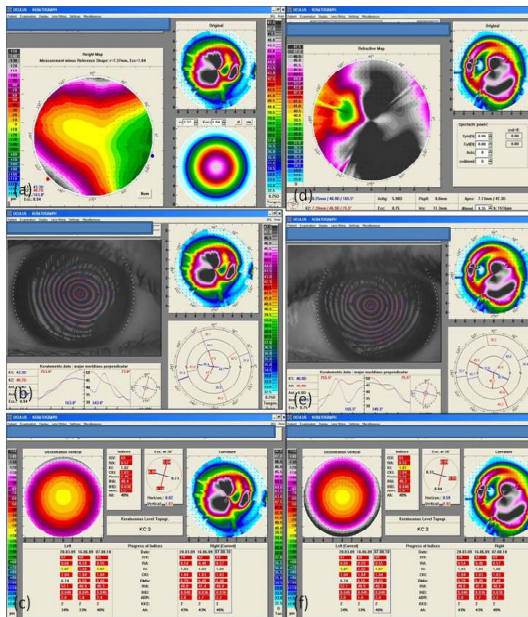


Figure 1: Corneal topography images (Placido's disc based system) of patient's right eye (a) Curvature Map (tangential): central and paracentral Zones showing irregular astigmatism with steepening in the vertical meridian and skewing of radial axis. There is a steep area nasally in the paracentral zone in the horizontal meridian at 3 O' clock; peripheral Zone shows flattening of the corneal curvature, (b) Photokeratoscopic view: Irregularly spaced rings, temporally rings are closely spaced as compared to nasally. There is irregular widening of spaces between the rings in the paracentral zone from 12 O' clock to 2 O' clock (Type of Scale used: Relative Scale), (c) Keratometric view: Central zone: oblique astigmatism (vertical meridian: 47.5D, Horizontal meridian: 44-45 D) with skewing of radial axis; paracentral Zone: oblique astigmatism with skewing of radial axis; peripheral Zone: oblique astigmatism; no skewing of axis. Final Corneal topography images (Placido's disc based system) of patient's left eye (d) Curvature Map (tangential): central and paracentral Zones showing steep cornea with irregular astigmatism. There is a flat area superonasally in the central zone in the oblique

meridian from 9 O' clock to 11 O' clock. Peripheral Zone shows flattening of the corneal curvature; peripheral zone inferiorly has a steep area extending from 4 O' clock to 6 O' clock (e) Photokeratoscopic view: Irregularly spaced rings, temporally rings are closely spaced as compared to superonasally. There is irregular widening of spaces between the rings in the central zone from 7 O' clock to 12 O' clock (Type of Scale used: Relative Scale), (f) Central, peripheral and peripheral zones: irregular astigmatism. Central and paracentral corneal keratometric powers are greater as compared to peripheral zone. Topography findings are suggestive of steep cornea with irregular astigmatism, this along with the clinical findings helped us to confirm the diagnosis as Post Refractive surgery corneal ectasia.

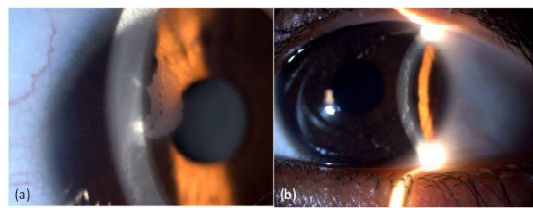


Figure 2: Slitlamp biomicroscopic images of the patient's eyes on presentation after refractive surgery showing (a) Corneal haze with epithelial ingrowth OD and (b) Corneal haze with irregular flap OS.

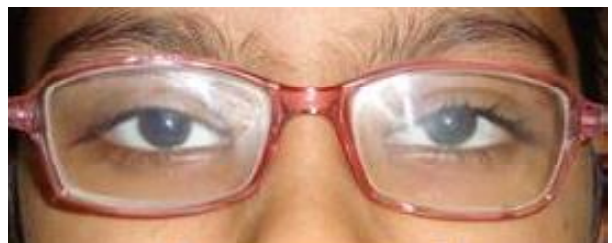

Figure 3: Final clinical photograph of the child at 12 years of age showing aligned eyes with glasses (photograph of the child published with due consent of parents). The corneal parameters at this stage are the same as in figure 1 with no further progression of corneal ectasia.

Discussion

Refractive surgery (photorefractive keratectomy and LASIK), now established for more than 20 years, is considered safe and effective for correction of refractive errors in adults. However, their indications in pediatric population is still a controversial issue (Luis Amaya, 2005). The controversy is not related to the technical aspects of carrying out these procedures in children, but to the appropriate age for intervention and to know whether it is the best way to correct their refractive error so as to benefit them most through their lives (Luis Amaya, 2005). One of the earliest studies on paediatric refractive surgery was undertaken in children with neurobehavioral disorders who could not be compliant with spectacles or contact lenses (Tychsen & Hoekel, 2006). Thereafter, refractive surgery was introduced in children with the aim of treatment of those cases of amblyopia where conventional treatments were ineffective or compliance was poor, such as in high anisometropia. Davidorf et al (2000) classified indications for performing refractive surgery in pediatric and adolescent populations as obligatory, functional and elective and stated that those children who are able to obtain adequate vision with glasses or who are capable of wearing contact lenses have no medical necessity for refractive surgery.

Ours is an unusual case of a seven-year-old child with partially accommodative esotropia, otherwise well managed with glasses, who developed an increase in the non-accommodative component, decrease in BCSVA, loss of stereopsis and gradually progressive irregular astigmatism following LASIK. In a child with partially accommodative esotropia, the resultant high astigmatism, corneal ectasia and increase in non-accommodative component of esotropia is an unacceptable outcome since this interrupts with maintenance of stereopsis which otherwise could have been well attained by treatment in the form of glasses or contact lenses along with squint surgery if needed.

Various studies clearly suggest hyperopic LASIK safe and effective for correction of their refractive

error and esodeviation in late childhood and adults; most of them have however included children beyond 9-10 years of age (Hoyos et al, 2002; Stidham et al, 2002; Kirwan et al, 2010). Stidham et al (2002) studied effect of hyperopic LASIK on ocular alignment in patients with accommodative esotropia (mean age, 33.3 years, range, 10-52 years) and concluded that hyperopic LASIK is effective in reducing mean corrected esotropia in these patients. Philips et al (2004) studied results of performing LASIK in patients with partially accommodative esotropia (range 9 to 18.8 years) and concluded that 47% required enhancement due to under correction of hypermetropia but no patient lost best corrected visual acuity. The role of weaning of hypermetropic glasses has also been studied with promising results (Hutcheson, 2003); Hutcheson et al (2003) in a series of children with accommodative esotropia concluded that 60% of children (with significantly low baseline and final refractive errors) were able to discontinue use of their glasses after a gradual reduction of their hypermetropic correction. Our patient with partially accommodative esotropia having moderate amount of hypermetropia and absence of anisometropic amblyopia was capable of wearing glasses or contact lenses and could first have been given a trial of weaning of glasses. As per the natural history, hypermetropia remains relatively unchanged beyond early childhood, thus making hypermetropia and accommodative strabismus permanent conditions in older children and adults, therefore, refractive surgery at this age to reduce dependence on glasses is justifiable (Stidham et al, 2002).

Non-availability of intra-operative and immediate post-operative corneal parameters is a limitation with our study since the resultant astigmatism could have been well correlated with an intra-operative flap-related complications and resultant epithelial ingrowth. Theoretically, there is less risk of corneal ectasia with surface ablation techniques and of flap related complications in LASIK. An age of less than 18 years and abnormal pre-operative topography,



among others, have been associated with an increased risk of ectasia as per the original ectasia risk scoring system by Randleman et al (2008). In the largest review on pediatric refractive surgery, not many complications were reported in the majority of children, with corneal haze as the most common reported complication (Alió et al, 2011).

Our case initially showed epithelial growth under the flap of both eyes that cleared spontaneously, followed by progressive irregular astigmatism and corneal ectasia. The unpredictable healing response of the cornea in this case challenges the relative safety of LASIK in such small children.

Conclusion

Our case highlights that pediatric refractive surgery should be undertaken with caution in such cases of accommodative esotropia, capable of wearing glasses or contact lenses, where waiting beyond teenage years is a viable option.

References

Alió JL, Wolter NV, Piñero DP, et al (2011). Pediatric refractive surgery and its role in the treatment of amblyopia: meta-analysis of the peer-reviewed literature. *J Refract Surg*; 27(5):364-74.

Davidorf JM (2000). Pediatric refractive surgery. *J Cataract Refract Surg*; 26(11):1567-8.

Hoyos JE, Cigales M, Hoyos-Chacón J, Ferrer J, Maldonado-Bas A (2002). Hyperopic laser in situ keratomileusis for refractive accommodative esotropia. *J Cataract Refract Surg*; 28(9):1522-9.

Hutcheson KA, Ellish NJ, Lambert SR (2003). Weaning children with accommodative esotropia out of spectacles: a pilot study. *Br J Ophthalmol*; 87(1):4-7.

Kirwan C, O'Keefe M, O'Mullane GM, Sheehan C (2010). Refractive surgery in patients with accommodative and non-accommodative strabismus: 1-year prospective follow-up. *Br J Ophthalmol*; 94(7):898-902.

Luis Amaya (2005). Refractive surgery in children. In: David Taylor, Creig S Hoyt, ed. *Pediatric Ophthalmology and Strabismus*, 3rd ed. Elsevier: 57-61.

Phillips CB, Prager TC, McClellan G, Mintz-Hittner HA (2004). Laser-in-situ keratomileusis for high hyperopia in awake, autofixating pediatric and adolescent patients with fully or partially accommodative esotropia. *J Cataract Refract Surg*; 30(10):2124-9.

Randleman JB, Woodward M, Lynn MJ, Stulting RD (2008). Risk assessment for ectasia after corneal refractive surgery. *Ophthalmology*; 115(1):37-50.

Stidham DB, Borissova O, Borissov V, Prager TC (2002). Effect of hyperopic laser-in-situ keratomileusis on ocular alignment and stereopsis in patients with accommodative esotropia. *Ophthalmology*; 109(6):1148-53.

Tychsen L, Hoekel J (2006). Refractive surgery for high bilateral myopia in children with neurobehavioral disorders: 2. Laser-assisted subepithelial keratectomy (LASEK). *J AAPOS*; 10(4):364-70.

Source of support: nil. Conflict of interest: none declared