

## Case report

# Ocular myocysticercosis: Favorable outcomes with early diagnosis and appropriate therapy

Chopra R<sup>1</sup>, Kapoor H<sup>2</sup>, Chopra A<sup>1</sup>

<sup>1</sup>Department of Ophthalmology  
Christian Medical College & Hospital  
Ludhiana, India

<sup>2</sup>SGSH Eye Institute and Multispecialty Hospital, Sohana  
Mohali, India

### Abstract

**Background:** Ocular myocysticercosis is rare and a high index of suspicion is required for its diagnosis. **Objective:** To describe clinical characteristics and treatment outcome of ocular myocysticercosis. **Cases:** We describe a series of three patients who had different clinical presentations of ocular myocysticercosis namely diplopia, restricted ocular motility and sub-conjunctival cyst. The treatment with oral albendazole and prednisolone was effective in all three cases. **Conclusion:** Favorable outcomes can be achieved with a high index of suspicion, early diagnosis and treatment with oral albendazole and prednisolone in patients with ocular myocysticercosis.

**Key-words:** Myocysticercosis, albendazole, steroids

### Introduction

Ocular cysticercosis is a parasitic infection caused by the larvae of cestode *Taenia solium*. It is endemic in developing countries of Latin America, Asia and Africa especially in areas of poverty and poor hygiene (Sekhar & Hanovar 1999). The cysticerci travel via the hematogenous route and lodge themselves in any part of the ocular or orbital tissue. After reviewing all the documented cases of ocular and adnexal cysticercosis, Kruger- Leite et al (1985) found that 35% of cysts were reported in sub-retinal space, 22% in the vitreous, 22% in the sub-conjunctival space, 5% in the anterior segment and only 1% in the orbit.

The clinical manifestations of ocular cysticercosis depend on the location, size, relation to the adjacent structure and the stage of development of the cyst. The most common presenting features are restricted ocular motility, recurrent pain and redness, diplopia, proptosis, subconjunctival cyst, atypical optic neuritis, papilloedema, lid nodules and sub-retinal and intra-vitreous cysts (Pushker et al, 2001).

The spectrum of clinical presentations of ocular myocysticercosis is diverse. We present three cases of ocular myocysticercosis with varied presentations who had a favorable outcome following early diagnosis and appropriate therapy.

**Case 1:** A 32-year old female presented with a history of episodes of pain and redness in the left eye for one week and diplopia in inferior gaze for two days. Ocular examination revealed a visual acuity of 20/20 in both eyes and mild conjunctival

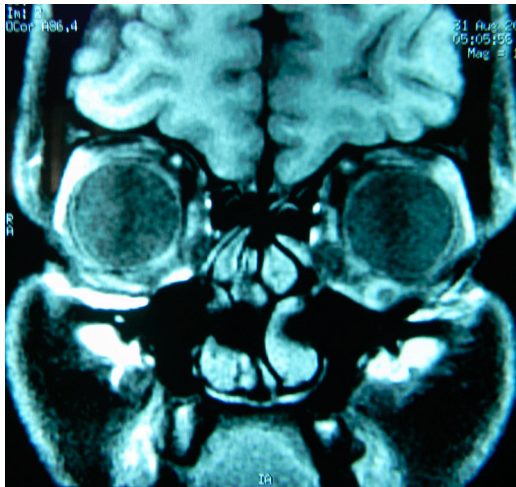
Received on: 28.09.2011 Accepted on: 06.06.2012  
**Address for correspondence :** Dr. Rupali Chopra,  
Associate Professor, Department of Ophthalmology,  
Christian Medical College & Hospital, Ludhiana, India  
Tel : +91 9872899124, Fax : +91 161 2229009  
Email : rupalichopra@gmail.com

congestion in the inferior bulbar conjunctiva of the left eye. Ocular movements were normal in the right eye, whereas in the left there was mild restriction in down gaze. Magnetic resonance imaging (MRI) of the orbit showed a ring enhancing lesion with an eccentric nodule in the inferior rectus muscle (Figure 1). Ultrasonography showed a well defined hypoechoic area in the inferior rectus muscle with a central echodense reflective structure suggestive of the scolex. Diagnosis of cysticercosis was confirmed by enzyme linked immunosorbent assay (ELISA). The patient was given oral albendazole 15mg/kg/day and prednisolone 1mg/kg/day for 4 weeks. Within 15 days of initiating treatment, her symptoms of diplopia, redness and pain decreased and completely regressed after 4 weeks of therapy. There has been no recurrence during the 2-year follow up period.

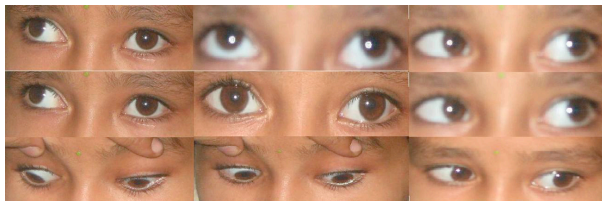
**Case 2:** A nine-year old girl presented with a history of gradual onset squint in the left eye for one month with no associated complaints. The patient had a history of episodes of generalized seizures one year ago for which an MRI of the brain was done elsewhere. She was reported to have a ring lesion in the left parietal lobe and was commenced on oral sodium valproate, after which her seizures did not reoccur. Her visual acuity was 20/20 in both eyes and upon ocular examination she was found to have an exotropia of 50 prism dioptres in the left eye with restricted abduction and adduction in the same eye (Figure 2A). The brain and orbit MRI showed expansion of the left lateral rectus muscle with an area of hyper-intensity within the muscle on T2W images and was suggestive of a cyst which slightly displaced the optic nerve medially. The ultrasonography also showed an enlargement of the left lateral rectus muscle with a hypoechoic area within it and mild displacement of the optic nerve. ELISA for cysticercosis was significantly positive and the patient was started on oral albendazole (15mg/kg/day) and prednisolone (1mg/kg/day). After two days of treatment, the patient returned with complaints of severe pain and swelling in the left eyelid (Figure 2B). Although her visual acuity

was normal, she had severe periorbital edema with conjunctival chemosis and congestion in the left eye. A repeat ultrasound of the left eye showed periorbital edema with no changes from previous examination. Topical tear substitute was added to the regimen of oral therapy and the patient was seen at frequent intervals. Her symptoms of pain, swelling and redness improved after one week and her ocular movements improved after 4 weeks of oral albendazole and prednisolone therapy. After one year, there was a residual exotropia of 15 prism dioptres in the left eye.

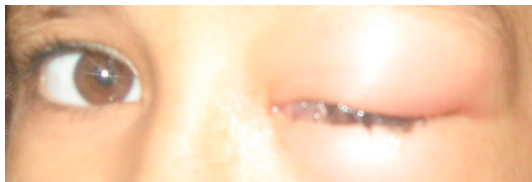
**Case 3:** A 20-year old male presented with history of a painful red nodule in the right eye for two months (Figure 3A) and binocular diplopia for one month. A CT scan of the orbit performed at another facility one month ago showed thickening of the right medial rectus muscle with an area of focal heterogenicity. He was started on oral steroids which caused a mild improvement in the symptoms. However, after discontinuation of steroid treatment, his symptoms recurred and he came to our facility for a second opinion. The visual acuity was 20/20 in both eyes. There was a smooth, hemispherical, sub-conjunctival cystic swelling 1.2cm x 1.2cm on the medial bulbar conjunctiva of the right eye. The overlying conjunctival and episcleral vessels were congested. An ultrasonography was recommended. The patient returned the next day with the spontaneous extrusion of a small balloon like translucent structure from the eye, which was wrapped in a piece of cloth. Upon examination of the eye, the cystic lesion could not be seen and there was a defect visible in the medial conjunctiva, along with localized congestion of vessels. Histopathological examination confirmed the diagnosis of cysticercosis cellulosae (Figure 3B), following which he was started on the regimen of oral albendazole and prednisolone, tear substitute and ciprofloxacin eye drops. His signs and symptoms regressed completely with the above therapy.



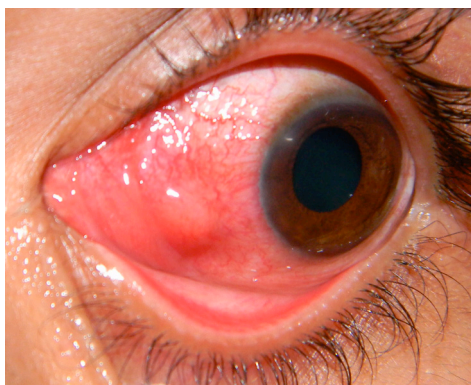
**Figure 1:** MRI of the first patient showing cyst in the inferior rectus muscle of the left eye



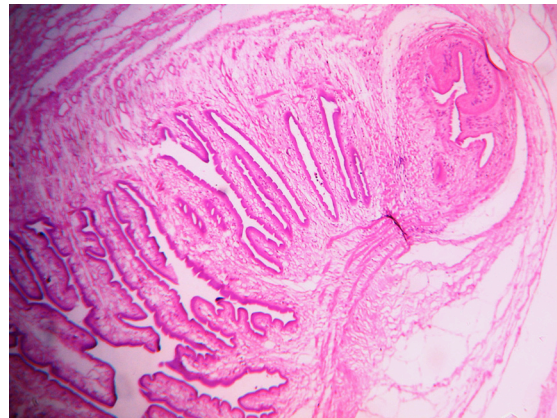
**Figure 2A:** Clinical photograph of the second patient with cyst in the lateral rectus muscle showing restricted ocular movements



**Figure 2B:** Clinical photograph of the same patient following reaction to albendazole



**Figure 3A:** Sub-conjunctival cyst with surrounding inflammation



**Figure 3B:** Histopathology of cysticercosis

### Discussion

While ocular cysticercosis predominantly affects the posterior segment, orbital involvement is not rare. The intraocular cysts are readily diagnosed because of their visibility; however the diagnosis of extraocular myocysticercosis remains speculative. With the advent of better imaging modalities and the availability of ELISA, extraocular myocysticercosis can be diagnosed more easily if clinical suspicion is high.

There are no clear cut guidelines for the management of extraocular myocysticercosis. Surgical removal of the cyst presents a high risk of inadvertent injury to the muscle, resulting in ocular motility disturbances. Surgical intervention is not recommended in myocysticercosis (Mohan K et al, 2005).

Spontaneous extrusion of the cyst, as seen in our third patient, may occur due to inflammation and frequent movement of the muscle involved (Sekhar & Lemke, 1997).

Oral albendazole is a highly effective cysticercidal drug which blocks the glucose uptake of the parasite, thus depleting its glycogen stores. This leads to the death of the larva, release of toxins and severe inflammation. Concurrent use of oral steroids suppresses this inflammation and its sequelae (Sekhar & Lemke, 1997).

Albendazole (15mg/kg/day in two divided doses) combined with oral prednisolone (1mg/kg/day) for



a period of 4 weeks is effective in the treatment of ocular myocysticercosis (Sihota & Honavar 1994). We used a similar regimen for all three patients with favourable outcomes. While complete recovery has been reported in the majority of patients with ocular myocysticercosis, ocular motility restrictions and residual deviations, as seen in our second patient, have also been reported (Sekhar 1997 & Sundaram et al 2004).

Side effects of oral albendazole are rare, though occasional cases of dizziness and gastrointestinal problems have been reported. Optic neuritis has been reported following administration of oral albendazole in a patient with orbital cysticercosis (Tandon et al, 1998). One of our patients developed severe periorbital edema and chemosis on the second day of oral albendazole therapy. A localized inflammatory reaction after initiating this treatment has been previously reported which usually peaks on the third day of the therapy. Therefore, it has been suggested that oral steroids should be started three days prior to therapy with albendazole (Pandey et al, 2000).

Praziquantel has also been used for treatment of ocular myocysticercosis. However, the cyst elimination rate with praziquantel is reported to be only 67% as compared to 80% with albendazole (Soletto J et al, 1998).

### Conclusion

A high index of suspicion, early diagnosis and appropriate therapy result in favorable outcomes in patients with ocular myocysticercosis. Moreover, oral albendazole and prednisolone are effective for the treatment of ocular myocysticercosis.

### Acknowledgement

We acknowledge the help rendered by Dr Sangeetha Mohan and Dr Kanwardeep in providing histological diagnosis. The authors would also like to thank Dr Thomas Mathew for the help.

### References

- Kruger-Leite A, Jalkh AE, Quiroz H, Schepens CL (1985). Intraocular cysticercosis. *Am J Ophthalmol*; 99:252-7.
- Mohan K, Saroha V, Sharma A, Pandav S, Singh U (2005). Extraocular muscle cysticercosis: clinical presentations and outcome of treatment. *J Pediatr Ophthalmol Strabismus*; 42:28-33.
- Pandey PK, Chaudhri Z, Sharma P, Bhomaj S (2000). Extraocular muscle cysticercosis : A clinical masquerade. *J Pediatr Ophthalmol Strabismus*; 37:273-8.
- Pushker N, Bajaj M.S., Chandra M, Neena (2001). Ocular and orbital cysticercosis. *Acta Ophthalmol Scand*; 79:408-13.
- Sekhar GC and Honavar SG (1999). Myocysticercosis: Experience with imaging and therapy. *Ophthalmology*; 106:2336-40.
- Sekhar GC, Lemke BN (1997). Orbital cysticercosis. *Ophthalmol*; 104:1599-1604.
- Sihota R, Honavar SG (1994). Oral albendazole in the management of extraocular muscle cysticercosis. *Br J Ophthalmol*; 78:621-3.
- Soletto J, Escobedo F, Penagos P (1988). Albendazole versus praziquantel for therapy of neurocysticercosis. *Arch Neurol*; 45:532-4.
- Sundaram PM, Jayakumar N, Noronha V. Extraocular muscle cysticercosis – a clinical challenge to ophthalmologists. *Orbit*; 2004;23:255-62.
- Tandon R, Sihota R, Dada T, Verma L (1998). Optic neuritis following albendazole therapy for orbital cysticercosis. *Aus NZ J Ophthalmol*; 26:339-41.

Source of support: nil. Conflict of interest: none