

Case report

Keratoprosthesis, Dohlman Type I device for a patient with repeated corneal graft failure

Bajracharya L¹, Gurung R¹, Tabin G²

¹Tilganga Institute of Ophthalmology, Gaushala, Kathmandu, Nepal

²John A Moran Eye Centre, University of Utah, Salt Lake City, Utah, USA

Abstract

Background: Keratoprosthesis (Kpro) surgery is performed in patients in whom traditional penetrating keratoplasty (PK) surgery has no hope for graft survival. The burden of corneal blindness is high in a developing country like Nepal. **Case:** A thirty-year-old man, with multiple graft failure in his only eye, underwent Kpro surgery. He had ambulatory vision and a stable Kpro 29 months after the surgery. **Conclusion:** Kpro surgery has been introduced in the country with this as the first case. Patients with poor prognosis for PK can benefit from this type of surgery.

Key-words: keratoprosthesis, Dohlman type I keratoprosthesis, Boston keratoprosthesis type I, graft rejection

Introduction: Cornea being avascular and immunologically privileged tissue, PK has very good prognosis compared to any other type of allograft organ transplant in our body. There are, however a group of corneal conditions, in which PK cannot be successful like those with repeated graft rejection, and with severe ocular surface diseases. Kpro or artificial cornea can be implanted in such cases (Bradley et al, 2009; Zerbe et al, 2006). First Kpro surgery was done 150 years back. In the last 50 years, it developed as an alternative for patients with poor or no hope of graft survival (Aquavella et al, 2005). Corneal problem stands as the second commonest cause of blindness, after cataract, in Nepal (Brilliant et al, 1984). Hence, importance of new technology in the country in this field for treating corneal blindness cannot be over emphasized.

Case: A 30-year-old man presented to Tilganga Institute of Ophthalmology in June 2005 with history of blast injury of two months' duration during which both his eyes were injured with loss of vision. His both upper arms were also amputated in the mishap. He had his initial treatment in a general hospital where he received topical antibiotic drops for his eyes and after his general condition had been stable, he was referred to our hospital for ocular management.

On examination, vision in right eye (RE) was perception of light and accurate projection of rays (PR). In his left eye, there was no light perception. His right cornea was edematous, lacerated and irregular with self sealed perforation and superficial vascularization in all quadrants. Details of anterior chamber, pupil, and lens were not visible. Digital intraocular pressure was normal. His left eye was phthisical. B- scan ultrasonography of the RE showed flat retina and clear vitreous cavity. He was put on priority list for penetrating keratoplasty in his RE and underwent the procedure in about a



week.

Intra-operatively, donor and recipient cornea were trephined to a size of 8.50 mm and 8.25mm respectively. The anterior segment of the eye was totally disorganized. Iris tissue was not seen. There was thick fibrous whitish membrane in place of iris and it was adherent to the partially absorbed lens. Posterior capsule was torn. Lens was aspirated and anterior vitrectomy was done. Fundal glow was not healthy. The graft was sutured with interrupted 10-0 nylon sutures.

Post-operatively at one week, vision was hand movement (HM). Graft was clear and anterior chamber was formed. Fundus was visible with normal optic disc, but macula was dull. There was peripheral retinal edema, exudates and hemorrhages were present in the mid periphery and vitreous opacities of grade one suggesting old vitreous hemorrhage. At two months, patient's vision was 1/60 with aphakic correction. At three months post surgery, patient came with pain and redness. His graft was edematous, vision again dropped down to HM. In his graft, he had a line of fresh keratic precipitates inferiorly which was typical of endothelial rejection. He was treated with intensive topical (prednisolone acetate 1%) and systemic steroids (prednisolone tablets 1mg/kg), but eventually graft failed despite timely treatment. He also developed rise in intraocular pressure (IOP) which was controlled with timolol maleate 0.5% twice a day. He had his second graft six months after his first graft. This time also he regained his vision up to 1/60. Unfortunately, graft rejection occurred again after two months of the second surgery. He was treated with anterior subtenon injection of steroids (triamcinolone 40 mg single dose) in addition to intensive topical and oral steroids, but it was of no benefit. Vision dropped to HM again.

The failed graft started to develop superficial and deep vessels, making the prognosis of third graft even worse. However his PR was accurate, retina was flat, his IOP was in control with a single drug, his ocular surface was fair and he can come for regular follow up. These made him a candidate for

Kpro surgery (Ament et al, 2009).

He underwent Kpro surgery on 23rd November 2008. It was the first surgery of this kind in Nepal. Peribulbar block was given. The procedure was performed as described in literature. (Aquavella et al, 2005). Donor button was cut 8.5mm. A 3mm hole is trephined in the centre of the donor. Aphakic type I Dohlman Kpro was fitted in the central 3mm hole in donor cornea and was locked with titanium ring. Patient's cornea, which was the failed edematous graft, was dissected to a diameter of 8.25 mm. No additional anterior segment procedures were performed during the surgery. The donor button with assembled Kpro was sutured to the recipient corneal rim with 10-0 nylon interrupted sutures. A bandage soft contact lens (BCL) was applied.

On first post op day vision was Counting Finger 2 feet. Graft with Kpro was well in place in the recipient rim (Figure 1). Post operative care done with reference to Boston Kpro international protocol (Ament et al, 2009). Patient was put on topical steroids and antibiotic combinations every two hours (ciprofloxacin 0.3% and dexamethasone 0.1%). He was also put on oral steroids at a dose of 1mg per kg for a week and tapered. His previous antiglaucoma medication of timolol maleate was continued. Three weeks post operatively, his vision was 6/18 unaided and 6/12 with pin hole. His digital IOP was on the higher side on digital palpation, so dorzolamide 2% eye drop was added three times a day. Topical antibiotic and steroid combination was tapered to four times a day.

He underwent cleaning of BCL every month and replacement of BCL every 3 months. At 6 months post operation, a faint membrane started to be seen behind the optic of Kpro. His retinoscopy reading was +4.50 at 180 degree and +5.00 at 90 degrees. From subjective refraction, he acquired a vision of 6/18 with +2.50 Diopter Spherical. Patient was happy with the results of surgery. But at 7 months post operative period, patient came with sudden onset blurring of vision which was 1/2/60. His Kpro was clear. Disc was normal but there

was macular edema. Optical coherence topography (OCT) showed subretinal fluid with shallow retinal detachment (RD). Diagnosis of cystoid macular edema (CME) was made. Repeat OCT 4 weeks later showed resolution of subretinal fluid. There was thickening of choroid and no RD. Four months later (1 year post Kpro surgery) vision was 1/60. Kpro was stable. There was 360 degree vascularization and retroprosthetic membrane was denser. At 22 months post Kpro surgery, yag laser membranectomy was done. Media became clearer but there was only little improvement of vision to 2/60 because of the maculopathy. Patient's last follow up was at 29 months during which, Kpro and vision was stable, media was clear (Figure 2). He was on twice a day regimen of steroid – antibiotic combination. IOP was in control with dorzolamide and timolol maleate. The patient was kept on artificial tears every two hours with follow up schedule

Figures

Figure 1 Post operative day one of Kpro surgery

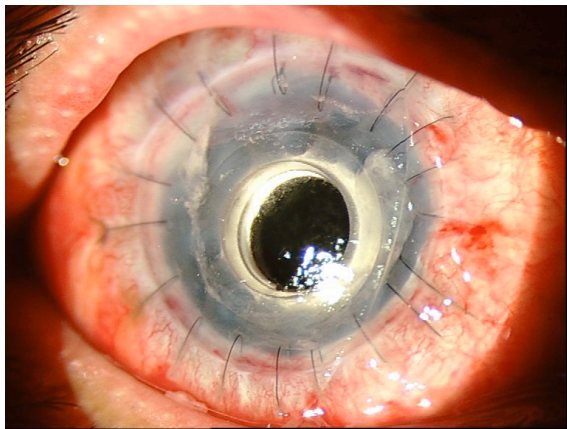
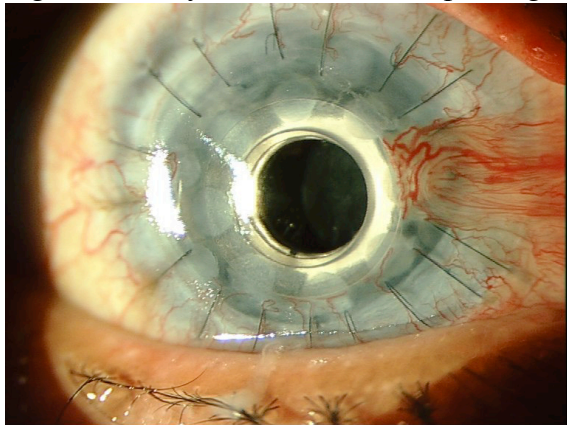


Figure 2: twenty nine months after Kpro surgery



of cleaning BCL 6 weeks later.

Discussion: Kpro surgery is performed to treat corneal blindness, which has poor prognosis for PK like patients with repeated graft failure and with severe ocular surface disease (Bradley et al 2009; Zerbe et al, 2006). There are several Kpro designs that have been developed over time. Dohlman type I (also known as Boston Kpro) is the most commonly used in USA. It is approved by the Food and Drug Administration in US in 1992 (Zerbe et al, 2006).

Several published reports show that eyes with graft failures and chemical injuries have best prognosis for Kpro surgery whereas ocular cicatricial pemphigoid and steven Johnson syndrome (SJS) have worse prognosis (Zerbe et al, 2006; Yaghouti, 2001; Aldave et al, 2009). For SJS and severe ocular surface keratinization, surgery is performed with Dohlman type II or osteo-odonto-keratoprosthesis in which Kpro is placed in the cornea through a closed eyelid (Falcinelli et al, 2005, Sayegh et al, 2008).

The commonest complications of Kpro surgery are retro-prosthetic membrane formation (25-65%) followed by increased intraocular pressure (15-38%), sterile vitritis (0-10%), infectious endophthalmitis (0-11%), choroidal effusion, epiretinal membrane, CME etc (Zerbe et al, 2006; Chew et al, 2009; Bradley et al, 2009; Aldave et al,2009). In most of the cases, the retro prosthetic membrane can easily be treated with yag laser as in this case. The visual prognosis of the Kpro depends on the preoperative status of eye. Often, patients undergoing Kpro have already undergone multiple surgeries and other adverse eye conditions. Pre exiting retinal pathology and glaucoma may make visual outcome poor. Post operatively, 57 to 83% of patients had visual acuity of more than or equal to 20/200.(Zerbe et al, 2006; Chew HF et al, 2009; Bradley et al, 2009; Aldave et al,2009). Visual results also depend on post op complications. The patient in our case was already a poor candidate for vision with respect to impact of blast injury to the eye. Patient had retinal



edema, retinal hemorrhages and unhealthy macula preoperatively. Our patient gained vision of 6/18 (20/60) but he lost it due to CME. Nevertheless, the anatomic success has been achieved with more than two years of follow up and patient could have ambulatory vision in his eye which has no hope for graft survival. The pressure of the eye cannot be determined accurately in an eye with Kpro, Presence of raised IOP is detected by digital tonometry (Aquavella et al, 2005; Klufas et al, 2010). Purpose of wearing BCL over the Kpro is to protect the ocular surface from drying. Desiccation of corneal tissue can result in epithelial defects, tissue melt, necrosis and aqueous leak. These complications have been reduced with continuous use of BCL, which is worn indefinitely (Harissi-Dagher, 2008).

Conclusion

Keratoprosthesis surgery is reserved for visual rehabilitation in cases with poor prognosis for traditional PK. Our yet to publish data of Tilganga Institute of Ophthalmology, a tertiary referral centre for cornea service in Nepal, shows that the commonest indication for PK is infective keratitis, which has poor outcome of graft survival. Kpro surgery is a reasonable option for graft failure patients (Klufas et al, 2010). Now that Kpro surgery has made a beginning in the country, this has set a hope for further development and treatment of patients with repeatedly failed graft as well as desperate cases of corneal blindness.

References

Aldave AJ, Kamal KM, Vo RC, Yu F (2009). The Boston type I keratoprosthesis: Improving Outcomes and Expanding Indications (2009). *Ophthalmology*;116:640–651.

Ament JD, Pineda R, Lawson B, Belau I, Dohlman CH (2009). The Boston keratoprosthesis : International protocol . Version 2 June 15, [http://www.masseyeandear.org/gedownload/KPro%20International%20Protocol2.pdf?item_id=5816015&version_id=5816016](http://1. http://www.masseyeandear.org/gedownload/KPro%20International%20Protocol2.pdf?it em_id=5816015&version_id=5816016).

Aquavella JV, Qian Y, McCormick GJ, Palakuru JR (2005). Keratoprosthesis: The Dohlman-Doane Device (2005). *Am J Ophthalmol*; 140:1032-1038.

Aquavella JV, Qian Y, McCormick GJ, Palakuru JR (2006). Keratoprosthesis Current Techniques. *Cornea*; 25:656-662.

Bradley JC, Hernandez EG, Schwab IR, Mannis MJ (2009). Boston Type I Keratoprosthesis: The University of California Davis Experience. *Cornea*; 28 (3):321-327.

Brilliant LB, Pokharel RP, Grasset NC, Lepkowski JM, Kolstad A, Hawks W, Pararajasegaram R, Brilliant GE, Gilbert S, Shrestha SR, J Kuo (1985). Epidemiology of Blindness in Nepal. *Bull World Health Organ*;63 (2):375-86.

Chew HF, Ayres BD, Hammersmith KM, Rapuano CJ, Laibson PR, Myers JS, Jin YP, Cohen EJ (2009). Boston Keratoprosthesis Outcomes and Complications. *Cornea*; 28(9):989-996.

Falcinelli G, Falsini B, Taloni M, Colliardo P, Falcinelli G (2005). Modified osteo-odonto-keratoprosthesis for treatment of corneal blindness: Long-term Anatomical and Functional Outcomes in 181 cases. *Arch Ophthalmol*; 123:1319-1329.

Harissi-Dagher M, Beyer J, Dohlman CH (2008). The Role of Soft Contact Lenses as an Adjunct to the Boston Keratoprosthesis. *Int Ophthalmol Clin*; 48(2): 43–51.

Khan BF, Mona Harissi-Dagher, Khan DM, Dohlman CH (2007). Advances in Boston Keratoprosthesis: Enhancing Retention and Prevention of Infection and Inflammation. *Int Ophthalmol Clin*; 47(2):61-71.

Klufas MA, Colby KA (2010). The Boston Keratoprosthesis. *Int Ophthalmol Clin*; 50(3): 161–175.

Ma JJ, Graney JM, Dohlman CH (2005). Repeat Penetrating Keratoplasty versus the Boston Keratoprosthesis in Graft Failure. *Int Ophthalmol Clin*; 45(4):49-59



Sayegh RR, Ang LPK, Foster CS, Dohlman CH (2008). The Boston keratoprosthesis in Steven – Johnson Syndrome. *Am J Ophthalmol*; 145:438-444.

Yaghouti F, Nouri M, Abad JC, Power WJ, Doane MG, Dohlman CH (2001).

Keratoprosthesis: Preoperative Prognostic Categories. *Cornea*; 20(1): 19–23.

Zerbe BL, Belin MW, Ciolino JB (2006). Results from the Multicenter Boston Type I Keratoprosthesis Study. *Ophthalmology*; 113: 1779-1784.

Source of support: nil. Conflict of interest: none