

Original article

Pterygium surgery with conjunctival limbal autograft with fibrin glue under topical anaesthesia with lignocaine 2% jelly

Mithal C, Agarwal P, Mithal N
Department of Ophthalmology

Lala Lajpat Rai Memorial Medical College, Meerut, UP, India

Abstract

Objective: To evaluate the efficacy of lignocaine 2% jelly as topical anesthesia in pterygium surgery with conjunctival limbal autograft using fibrin glue.

Materials and methods: A non-randomized interventional study was carried out including twenty-one patients who presented with primary pterygium. Under 2% lignocaine jelly, surgical dissection of the pterygium, scraping of corneal bed with crescent blade, excision of Tenon's capsule, harvesting conjunctival limbal autograft superiorly, and securing it with respect to limbus and stromal orientation with fibrin glue were done. Postoperatively, the patients' discomfort and pain were evaluated by Wong's pain scoring system.

Results: The mean pain score was 0.70 ± 0.97 . Only one patient (4.76%) out of the whole series experienced pain who rated more than three on the visual analog scale of 5. Thirteen patients (61.9%) had pain score of zero, that is, no pain. The surgeon's evaluation of the technique in terms of surgical ease and complications was favorable. There were no dislodged grafts and no cases required suturing. There were no cases of infection, significant inflammation, epithelial problems and reduction in visual acuity. There was a single case of recurrence (4.76%) five months postoperatively which was managed conservatively.

Conclusions: Topical anesthesia with lignocaine 2% jelly using fibrin sealant is safe and effective in pterygium surgery allowing for short operative times. It results in low pain and good aesthetic and functional outcomes.

Key words: fibrin glue, pterygium, topical anaesthesia, conjunctival autograft

Introduction

Tisseel VH (Baxter, Vienna, Austria) is a human fibrin tissue adhesive consisting of a combination of fibrinogen and thrombin which when admixed forms an adhesive fibrin network. Human fibrin tissue adhesive has been used for sutureless lamellar keratoplasty and scleral patch adhesion (Kaufman et al 2003).

Fibrin glue was recently reported as being a successful alternative to conventional suturing in pterygium auto grafting. Various authors have reported the successful use of fibrin glue compared to conventional sutures for pterygium auto grafting (Koranyi et al 2004, Koranyi et al 2005, Uy et al 2005, Marticorena et al 2006). Koranyi et al (2005) reported their findings in a randomized control trial comparing fibrin glue with conventional sutures in 43 cases of pterygium auto grafting, in which surgery time and postoperative discomfort was significantly reduced in those patients receiving

Received on: 28.01.2010 Accepted on: 25.05.2011

Address for correspondence: Dr Prateek Agarwal
469, Prabhat Nagar, Meerut, Uttar Pradesh
Tel: +91-121- 4027865
E-mail: dr.prateekagarwal@gmail.com

fibrin glue (Koranyi et al 2004). No complications were noted.

Our pubmed search revealed only one study in which authors have used ropivacaine 1 % as topical anesthesia for pterygium surgery with fibrin glue (Caccavale et al 2010). We hereby report the successful use of fibrin glue for pterygium surgery with conjunctival autograft under topical lignocaine 2 % jelly. Topical anesthesia with lignocaine 2% jelly using fibrin sealant is safe and effective in pterygium surgery allowing for short operative times and obviates the risk of peribulbar/retrobulbar block. It results in low pain and good aesthetic and functional results.

Materials and methods

The study was conducted in the department of ophthalmology, Lala Lajpat Rai Medical College, Meerut - a tertiary eye care centre in North India. Twenty-one patients were included who presented with primary pterygium from October 2009 to March 2010. This was a non-randomized prospective series of cases undergoing pterygium surgery under topical lignocaine 2 % jelly in which the viability and efficacy of fibrin glue was evaluated. Approval was obtained from the Institutional Review Board of the College and full informed consent was obtained in all our study patients, who were recruited from our general clinics. The inclusion criteria were cosmetically significant pterygium, or clinically significant pterygium presenting with ocular irritation, inflammation, or reduced vision. The exclusion criteria included an age of < 18 years, other concurrent corneal pathology and recurrent pterygium.

All surgeries were performed by a single surgeon (PA) under topical lignocaine 2 % jelly. The lignocaine 2% jelly was instilled in the conjunctival sac five minutes before the surgery. The lids and periocular area were painted with povidone iodine 5 % solution twice and the patient draped. Once fully draped, the eye speculum was inserted. The patients usually reported a stinging sensation, but if instructed and advised to look towards the

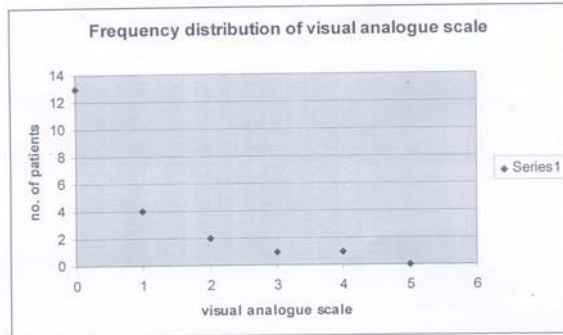
operating microscope light, they brought the eye back to straight gaze. We performed a surgical approach with dissection of the pterygium. Bleeding was controlled using merocel sponge soaked with adrenaline. In a few cases with torrential bleeding, mild bipolar cautery was applied to achieve hemostasis. The patients did not report any pain during cautery. The corneal bed was scraped with a crescent blade for a smooth interface. Meticulous excision of the underlying Tenon's capsule was done. Free autologous conjunctival graft was fashioned superiorly. The graft was positioned to cover the scleral bed exposed in the nasal area with respect to the limbus and stromal orientation with fibrin glue.

Before opening the dressing, a pain survey questionnaire having a visual analog scale for pain evaluation or Wong (2001) scale for a simplified version of pain evaluation was given to the patients. All patients were asked to return for follow-up at 1 day, 1 week, 1 month, 3 months and 6 months postoperatively. Regular slit-lamp anterior segment photography and detailed recording of the status of the grafts were performed in the follow-ups.

Results

There were 21 patients enrolled in the study according to the inclusion and exclusion criteria during the study period from October 2009 to March 2010. The minimum follow-up was 6 months (mean 8.4 months). Fourteen (66.66 %) patients were male. The patients' age ranged from 24 to 65 years (mean age 42.2 years). All the eyes had nasal pterygia. The patients felt mild pain during the excision of tenons capsule (n = 2). The visual analog scale or the Wong scale was used to evaluate the mean pain score.¹¹ The mean pain score was 0.70 ± 0.97 (range 0 - 5). Only one patient (4.76 %) out of the whole series experienced pain which was rated more than three on the visual analog scale of 5. Pain scores of more than three have been accepted to represent moderate pain.^[7] Thus, the rest of the patients can be assumed to have had mild pain. There were 20 patients (95.2 %) who

had a mean pain score of three or less. Thirteen patients (61.9 %) had a pain score of zero, that is, no pain (Figure).



The surgeon's evaluation of the technique in terms of surgical ease and complications was favorable with a good postoperative outcome.

There were no dislodged grafts and no cases required suturing. There were no cases of infection, significant inflammation, epithelial problems, or reduction in visual acuity. There was only a single recurrence (4.76 %) developed five months postoperatively. Since it did not encroach on the cornea, it was conservatively managed. The patients also reported comfortable eyes with typically low visual analogue pain scores (Figure).

Discussion

Pterygium excision with conjunctival grafting has become the gold standard for pterygium surgery, in view of studies demonstrating both safety and efficacy in reducing postoperative recurrence (Sharma *et al* 2003). Previously, the gold standard of securing conjunctival grafts had been the use of sutures. However, disadvantages, which are potential problems, include graft edge scalloping or retraction in-between sutures, suturing time often exceeding the actual pterygium excision and graft dissection, and sutures being prone to inducing hemorrhage. Sutures also add significantly more to postoperative discomfort as compared to fibrin adhesive in conjunctival grafting. Furthermore,

sutures may be associated with granulomas and a greater degree of inflammation, often attract mucous strands, and may require removal if not absorbed rapidly enough.

Our study contributes to the growing evidence that fibrin glue is effective and safe in securing conjunctival autografts for pterygium surgery. Although fibrin glue is bio-degradable and is reabsorbed in 7 - 10 days, ocular surface healing was fast enough and the relatively rapid degradation was not a significant issue in terms of graft stability. We experienced no graft dislocations and there was no significant graft contracture. Topical anesthesia saves the patients from the risks of globe perforations, optic nerve injury, possibility of life-threatening respiratory arrest (Eke *et al* 2007), and above all, the pain and fear perceived because of the peribulbar or retrobulbar injections.

Topical anesthesia has additional benefits like not interfering with visual function, immediate visual recovery, absence of pain due to injection, unlimited ocular motility, and absence of an increase in orbital volume. One drawback of fibrin adhesives remains the risk of transmissible disease, which is minimized by performing human immunodeficiency virus, hepatitis B virus, and hepatitis C virus serology on pooled plasma and screening for viral genomes with polymerase chain reaction. Furthermore, the product undergoes a two-step steam treatment. Thus far there have been no reported cases of transmitted disease in the literature for the use of Tisseel.

This study however has its own limitations. Being a non-comparative study, conclusive evidence of the superiority of topical anesthesia over local anesthesia is not available. The surgeries were done by a single surgeon. This arrangement might have omitted differences induced by variations in the surgical technique and skill. These limitations can be overcome by performing a prospective comparative study involving multiple centers and surgeons.

Conclusions

It is possible to perform pterygium surgery with conjunctival autograft using fibrin glue under topical anesthesia which greatly reduces surgical time. The anesthesia achieved is adequate for patient comfort and safety.

References

Caccavale A, Romanazzi F, Imparato M, et al (2010). Ropivacaine for Topical anesthesia in Pterygium Surgery With Fibrin Glue for Conjunctival Autograft. *Cornea* [Epub ahead of print]

Eke , Tom , Thompson , John R (2007). Serious complications of local anaesthesia for cataract surgery: A 1 year national survey in the United Kingdom. *Br J Ophthalmol*;91(4):470–5.

Kaufman HE, Insler MS, Ibrahim-Elzembely HA, et al (2003). Human fibrin tissue adhesive for sutureless lamellar keratoplasty and scleral patch adhesion: a pilot study. *Ophthalmology*;110 (11):2168-2172

Koranyi G, Seregard S, Kopp ED (2004). Cut and paste: A no suture, small incision approach to pterygium surgery. *Br J Ophthalmol*; 88 (7):911-914.

Koranyi G, Seregard S, Kopp ED (2005). The cut-and-paste method for primary pterygium surgery: long-term follow-up. *Acta Ophthalmol Scand*;83 (3):298-301

Lee J, Stiell I, Hobden E, Wells G (2000). Clinically meaningful values of the visual analog scale of pain severity. *Acad Emerg Med*;7(4):550.

Marticorena J, Rodriguez-Ares MT, Tourino R, et al (2006). Pterygium surgery: Conjunctival autograft using a fibrin adhesive. *Cornea*; 25 (1):34-36.

Sharma A, Gupta A, Ram J, et al (2000). Low-dose intraoperative mitomycin-C versus conjunctival autograft in primary pterygium surgery: long term follow-up. *Ophthalmic Surg Laser*;31 (3):301-307.

Uy HS, Reyes JM, Flores JD, et al (2005) Comparison of fibrin glue and sutures for attaching conjunctival autografts after pterygium excision. *Ophthalmology*;112(4):667-671.

Wong bakers visual analogue FACES pain scale adapted from From Wong DL, Hockenberry-Eaton M, Wilson D, Winkelstein ML, Schwartz P: *Wong's Essentials of Pediatric Nursing*, 6/e, St. Louis, 2001, P. 1301.

Source of support: nil. Conflict of interest: none